

# A practical formula for determining growth

Çağrı Türkoç  
Emine Kaygısız  
Çağrı Ulusoy  
Can Ateş

## PURPOSE

We aimed to establish a practical method to evaluate skeletal age using cervical vertebrae.

## METHODS

The study consisted of hand-wrist and cephalometric radiographs of 324 subjects (167 girls, 157 boys; age range, 7.3–17.2 years). Skeletal ages of the subjects were calculated from hand-wrist radiographs, and cervical vertebral bodies were measured using cephalometric radiographs. A single formula based on C3 and C4 vertebral body heights with different coefficients for each gender was derived using ridge regression analysis.

## RESULTS

The correlation coefficients for vertebral and hand-wrist bone age were 0.825 and 0.856 for girls and boys, respectively. The correlations among vertebral bone age and C3 and C4 vertebral body heights were also found to be significant. The intraclass correlation (ICC) score was found to be 0.914, which shows high consistency between the two measurements of the same investigator for each C3 and C4 vertebral body height result.

## CONCLUSION

The formula derived for evaluating skeletal age in cephalometric radiographs is reliable and can be applied to both girl and boy subjects for legal requirements or therapeutic needs of age estimation.

**T**he ability to determine individual skeletal maturity and percentage of remaining growth is important in optimal timing of correction of skeletal discrepancies in orthodontic treatment planning and age estimation (1–4). Assessment of skeletal age is also helpful in evaluation of growth hormone therapy, diagnosis of endocrine disorders, surgical planning of orthopedic disorders and predicting individual's final height (5). Several biologic indicators have been used to assess individual skeletal maturity, such as chronological age, dental evaluations, secondary sexual characteristics, height increase, hand-wrist radiographs, and maturity of cervical vertebrae (6).

Lateral cephalometric, panoramic, and hand-wrist radiographs, occlusal stone casts, intraoral and extraoral photographs are the standard records that must be evaluated prior to orthodontic treatment planning. Linear and angular calculations are derived from lateral cephalometric radiographs whereas skeletal age is determined from hand-wrist radiographs. The growth potential of the patient is the key determinant for treatment planning as it dramatically changes the treatment procedure. Orthopedic approaches like maxillo-mandibular advancement or retraction depends on the maturity of the bone and pubertal growth spurt as those kinds of treatment need some growth potential.

Hand-wrist radiograph evaluation method, which is popular for skeletal age evaluation, was shown to be highly reliable (2–4, 7–9). The Greulich & Pyle atlas has remained the most authoritative publication for determining skeletal age since 1959 (10). This atlas consists of plates of typical hand-wrist radiographs taken at six to twelve month intervals of chronological age. Twenty hand-wrist bones of the case are compared with the suiting bones in the atlas and an age in months is thereby assigned. In clinical use, this approach is frequently shortened to find the best match of the individual with one of the plates (11). Notable shortcomings of this method include the difficulty in matching the best resembling radiographs in the atlas, exposure to ionizing radiation in addition to that taken from routine orthodon-

From the Department of Orthodontics (Ç.T., E.K., Ç.U. ✉ [culusoy77@yahoo.com](mailto:culusoy77@yahoo.com)) Gazi University School of Dentistry, Ankara, Turkey; Department of Biostatistics (Ç.U., C.A.), Ankara University School of Medicine, Ankara, Turkey.

Received 30 June 2016; revision requested 1 August 2016; last revision received 20 September 2016; accepted 22 October 2016.

Published online 27 March 2017  
DOI 10.5152/dir.2016.16334

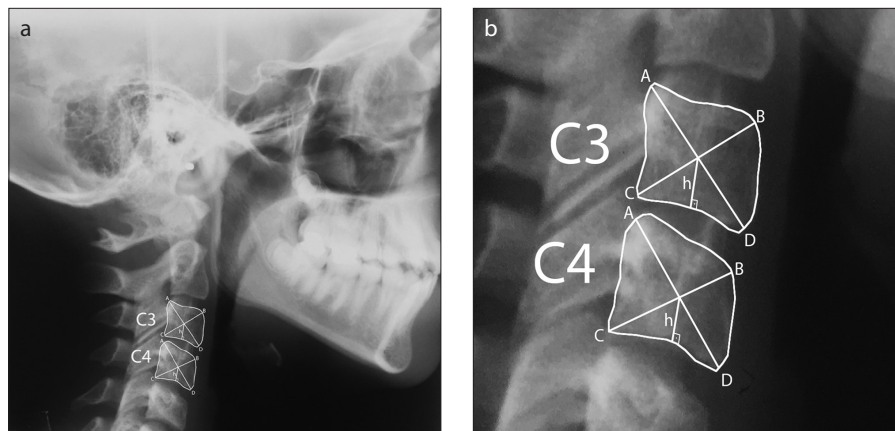
tic radiographs, and possible absence or damage of the hands in forensic cases.

It is known that the body shapes of the cervical vertebrae change with growth. Correlation was found between cervical vertebral maturation and the skeletal maturity of the hand-wrist (12–14). It was reported that cervical vertebral images derived from lateral cephalometric radiographs could be used for determining maturity without the need of hand-wrist radiographs to avoid additional radiation exposure (13, 15). However, this method is limited by the subjective evaluation of growth, because it mainly depends on finding similarity between the radiographs of the subjects and the defined images. Therefore, Mito et al. (16) derived a formula for cervical vertebral bone age in girls, and Caldas et al. (17, 18) developed two formulas in Brazilian subjects to determine reliability. Although these studies have simplified the maturation prediction process, to our knowledge, no previous studies have evaluated a single formula for both genders in Caucasian subjects. The aim of this study was to establish a practical method to evaluate the skeletal age using cervical vertebrae for orthodontic, medical, and forensic purposes.

## Methods

This retrospective study was approved by the local ethics committee. The lateral cephalometric and hand-wrist radiographs obtained for orthodontic treatment of 324 Caucasian patients (167 girls, 157 boys; age range, 7.3–17.2 years) were evaluated. The mean ages for girls and boys were  $11.9 \pm 5.15$  and  $12.1 \pm 3.24$  years, respectively.

Lateral cephalometric radiographs were taken in the natural head position in centric occlusion with a cephalometric radiography system (Trophy Instrumentarium Cephalometer, OP 100). The radiographs used in this study allowed precise visualization of



**Figure 1. a, b.** The points and lines used in the study (a, b). Panel (b) shows magnified view of C3 and C4 vertebrae.

anatomical structures, specifically the third (C3) and fourth (C4) cervical vertebral bodies and hand-wrist bones. One patient who suffered from cervical intervertebral disc calcification in the cervical vertebrae and one patient having endocrine disorder due to cystic fibrosis were excluded from the study.

Contours of the third and fourth cervical vertebral bodies were hand-traced on acetate film placed on a light box in a dark room. For achieving precise and reliable results, the acetate tracing paper (Great Lakes Orthodontics) was traced by 0.3 mm drafting pencil. The distances were measured using a digital caliper with 0.01 mm accuracy (Mitutoyo 500 Absolute Scale Digital Caliper).

The points and lines used in the study are listed below and shown in Fig. 1: Point (a), the most superior points at the posterior border of both vertebrae; Point (b), the most superior points at the anterior border of both vertebrae; Point (c), the most inferior points at the posterior border of both vertebrae; Point (d), the most inferior points at the anterior border of both vertebrae; Line (a–d), the diagonal line between points a and d; Line (b–c), the diagonal line between points b and c; h-line (H), the perpendicular line from the intersection point of the diagonals (a–d) and (b–c) to lower part of cervical vertebral bodies.

The geometrical center of the vertebrae was identified by the intersection of two diagonal lines, which were drawn through the edges of the vertebrae. A perpendicular line through the geometrical center to the base of the vertebral bodies was drawn for both third (C3) and fourth (C4) vertebrae to achieve C3\_H and C4\_H. Greulich & Pyle

Atlas (10) was used to calculate the skeletal age from the hand-wrist radiographs. Each hand-wrist bone was compared with the ones in the atlas in order to find the best match and assign an age in months.

All cephalometric radiographs were traced and measured by the same author (C.U.), and skeletal age was calculated from hand-wrist radiographs by another author (E.K.), each having over 10 years of clinical experience. To test the reproducibility of measurements, the same investigators re-evaluated 50 randomly selected cephalometric and hand-wrist radiographs two weeks after the first evaluation.

## Statistical analysis

The differences between double interpretations were statistically tested. A single formula with two different coefficients for both genders was formed using ridge regression analysis. The variables used in the formula are shown in Table 1.

Due to the multicollinearity problem, ridge regression analysis was preferred instead of multivariate linear regression for statistical evaluations to define a model to predict skeletal age based on C3\_H and C4\_H.

Pearson correlation coefficient ( $r$ ) was used to examine relationships between dependent and independent variables; the intraclass correlation (ICC) one-way random model was used to investigate intra-examiner reliability between two measurements for each independent variable (C3\_H and C4\_H).

Number Cruncher Statistical System (NCSS, 2007-trial version, LLC Inc.) and SPSS v.15 for Windows (SPSS Inc.) were used for statistical analysis and  $P < 0.05$  was considered as significant.

### Main points

- In this study we derived a formula for estimating skeletal age in cephalometric radiographs, which can be applied to male and female subjects for legal requirements and therapeutic needs.
- This formula can be used for age estimation instead of hand-wrist radiographs.
- By omitting the need for hand-wrist radiographs, the patients will be exposed to less radiation for age estimation.

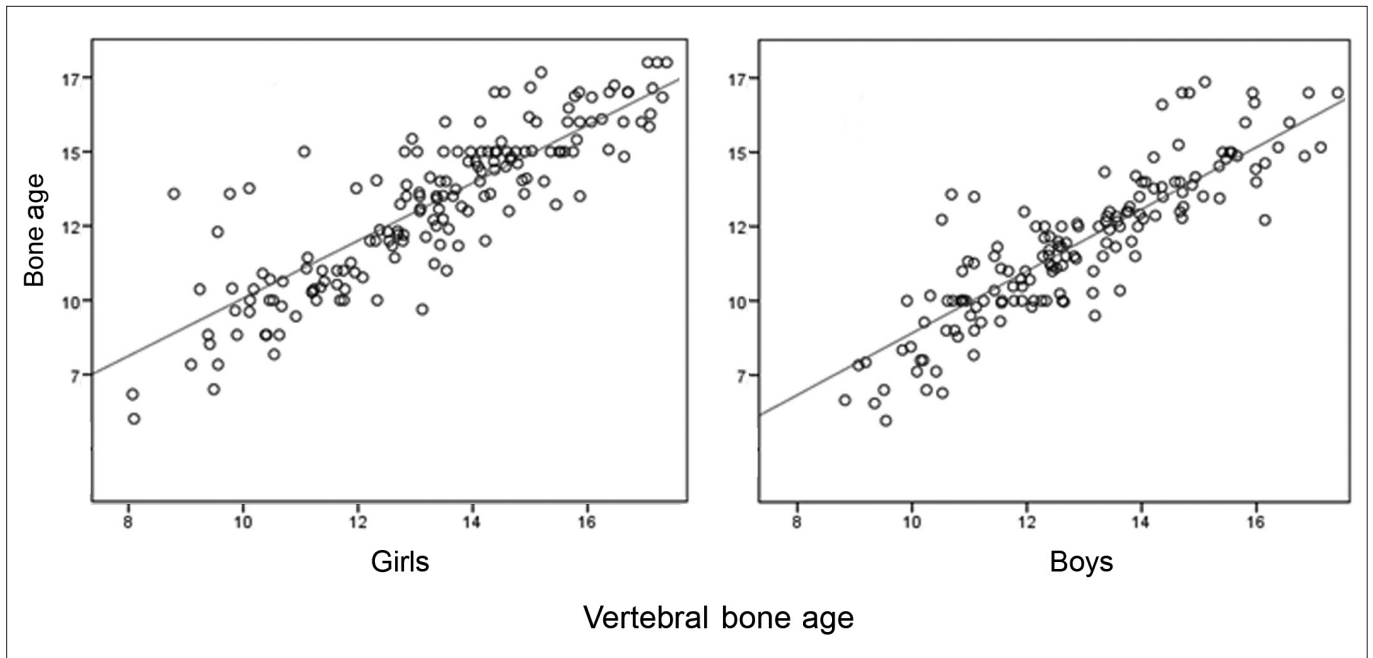

Figure 2. A scattergram of cervical vertebral bone age and bone age.

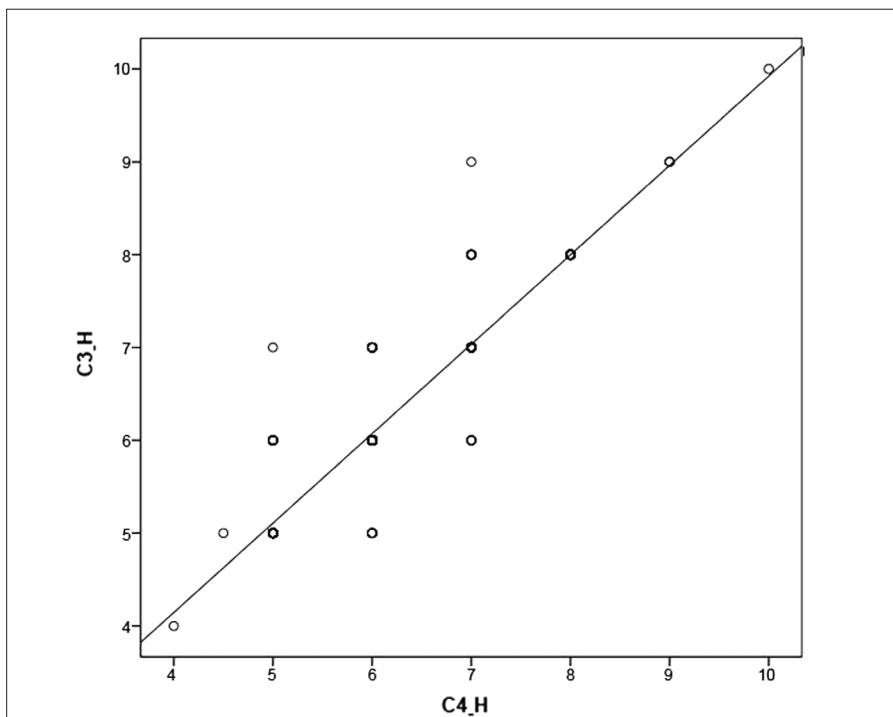


Figure 3. A scattergram of verberal body heights of C3 and C4 (C3\_H and C4\_H).

Table 1. Variables used in the vertebral bone age formula			
Independent variables	Regression coefficients	Standard error	Variance inflation factor
Intercept	0.9817		
Chronologic age	0.7696	0.0464	1.9955
C3_H	0.01028	0.2166	7.1131
C4_H	0.4685	0.2246	7.2094

Ridge regression coefficient section for  $k=0.005000$ .  
 C3\_H, third cervical vertebral height; C4\_H, fourth cervical vertebral height.

## Results

The intra-examiner ICC scores were 0.914 (95% CI, 0.829–0.958) and 0.785 (95% CI, 0.702–0.859) for vertebral heights (C3\_H and C4\_H) ( $P < 0.001$ ) and hand-wrist skeletal age respectively. The correlation coefficients for vertebral bone age and hand-wrist bone age were 0.825 and 0.856 ( $P < 0.001$ ) for girls and boys, respectively (Fig. 2). The ridge regression formulas for determining the cervical vertebral maturation are:

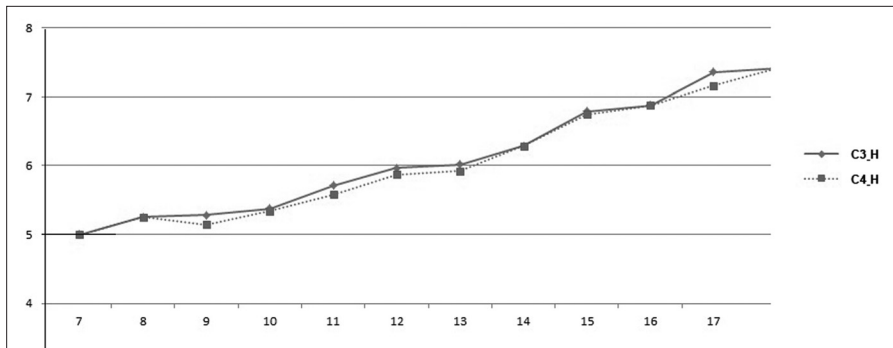
Cervical vertebral bone age for girls =  $0.5052 + 0.7696 \times \text{Chronologic age (years)} + 0.01028 \times C3\_H + 0.4685 \times C4\_H$

Cervical vertebral bone age for boys =  $0.9817 + 0.7696 \times \text{Chronologic age (years)} + 0.01028 \times C3\_H + 0.4685 \times C4\_H$

The correlations among vertebral bone age, C3\_H and C4\_H were significant ( $P < 0.001$ , Table 2). Significant correlations were also found between C3\_H and C4\_H as shown in Fig. 3 ( $P < 0.001$ ,  $r^2=0.935$ ). Both C3\_H and C4\_H were correlated significantly with vertebral age (Fig. 4).

## Discussion

Dentofacial orthopedic treatments on growing subjects have their utmost effect during specific skeletal maturational phases (6). Lateral cephalometric, panoramic, and hand-wrist radiographs are the main records that orthodontists generally use in order to assess facial dimensions, growth velocity,



**Figure 4.** A scattergram of the average vertebral height changes of C3 and C4 (C3\_H and C4\_H) and vertebral ages.

**Table 2.** Correlations among cervical vertebral bone age, bone age, and height of cervical vertebrae C3 and C4

	Correlation coefficients	P
VA and C3_H	0.777	< 0.001
VA and C4_H	0.796	< 0.001
C3_H and C4_H	0.935	< 0.001
VA and BA (girls)	0.825	< 0.001
VA and BA (boys)	0.856	< 0.001

VA, vertebral bone age; BA, bone age; C3\_H, third cervical vertebral height; C4\_H, fourth cervical vertebral height.

and amount of remaining facial growth. As chronologic age is not a valid predictor of skeletal maturation phases, skeletal maturation derived from radiographic analysis is a commonly used prediction method to estimate growth velocity and the proportion of remaining growth (7, 8).

Other reasons for age estimation using bone maturation include evaluation of patients who are being considered for growth hormone replacement therapy and legal matters, such as determination of age in persons without documentation, such as asylum seekers. (2, 4, 19). Moreover, the age limit for criminal liability differs in each country (2). In legal age estimation, performing hand-wrist X-rays for skeletal age prediction and the panoramic radiographs for dental age assessment are recommended (20–22).

Age estimation using cervical vertebrae has been increasingly used to assess skeletal maturation instead of the hand-wrist bone age in recent years (1, 6–8, 12–18). Scoring the developmental stages of twenty bones in the hand and wrist region could be noted as a time-consuming endeavor. San Roman et al. (23) reported that an additional hand-wrist radiograph was the main drawback of the traditional skeletal age prediction method. The American Dental Association Council on Scientific Affairs recommended scientists to follow the “As Low

As Reasonably Achievable” (ALARA) guideline (24). However, a limitation of the cervical vertebral age prediction method was the presence of cervical vertebral anomalies such as fusions, associated with craniofacial syndromes, which are rarely seen (25).

In several studies, cervical vertebral maturation prediction methods used morphologic characteristics of the cervical vertebrae, like the concavity of the lower border, height and shape of the vertebral bodies (13, 15, 16). Although a correlation between the changes in cervical vertebrae and growth was reported (12, 13, 15), the reproducibility of skeletal age evaluation based on similarity between the radiographs and the defined images was found to be disappointingly low (26). Mito et al. (16) and Caldas et al. (17, 18) suggested using methods depending on formulas instead of radiograph similarity for achieving objective results. Therefore, in this study, a formula was developed to easily and objectively calculate the cervical vertebral age.

The third and fourth cervical vertebrae were used in the present study, as the shape changes of these vertebrae with age were enough to show skeletal maturation (27). We used a single formula with different gender coefficients, as gender-dependent differences with regard to the timing of morphologic changes in cervical vertebral

bodies were reported to be significant (17). Moreover, a recent meta-analysis reported that skeletal maturation evaluation performed by cervical vertebrae is positively correlated with carpal calculation methods, showing higher correlation for female gender than for the male (28). The formula in the present study is simpler and more practical than the formulas proposed in previous studies, because it is derived from only three dependent variables.

The intraclass correlation coefficient (ICC), which shows intra-examiner reliability, was found to be 0.914. This high reliability coefficient might be due to the simple nature of the determinants of the formula.

The main ridge regression formula was used to determine cervical vertebral maturity in the present study. Ridge regression technique is used for analyzing multiple regression data that shows multicollinearity, to reduce the standard errors by adding a degree of bias to the regression estimates. Therefore, it is estimated that the net effect will be more reliable. Multicollinearity occurs when near-linear relationships are found among the independent variables. This situation indicates that the least square estimates are unbiased; however, their variances are large, so they may be far from the true value (29).

In this study, the ridge coefficient (k) was selected as k=0.005 according to ridge trace plot, because means and variations were estimated to be more stable at this value. Coefficient selection is an important issue in ridge regression analysis. When “k” is taken as zero, the result is the usual maximum probability estimator and when “k” becomes large the ridge estimators eventually go to zero. For small values of “k”, variable estimates, which are heavily influenced by multicollinearity, tend to change rapidly and as “k” increases, estimates become more stable (30).

Our correlation coefficients for vertebral and hand-wrist bone age estimations were 0.825 and 0.856 for girls and boys, respectively. Therefore, our formula seems to be sufficient to detect skeletal maturation age precisely for both genders. However, Caldas et al. (17) encountered significant differences between vertebral and hand-wrist bone ages for boys, which was in contrast with our findings. That study was performed in Brazil, which has numerous geographic territories with their own distinct characteristics. This might be the reason for different findings between their study and ours.

The main limitation of this study was the small sample size, and further studies

with larger sample sizes are suggested to achieve more reliable prediction methods. The main strength of this study is that with only two morphologic characteristics (C3\_H and C4\_H), a formula that estimates the maturity level has been designed.

In conclusion, the formula derived in this study for evaluating skeletal age in cephalometric radiographs can be used for age estimation instead of hand-wrist radiographs.

#### Conflict of interest disclosure

The authors declared no conflicts of interest.

#### References

- Kucukkeles N, Acar A, Biren S, Arun T. Comparisons between cervical vertebrae and hand-wrist maturation for the assessment of skeletal maturity. *J Clin Pediatr Dent* 1999; 224: 47–52.
- Pinchi V, De Luca F, Ricciardi F, et al. Skeletal age estimation for forensic purposes: A comparison of GP, TW2 and TW3 methods on an Italian sample. *Forensic Sci Int* 2014; 238: 83–90. [\[CrossRef\]](#)
- Darmawan MF, Yusuf SM, Kadir MR, Haron H. Comparison on three classification techniques for sex estimation from the bone length of Asian children below 19 years old: an analysis using different group of ages. *Forensic Sci Int* 2015; 247:130.e1–11. [\[CrossRef\]](#)
- Darmawan MF, Yusuf SM, Abdul Kadir MR, Haron H. Age estimation based on bone length using 12 regression models of left hand X-ray images for Asian children below 19 years old. *Leg Med (Tokyo)* 2015; 17:71–78. [\[CrossRef\]](#)
- Gertych A, Zhang A, Sayre J, Pospiech-Kurkowska S, Huang HK. Bone age assessment of children using a digital hand atlas. *Comput Med Imaging Graph* 2007; 31:322–331. [\[CrossRef\]](#)
- Baccetti T, Franchi L, McNamara JA Jr. The cervical vertebral maturation method for the assessment of optimal treatment timing in dentofacial orthopedics. *Semin Orthod* 2005; 11:119–129. [\[CrossRef\]](#)
- Litsas G, Ari-Demirkaya A. Growth indicators in orthodontic patients. Part 2: comparison of cervical bone age to hand-wrist skeletal age. Relationship with chronological age. *Eur J Paediatr Dent* 2010; 11:176–180.
- Uysal T, Ramoglu SI, Basciftci FA, Sari Z. Chronologic age and skeletal maturation of the cervical vertebrae and hand-wrist: is there a relationship? *Am J Orthod Dentofacial Orthop* 2006; 130:622–628. [\[CrossRef\]](#)
- Sato K, Mito T, Mitani H. An accurate method of predicting mandibular growth potential based on bone maturity. *Am J Orthod Dentofacial Orthop* 2001; 120:286–293. [\[CrossRef\]](#)
- Greulich W, Pyle S. Radiographic atlas of skeletal development of the hand and wrist. Palo Alto, Calif: Stanford University Press; 1959.
- Moore RN. Principles of dentofacial orthopedics. *Semin Orthod* 1997; 3:212–221. [\[CrossRef\]](#)
- O'Reilly M, Yanniello G. Mandibular growth changes and maturation of cervical vertebrae – a longitudinal cephalometric study. *Angle Orthod* 1988; 58:179–184.
- Hassel B, Farman AG. Skeletal maturation evaluation using cervical vertebrae. *Am J Orthod Dentofacial Orthop* 1995; 107:58–66. [\[CrossRef\]](#)
- Danaei SM, Karamifar A, Sardarian A. Measuring agreement between cervical vertebrae and hand-wrist maturation in determining skeletal age: reassessing the theory in patients with short stature. *Am J Orthod Dentofacial Orthop* 2014; 146:294–298. [\[CrossRef\]](#)
- Garcia-Fernandez P, Torre H, Flores L, Rea J. The cervical vertebrae as maturational indicators. *J Clin Orthod* 1998; 32:221–225.
- Mito T, Sato K, Mitani H. Cervical vertebral bone age in girls. *Am J Orthod Dentofacial Orthop* 2002; 122:380–385. [\[CrossRef\]](#)
- Caldas M de P, Ambrosano GM, Haiter Neto F. Computer-assisted analysis of cervical vertebral bone age using cephalometric radiographs in Brazilian subjects. *Braz Oral Res* 2010; 224:120–126. [\[CrossRef\]](#)
- Caldas M de P, Ambrosano GM, Haiter Neto F. New formula to objectively evaluate skeletal maturation using lateral cephalometric radiographs. *Braz Oral Res* 2007; 21:330–335. [\[CrossRef\]](#)
- Moore RN, Moyer BA, DuBois LM. Skeletal maturation and craniofacial growth. *Am J Orthod Dentofacial Orthop* 1990; 98:33–40. [\[CrossRef\]](#)
- Corradi F, Pinchi V, Barsanti I, Manca R, Garatti S. Optimal age classification of young individuals based on dental evidence in civil and criminal proceedings. *Int J Legal Med* 2013; 127:1157–1164. [\[CrossRef\]](#)
- De Donno A, Santoro V, Lubelli S, Marrone M, Lozito P, Introna F. Age assessment using the Greulich and Pyle method on a heterogeneous sample of 300 Italian healthy and pathologic subjects. *Forensic Sci Int* 2013; 229:157.e1–6. [\[CrossRef\]](#)
- Gandini P, Mancini M, Andreani F. A comparison of hand-wrist bone and cervical vertebral analyses in measuring skeletal maturation. *Angle Orthod* 2006; 76:984–989. [\[CrossRef\]](#)
- San Roman P, Palma JC, Oteo MD, Nevado E. Skeletal maturation determined by cervical vertebrae development. *Eur J Orthod* 2002; 24:303–311. [\[CrossRef\]](#)
- Patcas R, Signorelli L, Peltomäki T, Schätzle M. Is the use of cervical vertebra maturation method justified to determine skeletal age? A comparison of radiation dose of to strategies for skeletal age estimation. *Eur J Orthod* 2013; 35:604–609. [\[CrossRef\]](#)
- Sonnesen L. Associations between the cervical vertebral column and craniofacial morphology. *Int J Dent* 2010; 295728. [\[CrossRef\]](#)
- Zhao XG, Lin J, Jiang JH, Wang Q, Ng SH. Validity and reliability of a method for assessment of cervical vertebral maturation. *Angle Orthod* 2012; 82:229–234. [\[CrossRef\]](#)
- Baccetti T, Franchi L, McNamara Jr JA. An improved version of the cervical vertebral maturation (CVM) method for the assessment of mandibular growth. *Angle Orthod* 2002; 72:316–323.
- Cericato GO, Bittencourt MA, Paranhos LR. Validity of the assessment method of skeletal maturation by cervical vertebrae: a systematic review and meta-analysis. *Dentomaxillofac Radiol* 2015; 44:20140270. [\[CrossRef\]](#)
- Hintze J. NCSS, LLC, Kaysville: Utah; 2007.
- Holford TR, Zheng T, Mayne ST, Zahm SH, Tesfari JD, Boyle P. Joint effects of nine polychlorinated biphenyl (PCB) congeners on breast cancer risk. *Int J Epidemiol* 2000; 29:975–982. [\[CrossRef\]](#)