

Coil-assisted retrograde transvenous obliteration for the treatment of duodenal varix

Shin Jae Lee 
Gyeong Sik Jeon 

ABSTRACT

Duodenal variceal bleeding is a rare but potentially life-threatening complication of portal hypertension. Endoscopic therapy is usually the initial treatment option for bleeding duodenal varices, but it is not always feasible or successful. We present a technique of coil-assisted retrograde transvenous obliteration in a patient with duodenal varices originating from the inferior pancreaticoduodenal vein and draining into the right ovarian vein.

Duodenal variceal bleeding is a rare complication of portal hypertension; although it only occurs in 0.4% of cases, it is often catastrophic because of the difficulties in diagnosis and treatment (1). Endoscopic therapy is usually the initial treatment option for bleeding duodenal varices, but it is not always feasible or successful (2). In such circumstances, endovascular treatment could be considered as an alternative option for duodenal variceal bleeding (2). Several studies reported successful results with transjugular intrahepatic portosystemic shunts (TIPS), balloon-occluded retrograde transvenous obliteration (BRTO), and percutaneous transhepatic obliteration (PTO) in treatment of duodenal varices (2–4). To the best of our knowledge, only one case of coil-assisted retrograde transvenous obliteration (CARTO), which is a modified version of BRTO using coils and gelfoam, has been reported for duodenal varix treatment without documentation of collateral pathway (5). Herein we report a case of duodenal varices originating from the inferior pancreaticoduodenal vein and draining into the right ovarian vein that was successfully embolized with coils and gelfoam using double microcatheters.

Technique

A 79-year-old female with a history of right hepatic lobectomy for intrahepatic cholangiocarcinoma presented with hematochezia. An emergency endoscopy showed tortuous blue varices with a cherry red spot in the third portion of the duodenum, suggesting a recent bleeding episode. The varices were not amenable to band ligation or endoscopic injection sclerotherapy due to their location and extent. Contrast-enhanced computed tomography (CT) revealed duodenal varices with markedly dilated veins at the third portion of the duodenum (Fig. 1a). The inferior pancreaticoduodenal vein (one of tributary of superior mesenteric vein) was the feeder of the duodenal varices, and the right ovarian vein was detected as an efferent vein (Fig. 1b).

After obtaining informed consent, we initially planned retrograde venous approach via right ovarian vein to perform BRTO. Procedure was performed in the angiography suite under intravenous sedation and local anesthesia. After obtaining right internal jugular access with micropuncture access set (Cook Medical), 9 F Flexor RTPS guiding sheath (Cook Medical) was advanced to the inferior vena cava. After selection of the right ovarian vein with 5 F Torcon NB (C2) catheter (Cook Medical), we tried to advance occlusion balloon catheter into draining vein deep enough to avoid injecting sclerosing agent into a non-target vessel. However, 5 F catheter and 0.035-inch guidewire (Radiofocus, Terumo) could not be advanced into the distal efferent vein because of severe vascular tortuosity. Therefore, we

From the Department of Radiology (G.S.J. ✉ hae0820@naver.com), CHA Bundang Medical Center, CHA University, Gyeonggi-do, Korea.

Received 29 January 2018; revision requested 13 February 2018; last revision received 27 March 2018; accepted 31 March 2018.

Published online 9 August 2018.

DOI 10.5152/dir.2018.18031

You may cite this article as: Lee SJ, Jeon GS. Coil-assisted retrograde transvenous obliteration for the treatment of duodenal varix. *Diagn Interv Radiol* 2018; DOI 10.5152/dir.2018.18031.

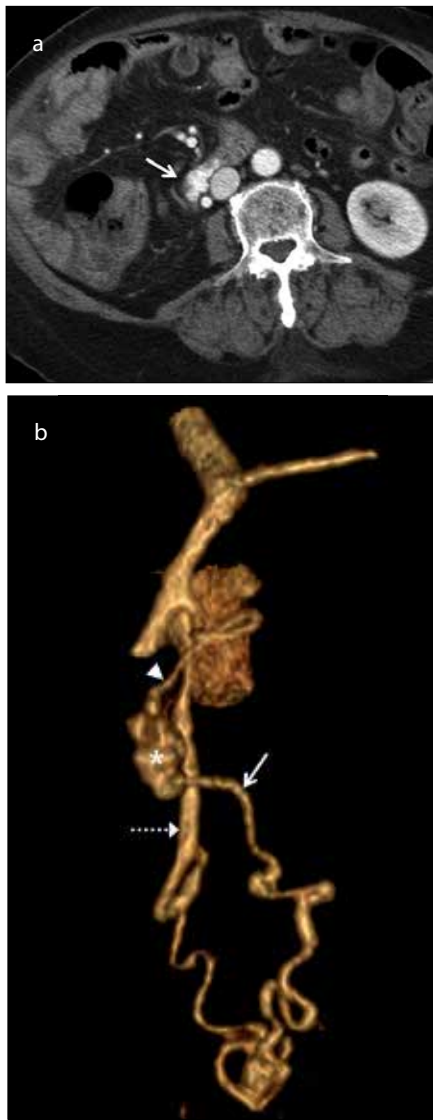


Figure 1. a, b. Axial contrast-enhanced CT scan (a) revealed markedly tortuous dilated veins (arrow) in the third portion of the duodenum. Volume-rendered image (b) demonstrated that the inferior pancreaticoduodenal vein (arrowhead) was the feeder of the duodenal varix (asterisk) and drained into the right ovarian vein (dashed arrow) via a tortuous efferent vein (arrow).

Main points

- Endovascular treatment can be a good alternative of endoscopic treatment for duodenal variceal bleeding.
- It is easier to approach an efferent vein with severe vascular tortuosity in coil-assisted retrograde transvenous obliteration (CARTO) using a double microcatheter system than in balloon-occluded retrograde transvenous obliteration.
- CARTO using only gelfoam has the advantage of avoiding complications related to sclerosant use.

changed our plan to perform CARTO to approach distal efferent vein using microcatheter. We tried to insert microcatheter by the side of 5 F catheter, but microcatheter could not be advanced into the right ovarian vein because of vascular spasm. After removing the 5 F catheter, the efferent vein was accessed using only two microcatheters with a combination of 1.8 F (Artec Portier II, Create Medic) and 1.98 F (Masters Parkway, Asahi Intecc) with either 0.014-inch (Transcend, Boston Scientific) or 0.016-inch (ASAHI Meister, Asahi Intecc) microwires (Fig. 2a). The 1.8 F microcatheter was advanced distally to perform shunt venogram and perform gelfoam embolization. Four 0.018-inch detachable coils (Interlock, Boston Scientific) and two 0.018-inch pushable coils (MicroNester, Cook Medical) were deployed through the proximally placed microcatheter within the efferent vein (Fig. 2b). Then, absorbable gelatin sponge particles (Cali-Gel, Alicon) were injected through the distally placed microcatheter until the entire efferent vein, varices, and afferent vein was visualized (Fig. 2c). After fluoroscopic confirmation of complete stasis, the microcatheters were removed.

The patient was stable without signs of gastrointestinal bleeding after embolization. Patient had no recurrent bleeding during 10 months of follow-up. Follow-up contrast-enhanced CT 3 days after CARTO confirmed complete obliteration of the efferent vein and duodenal varices (Fig 3). There was no major complication, except increased ascites. The duodenal varices were slightly regressed on a 2-week follow-up endoscopy and had completely disappeared at 3 months.

Discussion

The development of duodenal varices is usually associated with a locoregional component (6). These include mesenteric vein stenosis or thrombosis, congenital malformation, intraabdominal adhesion, and/or altered anatomy related to prior surgery (7). Although we did not observe vascular stenosis or thrombosis on contrast-enhanced CT, the patient's prior right lobectomy might have resulted in hemodynamic change from altered splanchnic venous anatomy. Duodenal varices consist of a single dilated "true vein" surrounding the pancreaticoduodenal region with associated afferent and efferent veins that form a retroperitoneal portosystemic shunt (6, 7).

The afferent veins of duodenal varices are commonly superior and inferior pancreaticoduodenal veins, cystic branches of the superior mesenteric veins, gastroduodenal veins, and the pyloric vein (6). Gonadal veins and renal capsular veins are usually the efferent veins of duodenal varices and drain into the inferior vena cava (6).

Because of accessibility issues and the invasiveness of endoscopic therapy, endovascular treatments such as TIPS, BRTO, and PTO have been applied for duodenal variceal bleeding (2). TIPS is accepted as a safe and effective method for both esophageal and gastric varices in the event of bleeding. However, its use for ectopic varices is not well established (2). Although TIPS is less invasive than a surgical shunt, both shunt surgery and TIPS are aimed at relieving portal hypertension, so liver failure and hepatic encephalopathy may develop as a consequence of diminished portal blood flow (8). Moreover, TIPS cannot be applied in patients with unfavorable venous anatomy or in patients with a low hepatic venous pressure gradient. In recent years, BRTO has been reported as a useful endovascular treatment for duodenal variceal bleeding (2, 9). In most reported cases, however, BRTO was performed with sclerotherapy using ethanolamine or cyanoacrylate, which can cause serious complications (2).

CARTO uses a coil for vascular occlusion which avoids some of the complications and difficulties associated with indwelling balloon catheters (5). In this case, it was not feasible to advance the balloon catheter into the efferent vein because of vascular tortuosity. We overcame this difficulty by using a double microcatheter system, advancing to a more proximal portion of the efferent vein as far as possible. Unlike gastric varices with gastrosplenic shunt, selection of the right ovarian vein is more difficult than selection of left renal vein. In addition, duodenal varices with mesenterogonadal shunt have more tortuous and longer collateral pathway to approach the efferent vein. Use of an angled introducer sheath set in the direction of the right ovarian vein orifice can facilitate the selection of right ovarian vein and enhance the catheter support. Moreover, we used gelfoam particles to avoid complications associated with sclerosant use, such as pulmonary embolism, pulmonary edema, portal vein thrombosis, renal failure, and anaphylactic reaction. The patient had no major complications asso-

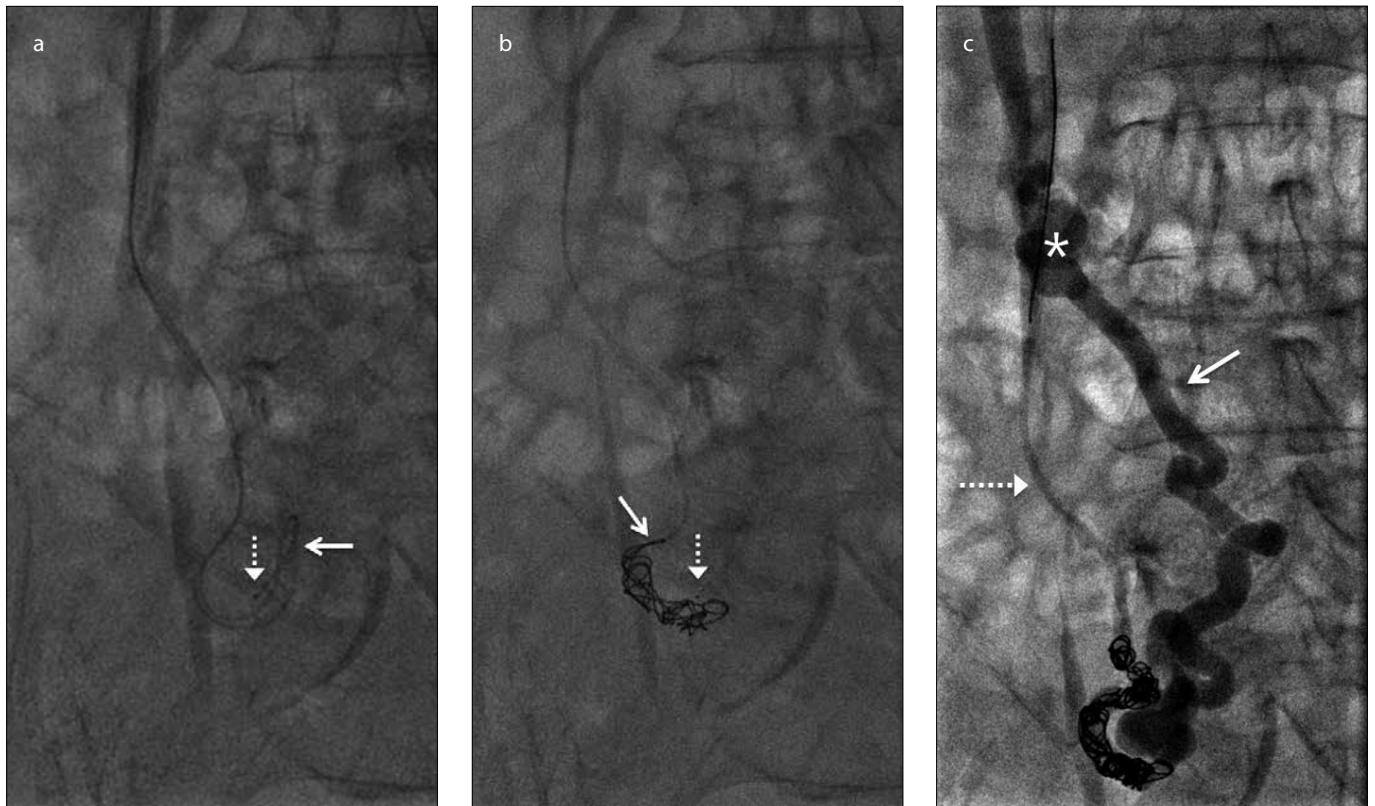


Figure 2. a–c. Fluoroscopic image during coil-assisted retrograde transvenous obliteration (a, b) showed two microcatheters located more distally (dashed arrow) and proximally (arrow) within the efferent vein. Microcoils were deployed through the more proximally placed microcatheter (arrow) within the efferent vein. Final fluoroscopic image (c) showed complete stasis and opacification of the duodenal varix (asterisk) and efferent vein (arrow). Note contrast stasis in the right ovarian vein (dashed arrow) because of sluggish blood flow.

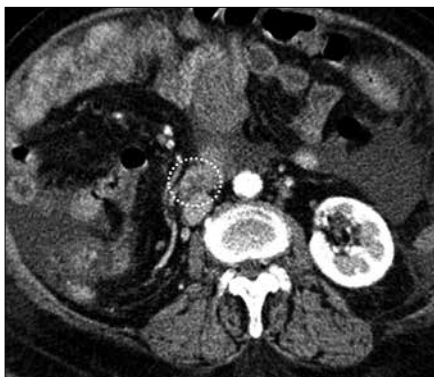


Figure 3. Follow-up axial contrast-enhanced CT scan 3 days after coil-assisted retrograde transvenous obliteration confirmed obliteration of the efferent vein and duodenal varices (dashed circle) in the third portion of the duodenum.

ciated with gelfoam use. Drawback of this technique was that we could not visualize the entire vascular structure before coil embolization because we used a retrograde approach. However, duodenal varices can be successfully embolized as long as microcatheters advance deep enough to avoid

embolization of large collateral veins because small accessory collateral veins are easily embolized with gelfoam.

In conclusion, we report that CARTO is a useful treatment modality for duodenal varices with mesenterogonadal shunt. Advantages of this technique include overcoming vascular tortuosity and avoiding complications related to sclerosant use.

Conflict of interest disclosure

The authors declared no conflicts of interest.

References

1. Hashizume M, Tanoue K, Ohta M, et al. Vascular anatomy of duodenal varices: angiographic and histopathological assessments. *Am J Gastroenterol* 1993; 88:1942–1945.
2. Copelan A, Chehab M, Dixit P, Cappell MS. Safety and efficacy of angiographic occlusion of duodenal varices as an alternative to TIPS: review of 32 cases. *Ann Hepatol* 2015; 14:369–379.
3. Hashimoto R, Sofue K, Takeuchi Y, Shibamoto K, Arai Y. Successful balloon-occluded retrograde transvenous obliteration for bleeding duodenal varices using cyanoacrylate. *World J Gastroenterol* 2013; 19:951–954. [CrossRef]
4. Tanaka O, Ohno K, Ohno T, et al. Should balloon-occluded retrograde transvenous obliteration be the first-line interventional radiologic treatment for bleeding duodenal varices? A case report and review of the literature. *Acta Radiol* 2008; 49:32–36. [CrossRef]
5. Lee EW, Saab S, Gomes AS, et al. Coil-assisted retrograde transvenous obliteration (CARTO) for the treatment of portal hypertensive variceal bleeding: preliminary results. *Clin Transl Gastroenterol* 2014; 5:e61. [CrossRef]
6. Saad WE, Lippert A, Saad NE, Caldwell S. Ectopic varices: anatomical classification, hemodynamic classification, and hemodynamic-based management. *Tech Vasc Interv Radiol* 2013; 16:158–175. [CrossRef]
7. Lopera JE, Arthurs B, Scheuerman C, Sandoz C, Petersosn S, Castaneda-Zuniga W. Bleeding duodenal: varices treatment by TIPS and transcatheter embolization. *Cardiovasc Intervent Radiol* 2008; 31:431–434. [CrossRef]
8. Encarnacion CE, Palmaz JC, Rivera FJ, et al. Transjugular intrahepatic portosystemic shunt placement for variceal bleeding: predictors of mortality. *J Vasc Interv Radiol* 1995; 6:687–694. [CrossRef]
9. Zamora CA, Sugimoto K, Tsurusaki M, et al. Endovascular obliteration of bleeding duodenal varices in patients with liver cirrhosis. *Eur Radiol* 2006; 16:73–79. [CrossRef]