

# Multiparametric MRI in rectal cancer

Bengi Gürses   
Medine Böge   
Emre Altınmakas   
Emre Balık 

## ABSTRACT

MRI has a pivotal role in both pretreatment staging and posttreatment evaluation of rectal cancer. The accuracy of MRI in pretreatment staging is higher compared with posttreatment evaluation. This occurs due to similar signal intensities of tumoral and posttreatment fibrotic, necrotic, and inflamed tissue. This limitation occurs with conventional MRI of the rectum with morphologic sequences. There is a need towards increasing the accuracy of MRI, especially for posttreatment evaluation. The term multiparametric MRI implies addition of functional sequences, namely, diffusion and perfusion to the routine protocol. This review summarizes the technique, potential implications and previously published studies about multiparametric MRI of rectal cancer.

Colorectal cancer is the second most common cancer in females and third most common cancer in males worldwide. Rectal cancer constitutes a significant clinical burden, with almost 40 000 new patients in the USA, in 2015. Rectal cancer constitutes a distinct subset of colorectal carcinoma necessitating a dedicated multidisciplinary approach. In the past decades, treatment approach and diagnostic imaging of rectal cancer have improved considerably (1). Magnetic resonance imaging (MRI) has gained wide acceptance in the pretreatment evaluation of rectal cancer, especially in terms of local staging. The key sequences for T staging are high resolution T2-weighted turbo spin-echo (TSE) images acquired in different planes, planned according to the axis and orientation of the tumor. MRI has overall high sensitivity for local staging of the primary tumor, especially when T staging is considered. MRI has the potential to evaluate and predict circumferential resection margin, extramural invasion and extramural venous invasion with high accuracy. In addition, studies have shown that it is a reproducible technique with high specificity (92%) for predicting a negative circumferential resection margin (CRM), depth of invasion beyond muscularis propria and relationship of the tumor with the CRM (1–3).

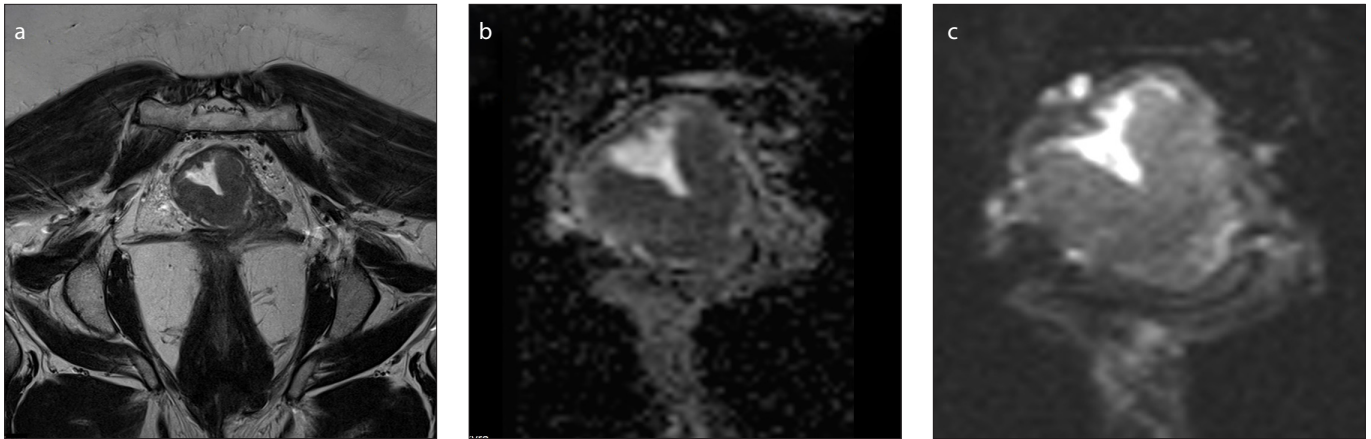
Currently, neoadjuvant treatment consisting of chemo- and radiotherapy (CRT) is applied for rectal carcinomas in locally advanced stage. The role of neoadjuvant treatment has been established, and is well known to reduce local recurrence and increase disease-free survival. Response to neoadjuvant treatment is also assessed by MRI. The sensitivity of MRI in evaluating response is less, when compared with the sensitivity value regarding primary local staging. Hence, for the last few years, there has been great effort to increase the capability of MRI in the evaluation of neoadjuvant treatment response. In addition to this, about 15%–27% of patients exhibit complete response to neoadjuvant therapy (4). It is very critical to identify patients with complete response, since less invasive surgery or no surgery termed as “watch-and-wait” approach are the preferred methods of management. The presence of edema, inflammation, and even fibrosis due to treatment, sometimes hinder the identification of complete response to treatment, since their signal intensities on T2-weighted images resemble that of tumoral tissue. The sensitivity and specificity values are mostly based on classical rectal MRI with conventional sequences based on morphologic evaluation. Due to these limitations, a functional response assessment method with advanced sequences is needed, rather than relying only on morphologic data. Furthermore, there is great interest in predict-

From the Departments of Radiology (B.G. ✉ [bgurses@kuh.ku.edu.tr](mailto:bgurses@kuh.ku.edu.tr), M.B., E.A.) and General Surgery (E.B.), Koç University School of Medicine, Istanbul, Turkey.

Received 3 May 2018; revision requested 6 June 2018; last revision received 8 August 2018; accepted 19 August 2018.

Published online 22 March 2018.

DOI 10.5152/dir.2019.18189



**Figure 1.** a–c. Axial T2-weighted image (a), axial diffusion-weighted image ( $b=800$ ) (b) and ADC map (c) show rectal cancer in the form of circumferential wall thickening.

ing patients who may or may not respond to neoadjuvant treatment at the time of initial diagnosis or early during the treatment period. CRT is not free of side effects such as incontinence and bowel dysfunction, so it is important to predict nonresponders at the time of initial diagnosis (1, 2, 5).

Conventional rectal MRI mainly includes high resolution T2-weighted sequences oriented according to the axis of the tumor in the rectum; additionally, T1- and T2-weighted, pre- and post-contrast images are obtained including the pelvis. The term multiparametric MRI of the rectum refers to addition of diffusion- and perfusion-weighted sequences to conventional rectal MRI. This technique, which is focused on tumor biology, is relatively new, there are only limited number of articles on this topic in the literature, some of which are in the form of feasibility studies (5–11).

#### Main points

- MRI has a pivotal role in both the primary local staging and neoadjuvant treatment response evaluation of rectal carcinoma.
- Accurate and optimal protocol is crucial and increases the sensitivity of local staging at the time of primary evaluation.
- The accuracy of MRI in primary local staging is better than its performance for neoadjuvant treatment response evaluation.
- Multiparametric MRI of the rectal cancer refers to addition of a number of functional techniques (DWI and perfusion) to the routine morphologic sequences.
- Further studies with larger patient groups needs to be performed with standardized techniques to validate the role of this technique on a clinical basis.

Diffusion-weighted imaging (DWI) relies on the thermally driven random motion of water molecules in tissues. In case of increased cellularity and change in cellular membrane integrity, such as in the presence of cancerous tissue, diffusion restriction ensues, which can be clearly shown with DWI sequences, in the form of hyperintensity. The use of DWI technique, although not routine, has an incremental course in both primary and treatment response evaluation for rectal cancer imaging (5–7).

There are several technical parameters as far as DWI acquisition is concerned. The detailed technical parameters is not the scope of this review, but it is noteworthy to mention small field-of-view (FOV) DWI sequence, which is one of the most recent advances in this area. It is well known that conventional DWI sequence has important limitations and artifacts that decrease the resolution. The combination of reduced FOV and single-shot echo-planar imaging (EPI) in the phase encoding direction spatially selective pulses enable decreased acquisition steps and lower EPI echo train (11). This new technique enables to receive high signal from only the area of interest with better resolution without an increase in scan time. There are limited number of studies regarding the feasibility and utility of small FOV DWI technique in the literature. Small FOV DWI studies include the pancreas, testes, kidney, cervix and prostate in the field of abdominal radiology (12–16). As to our knowledge, feasibility or utility study regarding small FOV DWI about rectum and rectal cancer does not exist in the literature. High resolution (HR) T2 TSE and small FOV (Zoom it) DWI images of a patient with rectal cancer performed in our institu-

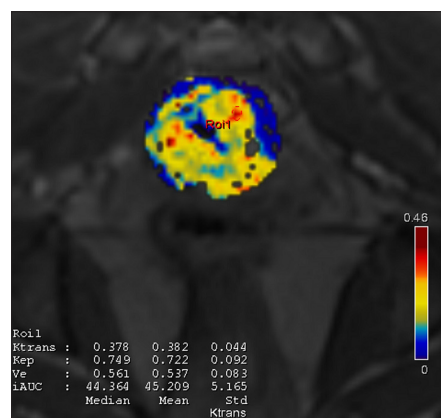
tion is given in Fig.1. Studies with large populations are needed to validate the utility of this new technique. However, we believe that, in future, small FOV DWI with less artifacts and better resolution, will be a routine part of rectal cancer MRI work-up.

Perfusion MRI technique depends on the dynamic assessment of kinetics of contrast uptake. It enables measuring local microcirculation and vascular permeability in a given tissue. Although a number of perfusion parameters can be derived from intravoxel incoherent motion (IVIM) DWI, more accurately perfusion MRI is performed by measuring signal intensity changes over time after administration of a paramagnetic contrast agent. A T1-weighted sequence with high temporal resolution is used for perfusion imaging. Different names exist in different vendors, but the basic sequence used is a high-resolution time-resolved magnetic resonance angiography. The first image obtained before contrast administration is used as a mask for subtraction to improve vascular conspicuity. This sequence enables the center of  $k$ -space to be sampled much more frequently than the periphery, during passage of the contrast. The data from the different partial  $k$ -space samplings are united to obtain a series of time-resolved images with good spatial resolution. After acquisition, the data can be evaluated quantitatively or semiquantitatively with different pharmacokinetic models (e.g., Tofts model, Tofts and Kermod model, Brix model) (2). At the end, a variety of parameters can be derived from perfusion data such as plasma flow (PF), plasma volume (PV), mean transit time (MTT), transfer constant ( $K^{trans}$ ), fractional extracellular leakage space ( $v_e$ ), and rate

constant ( $k_{ep}$ ). In our institution, we use the TWIST (time resolved MRA – echo-shared, high spatial and temporal resolution, time resolved sequences with interleaved stochastic trajectories) sequence with a temporal resolution of 2.9 s and  $K^{trans}$  value is obtained with Tofts model.  $K^{trans}$  is a measure of capillary permeability, which describes the trans-endothelial transport of the contrast medium. It changes according to the plasma flow and vascular permeability (15). Perfusion images of a patient with rectal carcinoma, obtained in our institution, is shown in Fig. 2.

### Paper selection criteria

Initially, a brief review was performed separately for diffusion and perfusion MRI of rectal cancer. In the literature, although there are various studies dealing with the role of DWI or perfusion MRI for rectal cancer with promising results, currently neither of these techniques alone is capable



**Figure 2.** Axial perfusion image of the tumoral segment showing ROI placement and  $K^{trans}$  values.

in terms of sensitivity and specificity to be used routinely in clinical practice with guidance of individualized therapy.

Following the initial review, Pubmed was searched with the keywords “multiparametric rectum MRI”, “diffusion MRI + rectum”, “perfusion MRI and dynamic contrast enhanced MRI + rectum”. The publications with multiparametric MRI of the rectum and ones containing both diffusion and perfusion techniques have been reviewed. Previous studies focusing on a single functional MRI technique have not been included in this part of the review process.

Small FOV diffusion is a new diffusion MRI technique that enables smaller FOV images within similar acquisition times. As far as we could review the literature, none of the previous studies has utilized this technique for multiparametric rectal MRI.

IVIM theory is well known to suggest that DWI signal intensity is not only pure diffusion signal, rather it is a combination of free water diffusion and perfusion of the blood capillary network depending on the  $b$  value. Thus, perfusion data can be extracted from IVIM with a biexponential DWI model. Articles with this technique were also included in the review.

We identified a total of 14 published studies (Tables 1 and 2) dealing with multiparametric MRI of the rectum (including both diffusion and perfusion data); of these, 4 included feasibility and reproducibility (Table 1), 3 were in the form of review, and 2 were technical reports.

### Literature review

Diffusion-weighted MRI has been shown to help detection, characterization, staging, and evaluation of neoadjuvant treatment

response for rectal cancer (17). As far as detection is concerned, the addition of DWI to conventional T2-weighted imaging has been proven to provide better results (17, 18). In a series of 45 rectal cancer patients the sensitivity of detection of the primary lesion increased from 82%–84% to 93%–96% with the addition of DWI technique in addition to T2-weighted imaging (19). As far as characterization is concerned, the apparent diffusion coefficient (ADC) value of adenocarcinomas have been found to be significantly lower compared with the normal rectal wall (19, 20). For mucinous type adenocarcinomas with more aggressive behavior, the ADC values have been reported to be higher compared with classical tubular type adenocarcinomas (21). As to our knowledge there is no study comparing the diffusion characteristics of adenocarcinomas and other tumors such as gastrointestinal stromal and carcinoid tumor (17).

Local staging of the tumor still relies on conventional T2-weighted sequences where DWI has shown no significant advantage for characterization, except for lymph node detection (22). The sensitivity and specificity of conventional MRI sequences is well known to be limited in the detection of response to neoadjuvant treatment. At this point, addition of DWI technique appears to be promising. DWI has been reported to perform better than conventional imaging in terms of detecting residual viable tumor after neoadjuvant treatment (17). In 2013 Ha et al. (23) measured tumor volumes of 100 rectal cancer patients on T2-weighted imaging (T2 volumetry) and DWI (DWI volumetry) before and after neoadjuvant treatment for evaluation of complete remission. Interestingly, post chemoradiotherapy

**Table 1.** Feasibility studies regarding multiparametric MRI of rectal adenocarcinoma

First author, date	No. of patients with rectal adenocarcinoma	Sequences for diffusion and perfusion	Diffusion parameters	Perfusion parameters	Volumetric analysis	Inter-reader correlation for tumoral tissue
Attenberger, 2014	54	ssEPI, TWIST	ADC	PF, MTT	-	“Good” for all parameters
Hötker, 2016	24	ssEPI, not indicated	ADC, DWI volumetry	$K^{trans}$ , DCE volumetry	+	Inter-reader measurements differ significantly
Attenberger, 2017	21	ssEPI, TWIST	ADC	PF, MTT	-	“Good” for ADC and PF
Sun, 2018	52	IVIM with single-shot DWI	ADC, D	f, D*	+	“Excellent” for ADC, D, D* and f

ssEPI, single shot echo-planar imaging; TWIST, time-resolved angiography with interleaved stochastic trajectories; ADC, apparent diffusion coefficient; PF, plasma flow; MTT, mean transit time; DWI, diffusion weighted imaging;  $K^{trans}$ , transfer constant; DCE, dynamic contrast-enhanced imaging; IVIM, intravoxel incoherent motion; D, diffusion coefficient; D\*, pseudodiffusion coefficient; f, perfusion fraction.

**Table 2.** Summary of methodology and results of all reviewed articles about multiparametric MRI of the rectal cancer

First author, year	MRI Tesla strength	Pt No	DWI sequence and b values	DWI parameters	Result of DWI analysis	Perfusion sequence	Perfusion parameters	Results of perfusion analysis	Conclusion
Attenberger, 2014	3 T	54	Routine, b: 50, 400, 800, 1000	ADC		TWIST, temp. resolution: 4.9 s	PF, MTT, PV		
Attenberger, 2017	3 T	21	Routine, b: 50, 400, 800, 1000	ADC	Higher ADC initially is correlated with better treatment response	TWIST, temp. resolution: 4.9 s	PF, MTT	No significant correlation	A high initial ADC might predict better response to CRT
Sun, 2017	3 T	52	IVIM, b: 0, 25, 50, 75, 150, 400, 800, 1000	ADC, D	Tumor grade positively correlated with ADC, tumor stage negatively correlated with D	IVIM	D*, f	Tumor grade positively correlated with D*, f Tumor stage negatively correlated with D*, patients with EMVI have decreased D*	IVIM parameters might have the potential to predict aggressiveness of the tumor
Xu, 2018	3 T	51	IVIM, b: 0, 25, 50, 75, 150, 400, 800, 1000	ADC, D	Negative correlation between KRAS positivity and ADC and D	IVIM	D*, f	Positive correlation between KRAS positivity and D*	IVIM parameters might have the potential to predict KRAS status and therefore therapy resistance
Petrillo, 2017	1.5 T	35	Routine + IVIM b: 0, 50, 100, 150, 300, 600, 800	ADC, f, Dt	$\Delta ADC, \Delta f, \Delta Dt, \Delta D^*$ has statistically significant difference among responders versus non-responders.	Flash 3D, temp. resolution: 0.58 min	$\Delta MSD, \Delta WOS, D^*$	Significant difference in SIS among responders and nonresponders (best diagnostic performance)	SIS derived from perfusion MRI has the potential to assess treatment response as an angiogenic biomarker
Hötker, 2016	1.5 T and 3 T	24	Routine, b: 0, 750, 1000	ADC, DWI volumetry	DWI volumetry has significant correlation with tumor regression grade	Not indicated	$K^{trans}$ , DCE volumetry	DCE volumetry has significant correlation with tumor regression grade	Only DWI and DCE volumetry were detected to have significant correlation with tumor regression
De Cecco, 2016	3 T	12	Routine, b: 0, 200, 800	ADC	No significant correlation with complete response	3D FSPGR	$K^{trans}, k_{ep}, v_e$ , IAUGC90	$v_e$ significantly lower in patients with complete pathologic response	Texture analysis with kurtosis and $v_e$ derived from perfusion may have the potential to act as biomarkers for treatment response
Nie, 2016	3 T	48	Routine, b: 0–800	ADC		SGR (LAVA)	MSD, WIS, WOS		With a systematic analysis of multiparametric MRI features, it is possible to build models with better predictive value over conventional imaging

MRI, magnetic resonance imaging; Pt, patient; DWI, diffusion-weighted imaging; ADC, apparent diffusion coefficient; TWIST, time-resolved angiography with interleaved stochastic trajectories; PF, plasma flow; MTT, mean transit time; PV, plasma volume; CRT, chemoradiotherapy; IVIM, intravoxel incoherent motion; D, diffusion coefficient; D\*, pseudodiffusion coefficient; f, perfusion fraction; EMVI, extramural venous invasion; KRAS, Kirsten rat sarcoma viral oncogene homologue; Dt, tissue diffusion; SIS, standardized index of shape; MSD, maximum signal difference; WOS, washout slope;  $K^{trans}$ , transfer constant; FSPGR, fast spoiled gradient echo;  $k_{ep}$ , rate constant between extravascular/extracellular space and blood plasma;  $v_e$ , volume of extravascular/extracellular space per unit volume of tissue; IAUGC90, areas under the concentration curve of gadolinium contrast agent over 90 s; WIS, wash in slope.

(CRT) ADC showed a significant difference between complete and noncomplete responders. The accuracy of DWI tumor volumetry was found to be significantly superior compared with T2 volumetry in determining complete response (23). Another series of 40 patients with rectal cancer used different methodology to confirm that the addition of DWI yielded better diagnostic accuracy than conventional imaging in terms of complete response evaluation (24). The mean ADC of the group with complete responders was detected to be significantly higher than that of the noncomplete responders' group.

As far as grade of the primary tumor is considered, low ADC values were reported to be detected in more aggressive tumors. This is concluded by the fact that histologically less well differentiated tumors (according to grades) were found to have significantly lower ADC values. In addition to this, lower rectal tumors invading the mesorectal fascia were found to have significantly lower pretreatment ADC values (17).

There are conflicting results about the prediction of tumor response to treatment based on DWI technique. A group of authors reported no significant difference between ADC values of responders and non-responders (25, 26). Whereas some authors reported that initial ADC values may predict favorable or bad response to neoadjuvant treatment, about one or two weeks after initiation of therapy (27, 28).

There are limited number of published studies regarding perfusion MRI of rectal cancer. Most of them have been focused on the role of perfusion MRI in the evaluation of neoadjuvant treatment response and detection of complete responders. Martens et al. (29) performed perfusion MRI at the time of initial diagnosis and 7–10 weeks later in a total of 30 patients with rectal carcinoma. The perfusion parameters they analyzed were initial slope, initial peak, late slope, and area under the curve (AUC). They found no significant difference except pretreatment late slope, which was detected to discriminate between good and poor responders. They concluded that the perfusion parameter "late slope" could potentially be used before the onset of therapy to predict who will respond to therapy (29). This is an interesting finding showing that perfusion MRI may have the potential to discriminate between responders and non-responders, which may cause avoidance of

a therapy causing side-effects or change in treatment strategy. On the other hand, Kim et al. (30) performed perfusion MRI in a total of 50 patients with rectal carcinoma to determine the role of this technique in the evaluation of treatment response after completion of neoadjuvant therapy. The perfusion parameters used were different from the previous study, and included  $K^{trans}$ ,  $k_{ep}$ , and  $v_e$ . Interestingly, they detected significant decrease in mean  $K^{trans}$  values in patients with a good response to therapy (30). This finding is very important since it shows that perfusion parameters may one day have the potential to detect complete responders, which is sometimes very hard to determine with conventional sequences. Another recent study about perfusion MRI of the rectum including 46 patients with rectal carcinoma investigated whether perfusion parameters were correlated with aggressiveness of rectal cancer. They detected significant correlation between some of the perfusion parameters and microvessel density and T stage of tumor and concluded that a number of perfusion parameters might be used to predict aggressiveness of the tumor and hence prognosis (31).

The first published study using the term "multiparametric MRI of rectal cancer" is by Attenberger et al. (5) in 2014. This study included both feasibility and repeatability of the parameters derived from multiparametric MRI. A total of 54 patients with biopsy-proven rectal adenocarcinoma were included retrospectively. The parameters evaluated were ADC derived from DWI and PF and MTT derived from perfusion data. For acquisition of perfusion sequence they used TWIST with a temporal resolution of 4.9 s. They performed measurements of both the tumor and the intramesorectal lymph nodes. Two different readers analyzed the data. The regions-of-interest (ROIs) in both diffusion and perfusion analyses were drawn at the discretion of each reader to fit the tumor size. They did not perform volumetric analysis. The inter-reader correlations for ADC, PF, and MTT for lymph nodes ranged from good to very good, whereas the correlations of the same values for primary tumor were reported to be good (5). This study is the first to show that diffusion and perfusion parameters derived from multiparametric rectal MRI can be performed with acceptable interobserver agreement, although they did not

perform a volumetric analysis. In addition to interobserver agreement, Attenberger et al. (5) performed the first research study on multiparametric MRI of the rectum. ADC maps were calculated automatically by the software, and the parameters measured for perfusion were PF, MTT and PV. PF and MTT were significantly different between cT2 and cT3 tumors, whereas no significant correlation existed between the clinical stage and ADC values. They suggested that some of the MRI perfusion parameters might have the potential to allow prediction of tumor grade (5). This is the first study that shows functional MRI parameters may help to discriminate between T and N stages, which we believe is a very important end point, since the accuracy of conventional MRI is limited in this area.

Hötter et al. (32), investigated the role of multiparametric MRI for neoadjuvant treatment response and performed inter-reader analysis. In a total of 24 patients with rectal adenocarcinoma, two different readers evaluated the results independently. In contrast with the findings of other publications, inter-reader agreement differed significantly in their study. The agreement on pretreatment values was determined to be better when compared with the post-treatment values. The best agreement was found to be for ADC (32). A major limitation of their study is the limited number of patients. In their study they have also investigated the role of multiparametric MRI in the assessment of response of rectal cancer to neoadjuvant treatment. All patients had undergone DWI and dynamic contrast enhanced (DCE) imaging sequences in addition to routine protocol. They performed volumetric analysis using T2, DWI and DCE sequences using a special software. We believe that volumetric analysis is the superior aspect of their study. They observed that the only parameters that have significant association with histopathologic tumor regression grades for all readers were DWI volumetry and DCE volumetry. Neither the morphologic nor the other functional (ADC,  $K^{trans}$ ) parameters were found to be associated with tumor regression. The results of this study provide a new concept to multiparametric MRI, namely volumetry, which might have the potential to perform better than two-dimensional functional parameter measurements (32).

In 2017, Attenberger et al. (33) published another article regarding the role of multi-

parametric MRI in rectal cancer as an evaluation tool of therapeutic response to neoadjuvant CRT in a group of 21 patients. They acquired DWI and perfusion using TWIST sequence. Two readers, blinded to the clinical data of the patients, performed the image analysis separately and inter-reader correlation was assessed. The parameters derived from DCE and DWI MRI were PF, MTT and ADC, respectively. They did not perform a volumetric analysis, rather they drew ROIs of approximately 1 cm<sup>2</sup> on the tumoral tissue. Inter-reader correlation was good for ADC and PF, but not good for MTT (33). Although once again a number of MRI parameters were shown to have good interobserver agreement, the major limitations of this study are limited number of patients and the lack of volumetric analysis. They have also evaluated the role of 3 T multiparametric MRI, namely ADC, PF, and MTT, in prediction of therapeutic response to neoadjuvant CRT in patients with advanced-stage rectal cancer. They observed that overall ADC values exhibited a significant increase after neoadjuvant CRT when compared with the parameters obtained at initial imaging. The PF values were found to be decreased but this was not significant. Between tumor regression grades 1 and 2 the only significant difference was detected among ADC values. The ADC value was significantly higher in patients with better response to CRT. They concluded that a high initial ADC value might have the potential to predict response to CRT. On the other hand they have not observed statistically significant correlation, as far as perfusion parameters are concerned (33).

A recent work about diffusion and perfusion MRI using IVIM was published in 2018, by Sun et al. (34). In their study, perfusion data were obtained from IVIM DWI performed with a 3 T MRI equipment. They did not perform contrast-enhanced perfusion technique, which we believe is the major limitation of this study. A total of 52 patients with rectal carcinoma were included. The parameters were ADC, pure diffusion coefficient (D), perfusion fraction (f), and pseudodiffusion coefficient (D\*). In the feasibility section of their study, they inserted ROIs to all sections containing tumoral tissue, excluding necrotic areas. ROIs were inserted manually on all consecutive tumor slices, differently from the previously mentioned feasibility studies. They reported excellent interobserver agreement between the two observers for ADC, D, D\*, and f parameters (34).

Multiparametric MRI of the rectum is a complex technique, where standardization is crucial in each step, including acquisition and data analysis. For the DWI technique, all the parameters including b value, ROI size, the level of tumor on which ROI will be inserted, needs to be standardized. Perfusion is a much more complicated technique compared with diffusion, as far as standardization is concerned. A number of perfusion parameters can be derived from IVIM DWI, or more accurately it can be performed using intravenous contrast material. The sequence used for perfusion, temporal resolution of the technique, as well as data analysis need to be standardized. There are different models that can be used during perfusion data analysis which further complicates the technique. In most of the previous work, different acquisition and analysis parameters have been used, and the number of studies including feasibility, inter and intra-observer variability is quite a few. Sun et al. (34) inserted ROIs on all consecutive slices including the tumor for measurement of IVIM parameters, in a volumetric fashion. Their level of interobserver agreement was excellent, whereas Attenberger et al. (33) did not perform such a volumetric analysis and their interobserver agreement was inferior. Thus, we believe that volumetric analysis with dedicated software instead of single-slice or slice-by-slice analysis and ROI replacements that include the tumor as much as possible instead of smaller ROIs, may provide more accurate and standardized data. However, more feasibility studies including interobserver correlation with standardized techniques need to be performed to validate the repeatability of this technique, prior to sensitivity and specificity analyses.

Among the nine studies on multiparametric MRI of rectal cancer, ADC was the main parameter that has been focused for DWI analysis, whereas for perfusion analysis, a large spectrum of parameters have been used. According to the sequence obtained and post-processing technique, D\* and f (obtained from IVIM),  $K^{trans}$ , PF, PV and MTT, maximum signal difference, wash-out-slope, wash-in-slope have been implicated by different authors (5, 8–11, 32–34).

A total of three articles used the IVIM technique to investigate about multiparametric MRI of the rectum (10, 11, 29). As mentioned above, in the feasibility section Sun et al. (34) performed multiparametric MRI in a total of 52 patients with rectal can-

cer using IVIM technique. They compared different IVIM parameters with a variety of tumor prognostic markers. With better differentiation of the tumor (low grade), they detected higher ADC, D\* and f values. This finding is very important which may have the potential in the future to discriminate between potential responders and nonresponders to neoadjuvant treatment. With increased tumor stage, significant decrease was observed as far as D and D\* are concerned. This proves that a number of IVIM DWI parameters have the potential to predict tumor aggressiveness and stage. Interestingly, the patient group with extramural venous invasion (EMVI) showed lower D\* when compared with the group without EMVI. Their results indicate that multiparametric MRI data may have the potential to predict aggressiveness of the tumor, and hence, prognosis (34).

The second article using IVIM technique is focused on different parameters (11). They studied the possible correlation of IVIM data with KRAS (Kirsten rat sarcoma viral oncogene homologue) status in patients with rectal cancer. KRAS is an oncogene that is mutated in approximately 35%–40% of patients with colorectal cancer. Clinically, it is crucial to be aware of any mutations in this gene, since patients with KRAS mutations are resistant to a specific type of therapy (anti-EGFR monoclonal antibody targeted therapy). In their study, IVIM parameters were measured in a total of 51 patients with rectal carcinoma and compared between patients with and without KRAS mutation. Interestingly, they found positive correlation between KRAS positivity and D\* value, and negative correlation between KRAS positivity and ADC and D values. They concluded that rectal cancers with different KRAS mutation status exhibited distinctive diffusion and perfusion parameters (11). This is a very interesting finding that may help in the future for prediction of therapy resistance, but their results need to be validated by a higher number of patients.

Another study about multiparametric MRI of rectal cancer included texture analysis, which is a measure of intratumoral heterogeneity, in addition to DWI and perfusion. They studied the possible role of these techniques in prediction of neoadjuvant treatment response in a total of 12 patients. The parameters obtained from functional sequences were kurtosis from T2-weighted images, ADC from DWI, and  $K^{trans}$ ,  $k_{ep}$ ,  $v_e$  and IAUGC90 (area under the

curve) from perfusion. They observed that pretreatment kurtosis was significantly lower in the group with complete pathologic response. Among the other parameters,  $v_e$  was the only one with significant negative correlation in complete response patients. They concluded that kurtosis derived from texture analysis and  $v_e$  might have the potential to act as a marker of neoadjuvant treatment response in rectal cancer (8). Their results are promising for the future of multiparametric MRI, although the number of patients is low, which is a major limitation of this study.

With the purpose of evaluation of multiparametric MRI in the prediction of pathologic response of rectal cancer to neoadjuvant treatment, Nie et al. (9) published a research study in 2016. They included a total of 48 patients with rectal cancer. DWI and DCE were performed on each patient in addition to the routine protocol. ADC maps were created from DWI, while perfusion imaging was used to calculate maximum signal difference, wash-in-slope and wash-out-slope parameters using a special software for each voxel. They analyzed the role of these parameters to predict "good" and "complete" response to treatment and concluded that through a systematic analysis of multiparametric MRI features, they were able to build models with improved predictive value, compared with conventional imaging metrics (9). A summary of all the above-mentioned studies about multiparametric MRI is given in Table 2.

There are also several studies in the literature focusing of diffusion kurtosis imaging (DKI) of rectal adenocarcinoma. Different from classical diffusion, diffusion kurtosis, namely non-Gaussian diffusion takes into account multiple factors related to tissues such as the cell membrane, proportion, and change in the formation of the extracellular matrix. DKI provides a number of diffusivity parameters. Zhu et al. (35) performed DKI in a total of 56 patients with rectal adenocarcinoma, in order to correlate DKI parameters (kurtosis and diffusivity) with prognostic factors of the rectal tumor. Kurtosis was detected to be significantly higher in high grade when compared with low grade tumors and diffusivity was significantly inversely related with the tumor grade. Interestingly, compared with ADC, kurtosis performed better in terms of correlation with tumor grades (35). Similarly, another study about DKI consisting of 76 patients

with rectal adenocarcinoma has shown that kurtosis also positively correlated with tumor grade. Among all parameters (kurtosis, diffusivity, and ADC) kurtosis showed the best correlation with prognostic factors (36). Yet, new studies with larger patient groups are needed to validate the role of this technique.

## Conclusion

Multiparametric MRI is a new technique that is largely in the research phase. The studies published in this area are limited in number. The sequences, the MRI parameters that are used in statistical analysis, and hence the results of the previous studies are extremely heterogeneous. This impedes comparison of studies and establishment of standardized protocols. Studies present conflicting results regarding the role of the MRI parameters in the prediction of neoadjuvant treatment response. Currently, there is no established cutoff value for any parameter to predict complete response. Moreover, the number of patients included in previous studies is limited. Multicenter studies with large patient populations, using standardized techniques in consensus are needed to validate the role of this new technique for the imaging of rectal cancer. Nevertheless, multiparametric MRI seems to emerge as a promising tool; we believe that in the future this technique will be employed in a standard fashion and will act as an imaging biomarker to predict potential responders and nonresponders prior to neoadjuvant treatment, determine responders in early phases of treatment, and predict "good" and "complete" responders.

## Conflict of interest disclosure

The authors declared no conflicts of interest.

## References

- Costa-Silva L, Brown G. Magnetic resonance imaging of rectal cancer. *Magn Reson Imaging Clin N Am* 2013; 21:385–408. [\[CrossRef\]](#)
- Hötker AM, Garcia-Aguilar J, Gollub MJ. Multiparametric MRI of rectal cancer in the assessment of response to therapy: a systematic review. *Dis Colon Rectum* 2014; 57:790–799. [\[CrossRef\]](#)
- Sun Y, Li J, Shen L, et al. Predictive value of MRI-detected extramural vascular invasion in stage T3 rectal cancer patients before neoadjuvant chemoradiation. *Diagn Interv Radiol* 2017; 23:251–256.
- Maas M, Nelemans PJ, Valentini V, et al. Long-term outcome in patients with a pathological complete response after chemoradiation for rectal cancer: a pooled analysis of individual patient data. *Lancet Oncol* 2010; 11:835–844. [\[CrossRef\]](#)

- Attenberger UI, Pilz LR, Morelli JN, et al. Multi-parametric MRI of rectal cancer - do quantitative functional MR measurements correlate with radiologic and pathologic tumor stages? *Eur J Radiol* 2014; 83:1036–1043. [\[CrossRef\]](#)
- Morani AC, Elsayes KM, Liu PS, et al. Abdominal applications of diffusion-weighted magnetic resonance imaging: Where do we stand. *World J Radiol* 2013; 5:68–80. [\[CrossRef\]](#)
- Pham TT, Liney G, Wong K, et al. Study protocol: multi-parametric magnetic resonance imaging for therapeutic response prediction in rectal cancer. *BMC Cancer* 2017; 17:465. [\[CrossRef\]](#)
- De Cecco CN, Ciolina M, Caruso D, et al. Performance of diffusion-weighted imaging, perfusion imaging, and texture analysis in predicting tumoral response to neoadjuvant chemoradiotherapy in rectal cancer patients studied with 3T MR: initial experience. *Abdom Radiol (NY)* 2016; 41:1728–1735. [\[CrossRef\]](#)
- Nie K, Shi L, Chen Q, et al. Rectal cancer: assessment of neoadjuvant chemoradiation outcome based on radiomics of multiparametric MRI. *Clin Cancer Res* 2016; 22:5256–5264. [\[CrossRef\]](#)
- Petrillo A, Fusco R, Granata V, et al. MR imaging perfusion and diffusion analysis to assess pre-operative Short Course Radiotherapy response in locally advanced rectal cancer: Standardized Index of Shape by DCE-MRI and intravoxel incoherent motion-derived parameters by DW-MRI. *Med Oncol* 2017; 34:198. [\[CrossRef\]](#)
- Xu Y, Xu Q, Sun H, et al. Could IVIM and ADC help in predicting the KRAS status in patients with rectal cancer? *Eur Radiol* 2018; 28:3059–3065. [\[CrossRef\]](#)
- Riffel P, Michaely HJ, Morelli JN, et al. Zoomed EPI-DWI of the pancreas using two-dimensional spatially-selective radiofrequency excitation pulses. *Plos One* 2014; 9:e89468. [\[CrossRef\]](#)
- Downey K, Jafar M, Attygalle AD, et al. Influencing surgical management in patients with carcinoma of the cervix using a T2- and ZOOM-diffusion-weighted endovaginal MRI technique. *Br J Cancer* 2013; 109:615–622. [\[CrossRef\]](#)
- He YL, Hausmann D, Morelli JN, et al. Real zoomed EPI-DWI with spatially-selective radiofrequency excitation pulses in two dimensions. *Eur J Radiol* 2016; 85:1773–1777. [\[CrossRef\]](#)
- Yıldırım İO, Sağlık S, Çelik H. Conventional and ZOOMit DWI for evaluation of testis in patients with ipsilateral varicocele. *AJR Am J Roentgenol* 2017; 208:1045–1050. [\[CrossRef\]](#)
- Luna A, Pahwa S, Bonini C, et al. Multiparametric MR Imaging in Abdominal Malignancies. *Magn Reson Imaging Clin N Am* 2016; 24:157–186. [\[CrossRef\]](#)
- Nguyen TLF, Soyer P, Fornes P, et al. Diffusion-weighted MR imaging of the rectum: Clinical applications. *Crit Rev Oncol Hematol* 2014; 92:279–295. [\[CrossRef\]](#)
- Soyer P, Lagadec M, Sirol M, et al. Free-breathing diffusion-weighted single-shot echo-planar MR imaging using parallel imaging (GRAPPA 2) and high b value for the detection of primary rectal adenocarcinoma. *Cancer Imaging* 2010; 10:32–39. [\[CrossRef\]](#)
- Rao SX, Zeng MS, Chen CZ, et al. The value of diffusion-weighted imaging in combination with T2-weighted imaging for rectal cancer detection. *Eur J Radiol* 2008; 65:299–303. [\[CrossRef\]](#)

20. Curvo-Semedo L, Lambregts DM, Maas M, et al. Diffusion-weighted MRI in rectal cancer: apparent diffusion coefficient as a potential noninvasive marker of tumor aggressiveness. *J Magn Reson Imaging* 2012; 35:1365–1371. [\[CrossRef\]](#)
21. Nasu K, Kroki Y, Minami M. Diffusion-weighted imaging findings of mucinous carcinoma arising in the ano-rectal region: comparison of apparent diffusion coefficient with that of tubular adenocarcinoma. *Jpn J Radiol* 2012; 30:120–127. [\[CrossRef\]](#)
22. Mizukami Y, Ueda S, Mizumoto A, et al. Diffusion-weighted magnetic resonance imaging for detecting lymph node metastases of rectal cancer. *World J Surg* 2011; 35:895–899. [\[CrossRef\]](#)
23. Ha Hong, Kim AY, Yu CS, et al. Locally advanced rectal cancer: diffusion-weighted MR tumor volumetry and the apparent diffusion coefficient for evaluating complete remission after preoperative chemoradiation therapy. *Eur Radiol* 2013; 23:3345–3353. [\[CrossRef\]](#)
24. Cho SH, Kim GC, Jang YJ, et al. Locally advanced rectal cancer: post-chemoradiotherapy ADC histogram analysis for predicting a complete response. *Acta Radiol* 2015; 56:1042–1100. [\[CrossRef\]](#)
25. Kim SH, Lee JY, Lee JM, et al. Apparent diffusion coefficient for evaluating tumor response to neoadjuvant chemoradiation therapy for locally advanced rectal cancer. *Eur Radiol* 2011; 21:987–995. [\[CrossRef\]](#)
26. Curvo-Semedo L, Lambregts DM, Maas M, et al. Rectal cancer: assessment of complete response to preoperative combined radiation therapy with chemotherapy-conventional MR volumetry versus diffusion-weighted MR imaging. *Radiology* 2011; 260:734–743. [\[CrossRef\]](#)
27. Jung SH, Heo SH, Kim JW, et al. Predicting response to neoadjuvant chemoradiation therapy in locally advanced rectal cancer: diffusion-weighted 3 Tesla MR imaging. *J Magn Reson Imaging* 2012; 35:110–116. [\[CrossRef\]](#)
28. Lambrecht M, Vandecaveye V, De Kayzer F, et al. Value of diffusion-weighted magnetic resonance imaging for prediction and early assessment of response to neoadjuvant radiochemotherapy in rectal cancer: preliminary results. *Inr J Radiat Oncol Biol Phys* 2012; 82:863–870. [\[CrossRef\]](#)
29. Martens MH, Subhani S, Heijnen LA, et al. Can perfusion MRI predict response to preoperative treatment in rectal cancer? *Radiother Oncol* 2015; 114:218–223. [\[CrossRef\]](#)
30. Kim SH, Lee JM, Gupta SN, Han JK, Choi BI. Dynamic contrast-enhanced MRI to evaluate the therapeutic response to neoadjuvant chemoradiation therapy in locally advanced rectal cancer. *J Magn Reson Imaging* 2014; 40:730–737. [\[CrossRef\]](#)
31. Yeo DM, Oh SN, Jung CK, et al. Correlation of dynamic contrast-enhanced MRI perfusion parameters with angiogenesis and biologic aggressiveness of rectal cancer: Preliminary results. *J Magn Reson Imaging* 2015; 41:474–480. [\[CrossRef\]](#)
32. Hötker AM, Tarlinton L, Mazaheri Y, et al. Multiparametric MRI in the assessment of response of rectal cancer to neoadjuvant chemoradiotherapy: A comparison of morphological, volumetric and functional MRI parameters. *Eur Radiol* 2016; 26:4303–4312. [\[CrossRef\]](#)
33. Attenberger UI, Ong MM, Rathmann N, et al. mMRI at 3.0 T as an evaluation tool of therapeutic response to neoadjuvant CRT in patients with advanced-stage rectal cancer. *Anticancer Res* 2017; 37:215–222. [\[CrossRef\]](#)
34. Sun H, Xu Y, Song A, et al. Intravoxel incoherent motion MRI of rectal cancer: correlation of diffusion and perfusion characteristics with prognostic tumor markers. *AJR Am J Roentgenol* 2018; 210:W139–W147. [\[CrossRef\]](#)
35. Zhu L, Pan Z, Ma Q, et al. Diffusion kurtosis imaging study of rectal adenocarcinoma associated with histopathologic prognostic factors: preliminary findings. *Radiology* 2017; 284:66–76. [\[CrossRef\]](#)
36. Cui Y, Yang X, Du X, et al. Whole-tumour diffusion kurtosis MR imaging histogram analysis of rectal adenocarcinoma: Correlation with clinical pathologic prognostic factors. *Eur Radiol* 2018; 28:1485–1494. [\[CrossRef\]](#)