

A pediatric case of Zenker diverticulum: imaging findings

Süreyya Burcu Görkem, Ali Yıkılmaz, Abdülhakim Coşkun, Mustafa Küçükaydın

ABSTRACT

Zenker diverticulum is known as an adult disease which occurs as result of outpouching of pharyngeal mucosa through a weak zone in the posterior wall of the pharynx. It is a very rare disorder in childhood, and only a few pediatric cases of Zenker diverticulum have been reported. Here, we report a 10-year-old boy with Zenker diverticulum who presented with aspiration pneumonia, dysphagia, regurgitation, and halitosis. The radiologic evaluation of the patient included chest radiography, ultrasonography, esophagography, and chest computed tomography which clearly demonstrated the pathological findings and confirmed the diagnosis.

Key words: • Zenker diverticulum • pediatrics • radiology

Zenker diverticulum is the most common diverticulum of the esophagus. The symptoms of Zenker diverticulum include dysphagia, regurgitation, cough, and halitosis. It is seen primarily in the sixth to ninth decades and is very rare in childhood, with only a few pediatric cases reported (1–4). We describe a boy with Zenker diverticulum and discuss the imaging findings in light of the literature.

Case report

A 10-year-old boy presented with cough, fever, wheezing, halitosis, regurgitation, and weight loss. The symptoms were recurrent but had worsened in the previous two years. He also had the phenotypic features of Marfan syndrome, with cutis laxa, arachnoid hand, and elongated extremities. Chest radiograph was obtained considering these symptoms to confirm the diagnosis of pneumonia. Chest radiograph showed bilateral perihilar pneumonic infiltrations and linear atelectasis (Fig. 1). Chest computed tomography (CT) was obtained for further evaluation of pneumonia and to assess possible lymphadenopathy; lymphadenopathy is seen in tuberculosis, which is endemic in Turkey. CT revealed a diverticular pouch filled with air and food particles, compressing the trachea (Fig. 2). CT also showed bilateral pneumonic infiltrations without any mediastinal or hilar lymphadenopathy.

Although the diagnosis of esophagus diverticulum was clear on the basis of CT findings, an esophagogram was performed to confirm the diagnosis and for better depiction of the lesion. On the esophagogram, outpouching of barium in the left hypopharyngeal region was visualized (Fig. 3). Because the finding was rare and unexpected, neck ultrasonography (US) was performed to confirm the presence of the diverticulum.

US was carried out by using a 7.5 MHz transducer (Toshiba SSA-250A, Tokyo, Japan). US revealed a solid-like heterogeneous lesion located posteroinferior to the left thyroid gland; the lesion had hypochoic and hyperechoic foci, and posterior acoustic enhancement (Fig. 4). The thyroid gland was normal, and there was no cervical lymphadenopathy.

The diagnosis of Zenker diverticulum was made based on the radiological findings. Surgical diverticulectomy was performed. Histopathologic evaluation revealed esophageal mucosa lining the diverticulum. On follow-up, the patient was free of symptoms after 7 months (Fig. 5).

Discussion

Zenker diverticulum is protrusion of pharyngeal mucosa through a weak zone in the posterior wall of the pharynx, known as Killian's dehiscence. This is the site of herniation of Zenker diverticulum (which is actually a pseudodiverticulum). It is considered a pulsion diverticulum, because it is associated with high intraluminal pressure. The etiology is not completely understood; it has been proposed that patients with Zenker

From the Departments of Radiology (S.B.G. ✉ drburcugorkem@gmail.com, A.Y., A.C.) and Pediatric Surgery (M.K.), Erciyes University School of Medicine, Kayseri, Turkey.

Received 22 June 2007; revision requested 14 December 2007; revision received 14 December 2007; accepted 24 December 2007.

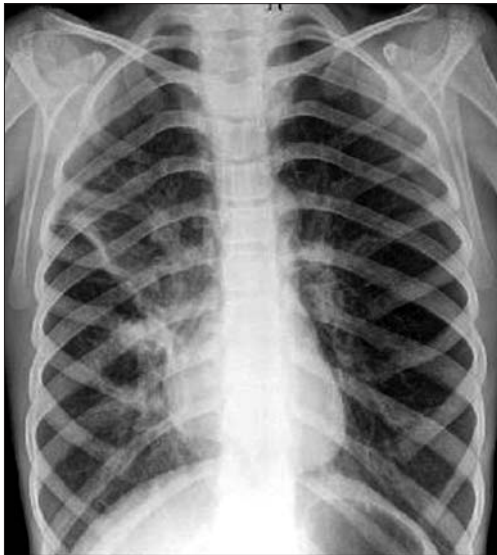

Figure 1. Posteroanterior chest radiograph shows bilateral central peribronchial infiltrations and a linear opacity, consistent with atelectasis, located along with the obliquely oriented minor fissure. Bilateral hila are enlarged.

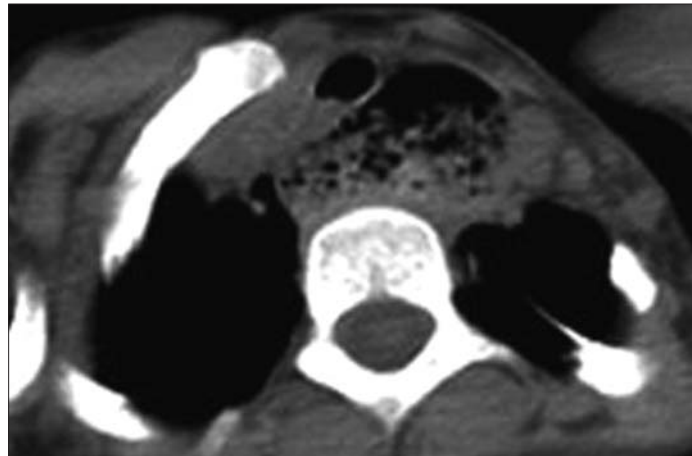


Figure 2. Axial chest CT image shows the pouch of the diverticulum filled with air and food particles, compressing the trachea.

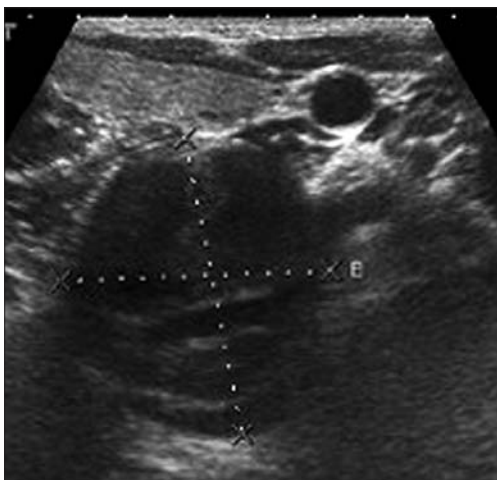


Figure 3. The neck ultrasound shows a lesion located posteroinferior to the left thyroid gland; the lesion has hypoechoic and hyperechoic foci and posterior acoustic enhancement.

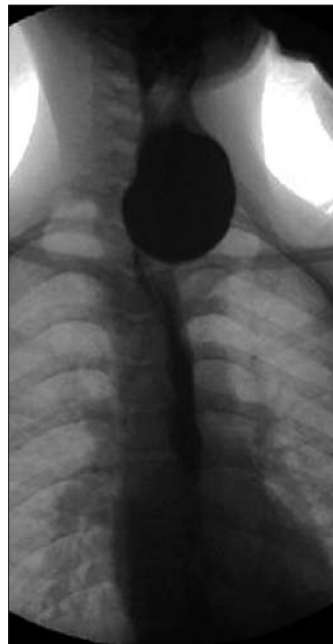


Figure 4. The esophagogram shows an outpouching of barium located in the left hypopharyngeal region.

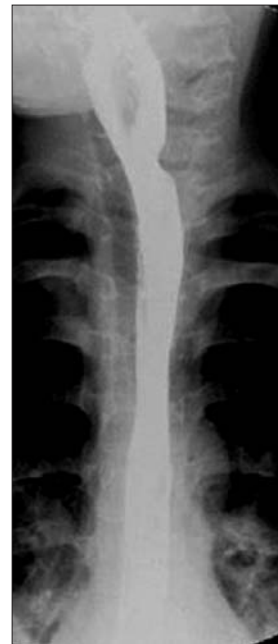

Figure 5. Postoperative esophagogram shows a normal hypopharyngeal region.

diverticulum have improper relaxation of the cricopharyngeus muscle during swallowing. Zenker diverticulum is an infrequent disorder in children and is considered to be an acquired entity (5). The pathophysiology of Zenker diverticulum in children does not differ from the adult type.

Our patient's clinical presentation had both similarities and differences in comparison to the classical symptoms of Zenker diverticulum. Dysphagia, regurgitation, cough, aspiration, and

halitosis are common symptoms associated with the adult type.

Only two children with Zenker diverticulum were reported before Fiser et al. reported a 10-year-old boy with Zenker diverticulum in 1981 (1). Results of surgery were reported in a 6-year-old girl with Zenker diverticulum by Dokucu et al. (2). A 21-day-old female neonate with perforated pharyngeal pseudodiverticulum in the pharyngoesophageal junction has also been reported (3). Our patient was delivered in a hospital without compli-

cations and did not require resuscitation or nasogastric intubation.

In our patient, posteroanterior chest radiograph showed bilateral perihilar pneumonic infiltrations. A chest CT was obtained for further evaluation of pneumonia and to assess possible lymphadenopathy related to endemic tuberculosis. On CT, axial images revealed a diverticular pouch filled with air and food particles, compressing the trachea. CT also revealed that there were no mediastinal or hilar lymphadenopathy. The presumed etiology of

pneumonia was aspiration of retained material in the diverticulum, and the wheezing was likely caused by compression of the trachea by the diverticulum.

Since esophagography has been the primary imaging technique for the diagnosis of regurgitation and esophageal diseases, an esophagogram was performed in our patient. An outpouching filled with barium, located in left hypopharyngeal region, was visualized. Morton and Bartley classified diverticula according to size (6). A longitudinal diameter <2 cm was classified as small, and 2–4 cm as medium; a diameter >4 cm was classified as large. In our case, the diverticulum was in the medium-size group, with a diameter of 3 cm.

Reported US findings of Zenker diverticulum in the literature include isoechoic or hypoechoic mass with internal or peripheral echogenic foci and a hypoechoic boundary zone at the posteroinferior portion of the left thyroid (7). The contents of the diverticulum, such as air, fluid, or debris, were represented with internal echoes and minimal posterior acoustic enhancement. There have been three reports describing US findings of Zenker diverticulum; one included four cases and two included three cases of Zenker diverticulum each (4, 8). All reported cases were adults; there are no reports of US findings of Zenker diverticulum in children.

In the literature, Zenker diverticulum has been reported to coexist with Marfan syndrome (9). Marfan syndrome is an autosomal dominant genetic disorder

of the elastic fibers of the connective tissue. Classical Marfan syndrome is the most frequent form of presentation in childhood and adolescence, with a hereditary background in 70% to 85% of the cases. Despite the abundance of elastic tissues throughout the gastrointestinal tract, there are no reports of gastrointestinal manifestations in Marfan syndrome. Phenotypic features in our patient were suggestive, but not diagnostic, of Marfan syndrome. We speculate that there is an abnormally weak wall in the esophagus related to the connective tissue disorder.

Treatment of the Zenker diverticulum varies according to the location, symptoms, and size of the diverticulum. Endoscopic stapling, diverticulectomy, or diverticulopexy might be carried out. Our patient underwent open diverticulectomy. Some authors reported a lower recurrence rate when myotomy was associated with diverticulectomy; however, more data are needed to confirm this hypothesis (10). Our patient has had no recurrence of the disorder during 7 months of follow-up.

A true diverticulum consists of all layers of the wall. Histopathologic examination of the diverticulum in our patient showed that it was a pseudo-diverticulum with involvement of only the mucosal layer.

In conclusion, although Zenker diverticulum is considered to be an adult disease, children may present with Zenker diverticulum as well. It should be included in the differential diagnosis of a child with regurgitation, halitosis, and aspiration pneumonia. If clinical

suspicion exists, radiologic studies should be carried out to confirm the diagnosis. Radiologists should be aware of the imaging findings of Zenker diverticulum in order to make an early and prompt diagnosis.

References

1. Fiser WP, Euler AR, Golladay ES. Pharyngoesophageal pulsion diverticulum (Zenker) in a ten-year-old boy. *J Pediatr Surg* 1981; 16:727–729.
2. Dokucu AI, Fabre M, Otcu S, et al. Zenker's diverticulum in childhood: a new case. *Eur J Pediatr Surg* 2000; 10:191–193.
3. Sarin YK, Goel D, Mathur NB, Maria A. Neonatal pharyngeal pseudo-diverticulum. *Indian Pediatr* 2000; 37:1134–1137.
4. Kumar A, Aggarwal S, Pham DH. Pharyngoesophageal (Zenker's) diverticulum mimicking thyroid nodule on ultrasonography: report of two cases. *J Ultrasound Med* 1994; 13:319–322.
5. Ruiz-Tovar J, Perez de Oteyza J, Collado MV, Rojo R, Garcia Villanueva A. 20 years experience in the management of Zenker's diverticulum in a third-level hospital. *Rev Esp Enferm Dig* 2006; 98:429–435.
6. Morton RP, Bartley JR. Inversion of Zenker's diverticulum: the preferred option. *Head Neck* 1993; 15:253–256.
7. Kwak JY, Kim EK. Sonographic findings of Zenker diverticula. *J Ultrasound Med* 2006; 25:639–642.
8. Biggi E, Derchi LE, Cicio GR, Neumaier CE. Sonographic findings of Zenker's diverticulum. *J Clin Ultrasound* 1982; 10:395–396.
9. Eliashar R, Sichel JY, Biron A, Dano I. Multiple gastrointestinal complications in Marfan syndrome. *Postgrad Med J* 1998; 74:495–497.
10. Lerut T, van Raemdonck D, Guelinckx P, Dom R, Geboes K. Zenker's diverticulum: is a myotomy of the cricopharyngeus useful? How long should it be? *Hepatogastroenterology* 1992; 9:127–131.