

# Popliteal artery branching patterns detected by digital subtraction angiography

Ertuğrul Mavili, Halil Dönmez, Güven Kahriman, Aysel Özaşlamacı, Nevzat Özcan, Kutay Taşdemir

## PURPOSE

To describe the popliteal and distal branching patterns detected by digital subtraction angiography.

## MATERIALS AND METHODS

The popliteal branching patterns were analyzed in 535 extremities (270 right, 265 left). Of these, 226 limbs were evaluated bilaterally, while 83 were evaluated unilaterally. The branching patterns were classified according to the level of branching and the presence of hypoplasia or aplasia of the distal branches.

## RESULTS

Four hundred and seventy-two (88.1%) limbs had a normal level of popliteal artery branching. Type IA was the most frequently encountered pattern. High division of the popliteal artery was seen in 30 (5.6%) limbs. Type IIA was the most frequently encountered pattern among these limbs. Type IIC was not seen. We encountered a new pattern characterized by high division of the peroneal artery with a trifurcation pattern and an anterior tibial artery with a proximal medial course and a distal lateral course. We called this pattern Type IID. Thirty-three (6.1%) limbs exhibited hypoplasia/aplasia of the distal branches. Type IIIA was the most frequently encountered pattern among these limbs.

## CONCLUSION

Variations that occur in nearly 10% of patients should be understood because they may affect the choice of management strategy.

*Key words:* • popliteal artery • peroneal artery • posterior tibial artery • anterior tibial artery • digital subtraction angiography

**A**wareness of the anatomical variability determined by embryonic vascular development is important for radiologists and surgeons. Popliteal arterial variation may have clinical implications for vascular grafting, direct surgical repair, transluminal angioplasty, or embolectomy. Moreover, differentiating occlusion or arterial injury from variation depends on the clinician's knowledge of variations (1–10). Therefore, we aim to describe popliteal arterial variations.

## Materials and methods

The femoral angiograms of 535 extremities (270 right, 265 left) in 350 consecutive patients who provided informed consent for the digital subtraction angiography (DSA) procedure were retrospectively examined. Of these, 226 limbs were evaluated bilaterally, and 83 limbs were evaluated unilaterally.

The branching patterns were classified according to the system used by Kim et al. (Figs. 1a, 2a, 3a) (1). A normal level of popliteal branching (below the level of the tibial plateau) was classified as Type I. Type I was further divided into Type IA, in which the anterior tibial artery (AT) is the first branch, and the peroneal artery (PR) and posterior tibial artery (PT) arise from the tibioperoneal trunk (Fig. 1b); IB, in which there is no true tibioperoneal trunk and AT, PT, and PR arise within 0.5 cm (Fig. 1c); and IC, in which the PT is the first branch and AT and PR arise from the anterior tibioperoneal trunk (Fig. 1d).

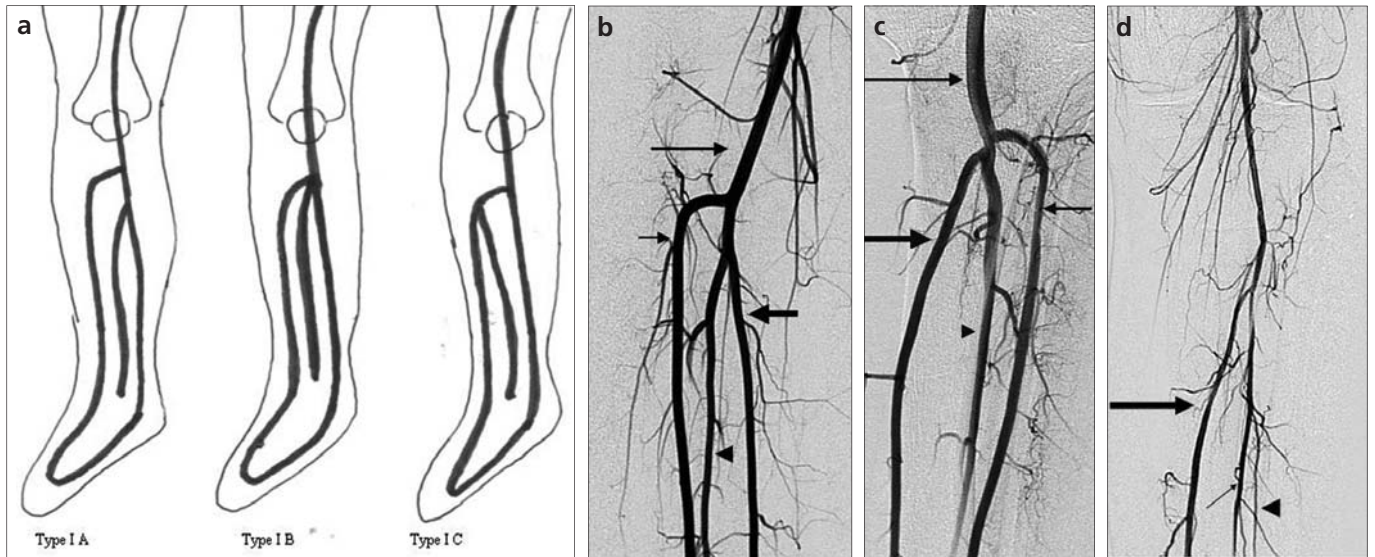
High division of the popliteal artery (at or above the level of the tibial plateau) was classified as Type II. This classification was further divided into Type IIA1, in which the AT arises above the knee and has a normal course (Fig. 2b); IIA2, in which the AT arises above the knee and has an initial medial curve (Fig. 2c); IIB, in which the PT is the first branch and arises above the knee joint, and the AT and PR have a common trunk (Fig. 2d); IIC, in which the PR is the first branch and arises above the knee joint, and the AT and PT have a common trunk; and IID, which involves high division of the popliteal artery with a trifurcation pattern and an AT with an initial medial course and a distal lateral course (Figs. 2e and 2f).

Hypoplastic or aplastic branching with altered distal supply was classified as Type III. This group was further divided into Type IIIA, in which the PT is hypoplastic and the distal PT is replaced by the PR (Figs. 3b and 3c); Type IIIB, in which the AT is hypoplastic and the dorsalis pedis (PD) is replaced by the PR (Figs. 3d and 3e); and Type IIIC, in which the AT and PT are hypoplastic and the distal PT and DP are replaced by the PR (Figs. 3f and 3g).

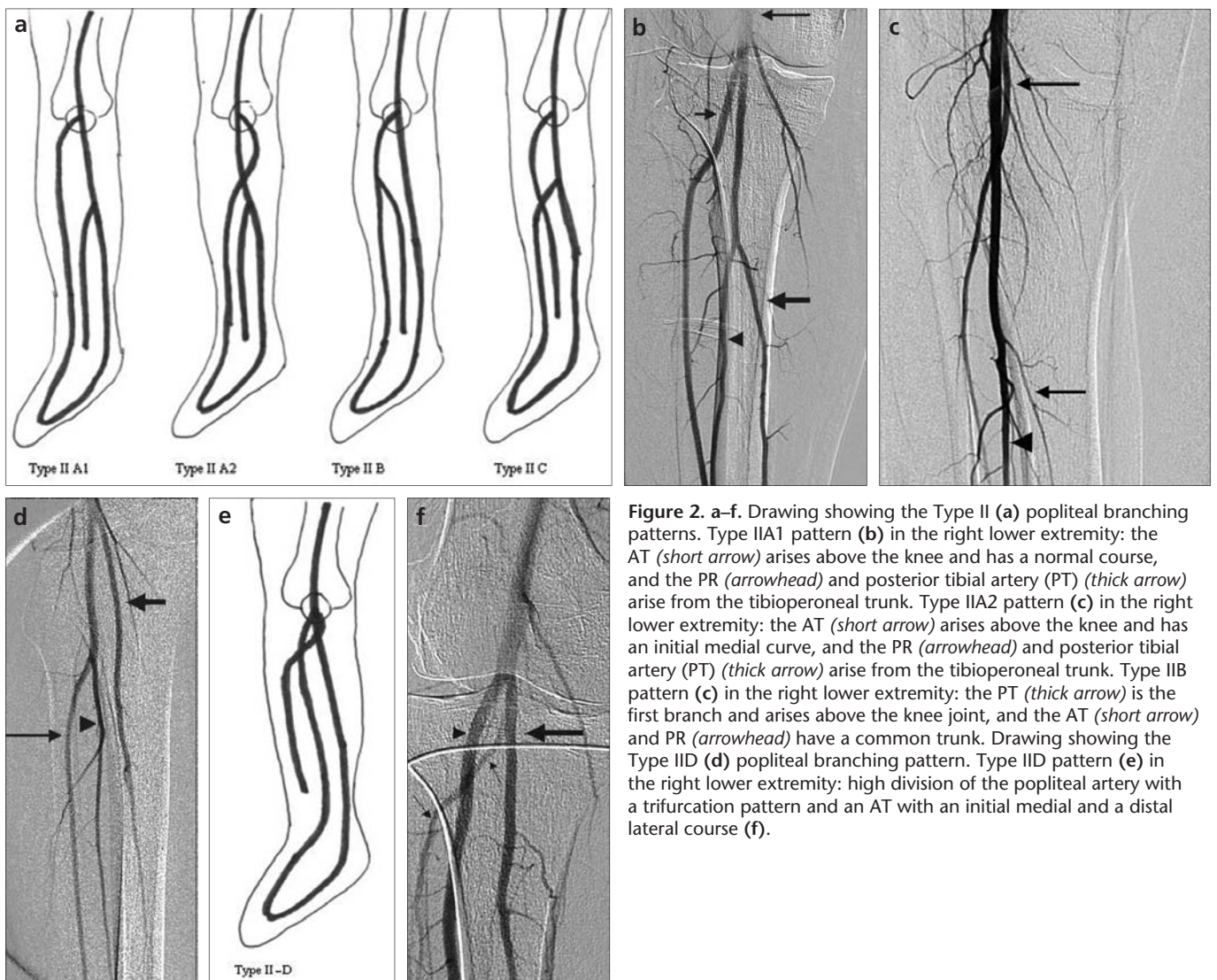
From the Departments of Radiology (E.M. ✉ [emavili@erciyes.edu.tr](mailto:emavili@erciyes.edu.tr), H.D., G.K., A.Ö., N.Ö.), and Cardiovascular Surgery (K.T.), Erciyes University School of Medicine, Kayseri, Turkey.

Received 26 November 2009; revision requested 4 January 2010; revision received 23 February 2010; accepted 7 March 2010.

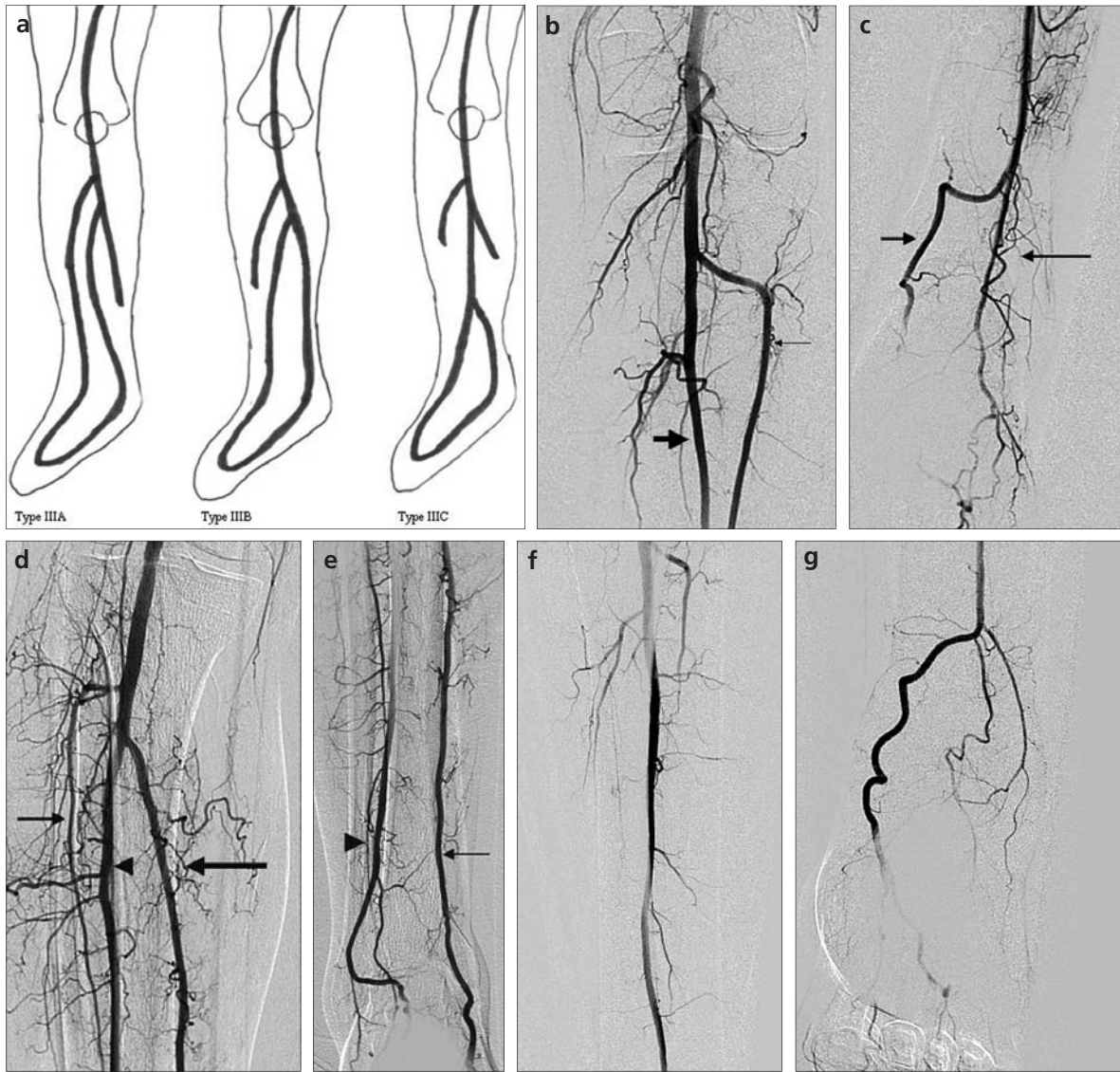
Published online 13 August 2010  
DOI 10.4261/1305-3825.DIR.3141-09.1



**Figure 1.** a–d. Drawing showing the Type I (a) popliteal branching patterns. Type IA pattern (b) in the right lower extremity; the anterior tibial artery (AT) (*short thin arrow*) is the first branch; the peroneal artery (PR) (*arrowhead*) and posterior tibial artery (PT) (*long thick arrow*) arise from the tibio-peroneal trunk. Type IB pattern (c) in the left lower extremity; there is no true tibio-peroneal trunk, and the AT (*thin arrow*), PT (*thick arrow*), and PR (*arrowhead*) arise within 0.5 cm. Type IC pattern (d) in the left lower extremity; the PT (*long thick arrow*) is the first branch, and the PR (*arrowhead*) arises from the AT (*thin arrow*).



**Figure 2.** a–f. Drawing showing the Type II (a) popliteal branching patterns. Type IIA1 pattern (b) in the right lower extremity: the AT (*short arrow*) arises above the knee and has a normal course, and the PR (*arrowhead*) and posterior tibial artery (PT) (*thick arrow*) arise from the tibio-peroneal trunk. Type IIA2 pattern (c) in the right lower extremity: the AT (*short arrow*) arises above the knee and has an initial medial curve, and the PR (*arrowhead*) and posterior tibial artery (PT) (*thick arrow*) arise from the tibio-peroneal trunk. Type IIB pattern (d) in the right lower extremity: the PT (*thick arrow*) is the first branch and arises above the knee joint, and the AT (*short arrow*) and PR (*arrowhead*) have a common trunk. Drawing showing the Type IID (e) popliteal branching pattern. Type IID pattern (e) in the right lower extremity: high division of the popliteal artery with a trifurcation pattern and an AT with an initial medial and a distal lateral course (f).



**Figure 3.** a–g. Drawing showing the Type III (a) popliteal branching patterns. Type IIIA pattern (b) in the left lower extremity: the AT artery (long thin arrow) and PR (short thick arrow) artery are visible, but the PT artery is aplastic, and the distal PT is replaced by the PR artery (c). Type IIIB pattern (d) in the right lower extremity: the PT artery (long thin arrow) and PR (short thick arrow) artery are visible, but the AT artery is hypoplastic, and the distal AT artery is replaced by the PR artery (e). Type IIIC pattern (f) in the left lower extremity: the PR artery is visible, but both the PT and AT arteries are aplastic. The dorsalis pedis artery and plantar arteries are formed by the PR artery (g).

**Table.** Distribution of the popliteal branching patterns

Branching type	Number of limbs
Type IA	441 (82.4%)
Type IB	29 (5.4%)
Type IC	2 (0.4%)
Type IIA1	14 (2.6%)
Type IIA2	7 (1.3%)
Type IIB	8 (1.5%)
Type IIC	0 (0%)
Type IID	1 (0.2%)
Type IIIA	20 (3.7%)
Type IIIB	12 (2.2%)
Type IIIC	1 (0.2%)

## Results

The branching patterns of the limbs are summarized in Table. Of the 226 bilaterally evaluated patients, 172 (76.1%) (163 Type IA, 3 Type IB, 2 Type IIA, 3 Type IIIA, and 1 Type IIIB) exhibited a bilaterally symmetric pattern.

Four hundred and seventy-two limbs (88.1%) had a normal level of popliteal artery branching. Type IA, the usual pattern, was the most frequently encountered pattern and was seen in 441 limbs (82.4%). The Type IB trifurcation pattern was seen in 29 limbs (5.4%). The posterior tibial artery was the first branch (Type IC) in 2 limbs (0.3%).

High division of the popliteal artery was seen in 30 limbs (5.6%). No instances of the peroneal artery arising from the popliteal artery above the knee joint (Type IIC) were observed in this study. Twenty-one limbs (3.9%) showed a high division of the AT from the popliteal artery at or above the level of the tibial plateau. The AT followed a normal course in 14 limbs (2.6%) (Type IIA1). In 7 limbs (1.3%), the AT had an initial medial course (Type IIA2). High division of the PT from the popliteal artery (Type IIB) was seen in 8 limbs (1.5%). In this study, we encountered high division of the popliteal artery with a trifurcation pattern and an AT with an initial medial course and a distal lateral course, which we called Type IID.

The distal branching pattern was also examined in these patients. Thirty-three limbs (6.1%) had hypoplasia–aplasia of the distal branches. The PT was hypo- or aplastic (Type IIIA) in 20 limbs (3.7%). The AT was hypo- or aplastic (Type IIIB) in 12 limbs (2.2%). Hypo- or aplasia of both the PT and the AT (Type IIIC) was seen in 1 patient (0.2%).

## Discussion

The popliteal and peroneal arteries are derived from the primitive middle and distal segments of the sciatic artery, which is an embryonic vessel that supplies the lower limbs. The sciatic artery arises from the dorsal root of the umbilical artery and runs through the thigh, knee, and leg, and below the knee it lies between the tibia and popliteus (2, 3). The anterior and posterior tibial arteries derive from the femoral system. At the distal border of the popliteus, a perforating branch that communicates with the femoral artery arises from the sciatic artery. This branch, called the ramus communicans, passes ventrally between the tibia and fibula and forms the anterior tibial artery (2–4). The posterior tibial artery is formed by an anastomosis between the early distal femoral artery and the popliteal artery (2). Persistent primitive arterial segments, abnormal fusions, segmental hypoplasia, or the absence of these arteries give rise to anatomic variability (4).

The incidence of normal popliteal branching ranges between 92–96% (3–

6). Type IA is the most frequently encountered pattern in both prior studies and the present study. In this study, the percentage of patients with a normal level of branching was 88.1%.

The Type II pattern was encountered in 5.6% of the limbs in this study, a value in concordance with previous reports (1, 4–6). The Type IIA and Type IIB patterns are relatively frequent, but the Type IIC pattern is extremely rare, and only 3 cases of the Type IIC pattern have been reported (1, 6). We did not observe the Type IIC pattern in this study, but we encountered a new pattern that has not been previously described. In this case, the popliteal artery had a high division with a trifurcation pattern, and the anterior tibial artery arose medially and then turned laterally.

Kim et al. (1) reported that Type III variation was present in 5.6% of limbs, but Day and Orme (6) found this variation in only 1% of limbs. They claimed that this difference might be due to the difficulty in distinguishing between congenital and acquired arterial abnormalities in patients with atherosclerotic disease. Gradual tapering of the hypoplastic artery, lack of collateral circulation, and a straight, non-undulating course for the distal PR to reach the PT or DP without transitional tapering at the junction of these vessels all indicate variation, but it should be kept in mind that despite these findings, it may be very difficult to differentiate congenital arterial abnormalities from acquired arterial abnormalities (6). Finally, we found the Type III pattern in 6.1% of patients.

Individuals working with angiography, duplex ultrasound, magnetic resonance angiography and computed tomography angiography should understand these variations to prevent misinterpretation of test results (6). Moreover, recognizing anatomical variation is necessary for planning radiological and surgical interventions (1–10). Despite improvements in vascular surgical techniques, patients with a high-origin anterior tibial artery lying posterior to the popliteus are vulnerable to arterial complications, including transection, fistula formation, pseudoaneurysm, and thrombosis, during orthopedic procedures such as high

tibial osteotomy, revision total knee arthroplasty, lateral meniscal repair, posterior cruciate ligament reconstruction, and screw fixation for tibial tubercle osteotomy (2, 11). Knowledge about hypoplastic or aplastic branching with altered distal supply is important in planning angioplasty and peroneal artery harvesting. In the presence of the Type III variation, it may be necessary to modify the angioplasty technique. In addition, if the very rare Type IIIC pattern (hypoplasia–aplasia of both the AT and the PT) is present, harvesting of the peroneal artery is contraindicated because this artery is the only artery that feeds the distal parts of the limb. Therefore, knowledge of these variations will change the treatment strategy (1–11).

## References

1. Kim D, Orron DE, Skillman JJ. Surgical significance of popliteal arterial variants. A unified angiographic classification. *Ann Surg* 1989; 210:776–781.
2. Tindall AJ, Shetty AA, James KD, Middleton A, Fernando KW. Prevalence and surgical significance of a high-origin anterior tibial artery. *J Orthop Surg* 2006; 14:13–16.
3. Jung W, Oh CS, Won HS, Chung IH. Unilateral arteria peronea magna associated with bilateral replaced dorsalis pedis arteries. *Surg Radiol Anat* 2008; 30:449–452.
4. Mauro MA, Jaques PF, Moore M. The popliteal artery and its branches: embryological basis of normal and variant anatomy. *AJR Am J Roentgenol* 1988; 150:435–437.
5. Szpinda M. Digital-image analysis of the angiographic patterns of the popliteal artery in patients with aorto-iliac occlusive disease (Leriche syndrome). *Ann Anat* 2006; 188:377–382.
6. Day CP, Orme R. Popliteal artery branching patterns an angiographic study. *Clin Radiol* 2006; 61:696–699.
7. Vazquez T, Rodríguez-Niedenfuhr M, Parkin I, Viejo F, Sanudo J. Anatomic study of blood supply of the dorsum of the foot and ankle. *Arthroscopy* 2006; 22:287–290.
8. Cross L, Hall J, Howdieshell TR, Colborn GL, Gale TF. Clinical anatomy of the popliteal blood vessels. *Clin Anat* 2000; 13:347–353.
9. Colborn GL, Lumsden AB, Taylor BS, Skandalakis JE. The surgical anatomy of the popliteal artery. *Am Surg* 1994; 60:238–246.
10. Sanders RJ, Alston GK. Variations and anomalies of the popliteal and tibial arteries. *Am J Surg* 1986; 152:531–534.
11. Klecker RJ, Winalski CS, Aliabadi P, Minas T. The aberrant anterior tibial artery: magnetic resonance appearance, prevalence, and surgical implications. *Am J Sports Med* 2008; 36:720–727.