

Gastric stromal tumor

Gülgün Yılmaz Ovalı, Serdar Tarhan, Selim Serter, Yüksel Pabuşçu

ABSTRACT

Gastric stromal tumors are rare neoplasms of the stomach. In this report we present a gastric stromal tumor with an exophytic growth pattern, and describe magnetic resonance imaging and endoscopic ultrasonography findings.

Key words: • stomach, neoplasms • magnetic resonance imaging • ultrasonography

Gastric stromal tumors are rare neoplasms of the stomach, which account for approximately 3.6% of all gastric tumors. In this report we present a gastric stromal tumor with an exophytic growth pattern, which was seen as a large mass outside the organ of origin. We describe both the magnetic resonance (MR) imaging and endoscopic ultrasonography (US) findings as well as discuss the differential diagnosis.

Case report

A 62-year-old male patient was admitted to the emergency department with vertigo, weakness, nausea, and vomiting. The patient had been followed up for diabetes mellitus type 2 and complications due to diabetes mellitus for 20 years. During physical examination, a palpable mass was identified on the left upper abdominal quadrant. Abdominal ultrasonography (US) was performed and a mass with heterogenous echo pattern, measuring 12x9 cm in size, was observed on the left side of the midline. MR imaging was planned instead of computed tomography (CT) because intravenous contrast medium was contraindicated due to diabetic nephropathy. In abdominal MR imaging, there was a mass, which was growing outside the gastric body and antrum. The mass had necrosis in some areas and it had low signal intensity on T1-weighted images and high signal intensity on T2-weighted images (Figure 1). The mass growing outside the gastric wall was adjacent to the pancreatic tail and spleen (Figure 2a). There was a significant enhancement after intravenous gadolinium-DTPA injection (Figure 2). Although the mass was close to the neighboring organs, there was no invasion to the surrounding tissues. MR imaging did not reveal the lymph nodes with pathological size. Endoscopic examination was performed to determine mucosal pathology and endoscopic US was performed to determine the relationship between the mass and gastric wall. In endoscopy, gastric mucosa appeared intact, but there was an impression outside the stomach to the gastric lumen. The mass had originated from submucosa and was growing outside the gastric wall with an exophytic pattern, had necrosis in some areas, and a heterogenous echo pattern in endoscopic US (Figure 3). Radiological findings were first believed to be indicative of a malignant mass. Following total gastric resection, however, the pathology of the mass was reported as a benign gastric stromal tumor (Figure 4).

Discussion

Gastric stromal tumors are rare mesenchymal neoplasms of the stomach, which account for approximately 3.6% of all gastric tumors (1). Previously, gastrointestinal mesenchymal tumors were categorized into two subgroups as benign and malignant smooth muscle tumors. Today, these tumors are classified as gastrointestinal stromal tumors. Stromal tumors

From the Department of Radiology (G.Y.O. ✉ gulgun.yilmaz@bayar.edu.tr), Celal Bayar University School of Medicine, Manisa, Turkey.

Received 25 December 2003; revision requested 7 April 2004; revision received 29 April 2004; accepted 4 May 2004.

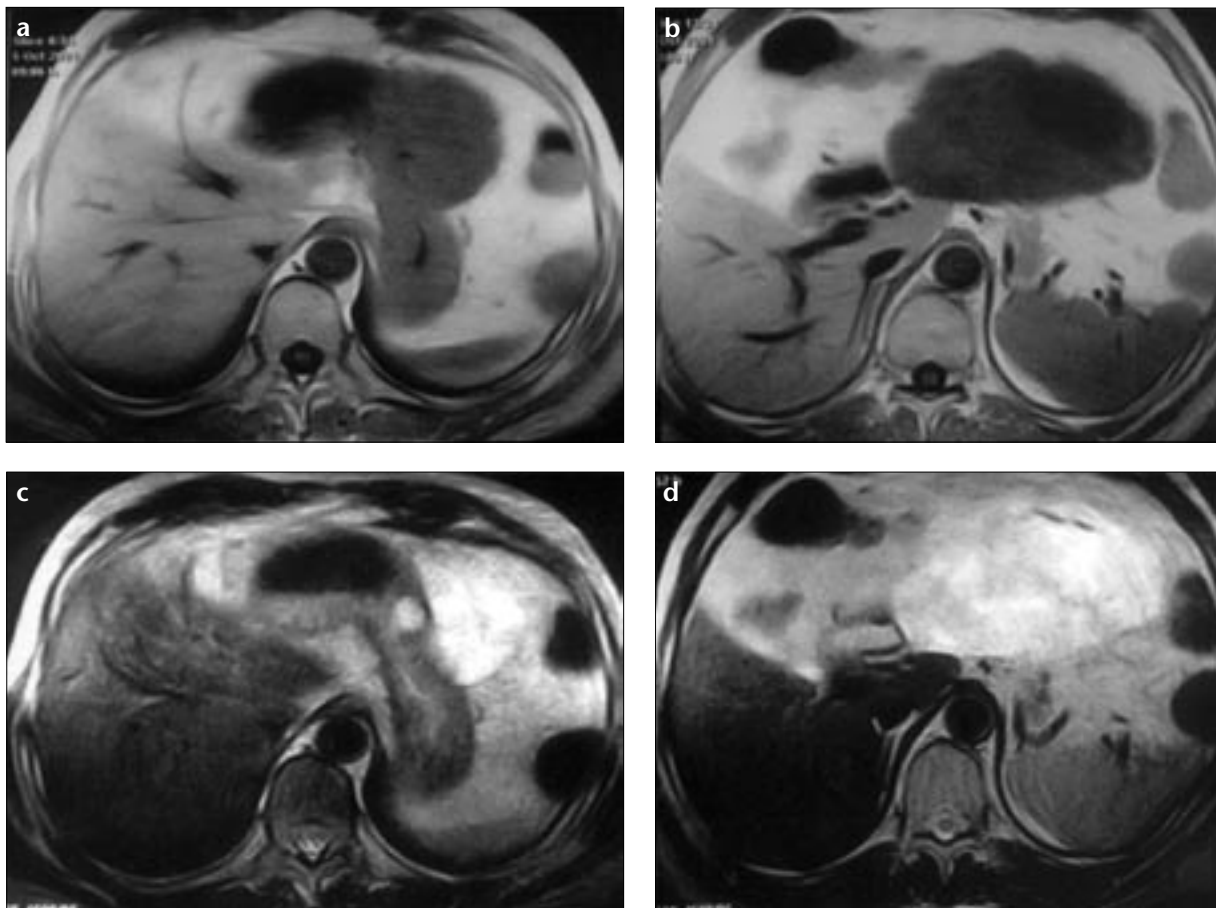


Figure 1. a-d. Transverse precontrast T1-weighted (a, b) and T2-weighted (c, d) MR images show an exophytic gastric mass, which is hypo- and hyperintense in relation to the stomach on T1- and T2-weighted images, respectively.

generally originate from epithelioid and spindle-like cells and do not differentiate into schwannoma and smooth muscle cells (2). The ratio of male to female cases is 3:1 and the average age of patients presenting with the tumor is between 40-60 years. They originate from gastric antrum and body in 70-90% of cases. They grow in an exophytic pattern in 30-40%, intraluminal pattern in 29-44%, endoluminal pattern in 18-22% and a mixed pattern in 16-20% of all cases. An exophytic component of the tumor is predominant because usually all stromal tumors originate from muscularis propria of the gastric and intestinal wall (3).

Gastric stromal tumors are sometimes multifocal and their size is variable. As it may be completely solid, it may also have pseudocystic degeneration. There also may be hemorrhage inside the tumor (1). Upper gastrointestinal system barium examinations may be useful for the differential diagnosis of endoluminal tumors. However, their appearance cannot be distinguished from extrinsic

compression of an extragastric tumor. Endoscopic US is useful for determining the gastric origin of the mass (4). In our case, during endoscopic US, we observed that the mass had originated from submucosa of the gastric wall and was extending outside the organ of origin with an exophytic growth pattern.

Multiplanar imaging methods, such as CT and MR imaging are very useful for making differential diagnoses. MR imaging signal intensity of stromal tumors are variable. Hemorrhage and necrosis inside the mass cause the variability of signal intensity. Generally, the solid component is hypointense on T1-weighted images, hyperintense on T2-weighted images, and has significant enhancement after intravenous contrast medium injection, as seen in our case. If there are hemorrhagic areas, they are seen as variable signal intensities on T1-weighted and T2-weighted images due to their bleeding phase (3). Because gastric tumors are usually hypervascular and cross-sectional imaging methods are insufficient for

making a diagnosis, vascularity of the tumor can be determined by performing angiography. Their feeding arteries may originate from the gastroduodenal artery or the left gastric artery (1).

Varying rates of malignant degeneration of gastric stromal tumors have been reported in the literature. Lee et al. have described the rate of malignant degeneration as 27% in their series of 55 cases (5). Mass size greater than 5 cm, a dominant exophytic component, heterogenous enhancement, lobular contours, mesenteric infiltration, and ulceration are the criteria for malignancy of the mass. Curative treatment is surgery (1, 5). There is a low risk of malignant local recurrence and metastasis for large gastric stromal tumors. Radiological and clinical follow-up is necessary due to the malignant potential of stromal tumors (1).

We considered the mass in our case to be malignant because the size of the mass was greater than 5 cm, it had a significant exophytic component, had lobular contours and necrotic areas,

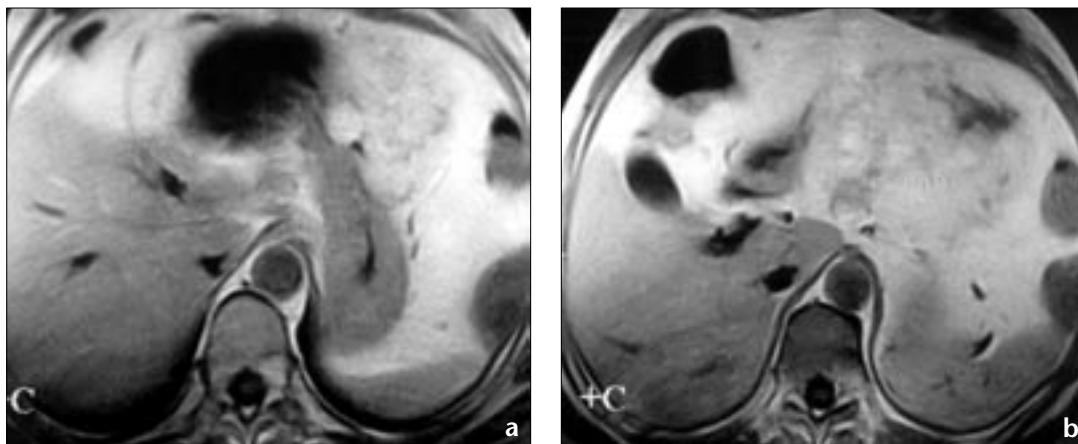


Figure 2. a, b. Focal extension into the gastric wall and significant contrast enhancement of the mass are seen on consecutive transverse post-contrast T1-weighted MR images.

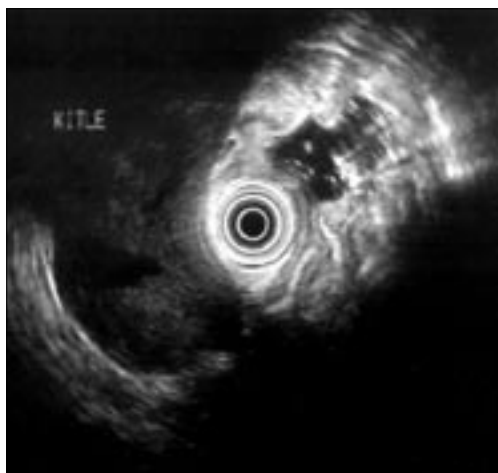


Figure 3. Endoscopic US images show the mass extending outside the gastric wall.

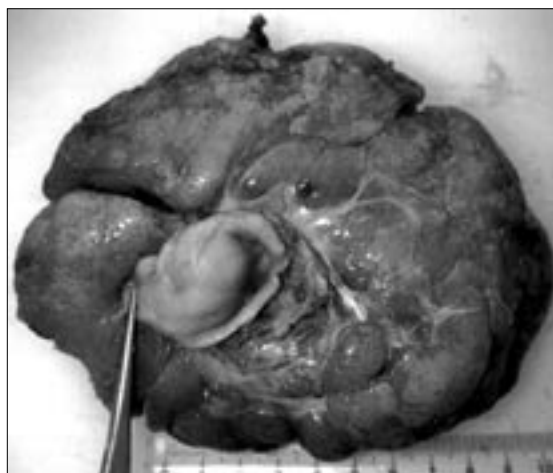

Figure 4. The macroscopic appearance of the mass.

and had significant enhancement on postcontrast images. Although the histopathological diagnosis of the mass was benign stromal tumor, we decided to follow up the patient for a six-month period, since the mass had malignant potential. There was no clinical or sonographic recurrent mass or metastasis in follow ups.

Gastrointestinal stromal tumors can be divided into four major categories on the basis of their immunohistochemical and ultrastructural properties; tumors with features of smooth muscle differentiation; neural differentiation; both smooth muscle and neural elements; tumors lacking differentiation in either cell type. Differential diagnosis is considered histopathologically to define the groups according to their differentiation as described above (5, 6). Gastric stromal tumors are believed to originate from Cajal

cells, which are between the gastrointestinal wall and myenteric plexus (1).

Stromal tumors, such as leiomyoma, leiomyosarcoma, and schwannoma are seen more frequently in the stomach (2, 3). Gastric carcinoids are usually located in antrum and characteristically have central ulceration. Gastric adenocarcinomas and lymphomas rarely have an exophytic component, and are frequently associated with enlarged regional lymph nodes (3).

In conclusion, gastric stromal tumors need to be considered when there is a left upper quadrant mass. Endoscopic US is useful for showing the relationship between the gastric wall and the mass and MR imaging is useful in determining the relationship between the tumor and neighboring organs.

References

1. Mignon F, Julie C, Izzillo R, et al. Imaging features of gastric stromal tumors: radiologic correlation. Report of 4 cases. *J Radiol* 2000; 81:874-881.
2. Kim CJ, Day S, Yeh KA. Gastrointestinal stromal tumors: analysis of clinical and pathologic factors. *Am Surg* 2001; 67:135-137.
3. Levy AD, Remotti HE, Thompson WM, Sobin LH, Miettinen M. Gastrointestinal stromal tumors: radiologic features with pathologic correlation. *Radiographics* 2003; 23:283-304.
4. Tsai TL, Changchien CS, Hu TH, Hsiaw Hsieh KC. Differentiation of benign and malignant gastric tumors using endoscopic ultrasonography. *Chang Gung Med J* 2001; 24:167-173.
5. Lee JSY, Nascimento AG, Farnell MB, et al. Epithelioid gastric stromal tumors: a study of fifty five cases. *Surgery* 1995; 118:653-661.
6. Shirai H, Takeuchi T, Naka T, Minaghi S, Kimaru A, Hamazaki S, Ito H. Gastrointestinal stromal tumor of the stomach: report of a case. *Surg Today* 2001; 31:346-349.