



# Percutaneous nephrostomy in infants: a 20-year single-center experience

- Onur Taydaş<sup>1</sup>  
 Emre Ünal<sup>2</sup>  
 Devrim Akıncı<sup>2</sup>  
 Mehmet Şeker<sup>3</sup>  
 Osman Melih Topçuoğlu<sup>4</sup>  
 Okan Akhan<sup>2</sup>  
 Türkmen Turan Çiftçi<sup>2</sup>

<sup>1</sup>Sakarya University Faculty of Medicine, Department of Radiology, Sakarya, Türkiye

<sup>2</sup>Hacettepe University Faculty of Medicine, Department of Radiology, Ankara, Türkiye

<sup>3</sup>Medipol University Faculty of Medicine, Department of Radiology, İstanbul, Türkiye

<sup>4</sup>Yeditepe University Faculty of Medicine, Department of Radiology, İstanbul, Türkiye

## PURPOSE

To investigate the safety and efficacy of the imaging-guided percutaneous nephrostomy (PCN) procedure in infants.

## METHODS

A total of 75 (50 boys; 66.7%) patients with a mean age of 121 days (range, 1–351 days) who underwent PCN over a period of 20 years were included in this retrospective study. For each patient, PCN indications, catheter size, the mean duration of catheterization, complications, and the procedure performed following nephrostomy were recorded. Technical success was determined based on the successful placement of the nephrostomy catheter within the pelvicalyceal system. Clinical success was defined as the complete resolution of hydronephrosis and improvement in renal function tests during follow-up. In patients with urinary leakage, technical and clinical success was determined based on the resolution of leakage.

## RESULTS

The technical success rate was 100%, and no procedure-related mortality was observed. In 11 patients (14.7%), bilateral PCN was performed. The most frequent indication of PCN was ureteropelvic junction obstruction (n = 41, 54.7%). Procedure-related major complications were encountered in two patients (methemoglobinemia and respiratory arrest caused by the local anesthetic agent in one patient and the development of urinoma caused by urinary leakage from the puncture site in the other). Mild urinary leakage was the only minor complication that occurred and only in one patient. Catheter-related complications were managed through replacement or revision surgery in 16 patients (21.3%).

## CONCLUSION

Imaging-guided PCN is a feasible and effective procedure with high technical success and low major complication rates, and it is useful for protecting kidney function in infants.

## KEYWORDS

Percutaneous nephrostomy, infants, interventional radiology, urinary tract obstruction, complications

Corresponding author: Onur Taydaş

E-mail: taydasonur@gmail.com

Received 20 April 2023; revision requested 11 June 2023; accepted 23 July 2023.



Epub: 18.08.2023

Publication date: 09.09.2024

DOI: 10.4274/dir.2023.232276

**P**ercutaneous nephrostomy (PCN) is the method of choice for external urinary diversion in patients with urinary obstruction or extravasation.<sup>1</sup> It is an indispensable tool, particularly for patients with malignant urinary obstruction because retrograde ureteral stenting is almost always challenging in these patients. The ultrasound-guided approach makes the procedure much safer than the conventional fluoroscopy-guided method. Access to the pelvicalyceal system through PCN may also serve as a feasible route for further interventions, including ureteral balloon dilatation, stenting, and foreign object or stone removal.<sup>2</sup>

Although PCN is routinely performed in adults at every major hospital and a large number of minor hospitals around the world, its applicability in infants and neonates is limited. The procedure can be more challenging in infants than in adults for various reasons, such as the smaller kidney size, lower cutaneous and subcutaneous tissue thickness, lack of perirenal fat

You may cite this article as: Taydaş O, Ünal E, Akıncı D, et al. Percutaneous nephrostomy in infants: a 20-year single-center experience. *Diagn Interv Radiol*. 2024;30(5):318-324.

tissue, more elastic and flexible renal parenchyma, and smaller volume of the pelvicalyceal system.<sup>3</sup> The elasticity of infant kidneys is the most commonly encountered problem. In infants, the kidney can be pushed or even kinked during needle puncturing, which is a rarely encountered incident in adults other than for patients with chronic kidney diseases. In addition, the rapid decompression of the pelvicalyceal system during the procedure may result in the loss of percutaneous access, further complicating the procedure.<sup>4</sup> Moreover, urinary leakage following kidney puncture may be negligible in adults, but it is particularly important for infants because of the smaller volume of their collecting systems. The management of infant patients following PCN is also very different from that of adults.<sup>5,6</sup>

Although PCN placement is an essential element of interventional radiology practice,<sup>3</sup> it is not widely practiced in infants for the reasons outlined above. Despite current studies on nephrostomy in pediatric and newborn patient groups in the literature,<sup>7,8</sup> there are no comprehensive and long-term studies on the infant age group. The fact that this age group includes the neonatal period, which marks an important period for kidney maturation, emphasizes that the evaluation of these patients should be of special interest.<sup>9</sup> In this study, we report our experience with imaging-guided PCN in infants, with an emphasis on the safety and efficacy of the procedure in this patient group.

## Methods

### Patients

Institutional approval for the study was granted by the Hacettepe University Clinical Research Ethics Committee (GO 16/609-06),

and all procedures were in accordance with the principles of the Helsinki Declaration. Informed consent was waived because of the retrospective nature of the study. Patient records were obtained from physical and electronic files, and the images of the patients were acquired from the picture archiving and communication systems of the hospital. The inclusion criteria were as follows: younger than 12 months at the date of the nephrostomy procedure; availability of clinical, imaging, and laboratory findings; and a post-procedure follow-up conducted in our hospital. The exclusion criteria were as follows: older than 12 months at the date of the procedure; incomplete data on clinical, imaging, and laboratory findings; or incomplete post-procedure follow-up. The clinical and radiological data of 75 infants who underwent PCN over a period of 20 years were retrospectively reviewed for the study. A total of 11 patients whose clinical or radiological findings could not be obtained were excluded from the study. The PCN indications, catheter size, duration of catheterization, complications, and any procedures performed following a nephrostomy were recorded for each patient. Technical success was determined based on the successful placement of the nephrostomy catheter within the pelvicalyceal system, whereas clinical success was defined as the complete resolution of hydronephrosis and improvement in renal function tests [blood urea nitrogen (BUN) and creatinine levels] during the follow-up. In patients with urinary leakage, clinical success was determined based on the resolution of leakage (successful urinary diversion).

The treatment results were also evaluated by reviewing the hospital records. Serum creatinine levels and the presence of hydronephrosis were routinely evaluated (at 3-month intervals) in all patients after the procedure. Complications were classified as major or minor according to the criteria of the Society of Interventional Radiology.<sup>10</sup>

### Preprocedural evaluation

Indications of PCN were evaluated using ultrasonography in each patient. Hydronephrosis was graded according to the Society for Fetal Urology classification.<sup>11</sup> Informed written consent was obtained from the parents of the patients prior to the procedure. In addition to routine blood biochemistry and hemogram analyses, coagulation parameters were also examined before each procedure. Nine patients (12%) were already using antibiotics because of bacteriuria iden-

tified through urine culture results; all the remaining patients received prophylactic broad-spectrum antibiotics prior to the procedure. All procedures were performed in an interventional radiology unit and were evaluated through ultrasonography before the procedure and at hour 6 after the procedure. The longitudinal length of the kidney and parenchyma thickness were measured and recorded.

### Procedures

The PCN procedure was performed while the patients were in the prone position. Ultrasound guidance was used to puncture the lower or middle calyx. The kidney was punctured with a 19-G, 18-G, and 21-G needle in 19 (38.7%), 37 (49.3%), and 9 (12%) patients, respectively. Two different techniques were used during the procedure:

1. In patients with severe hydronephrosis, following urine sampling through the needle, contrast material was administered to reveal the pelvicalyceal system under fluoroscopy. A stiff guide wire (Amplatz, Super Stiff; Boston Scientific, Marlborough, MA, USA) was then advanced through the renal pelvis and ureter. Consequently, the tract was dilated, and a nephrostomy catheter was placed in the renal pelvis over the guide wire (Figure 1).

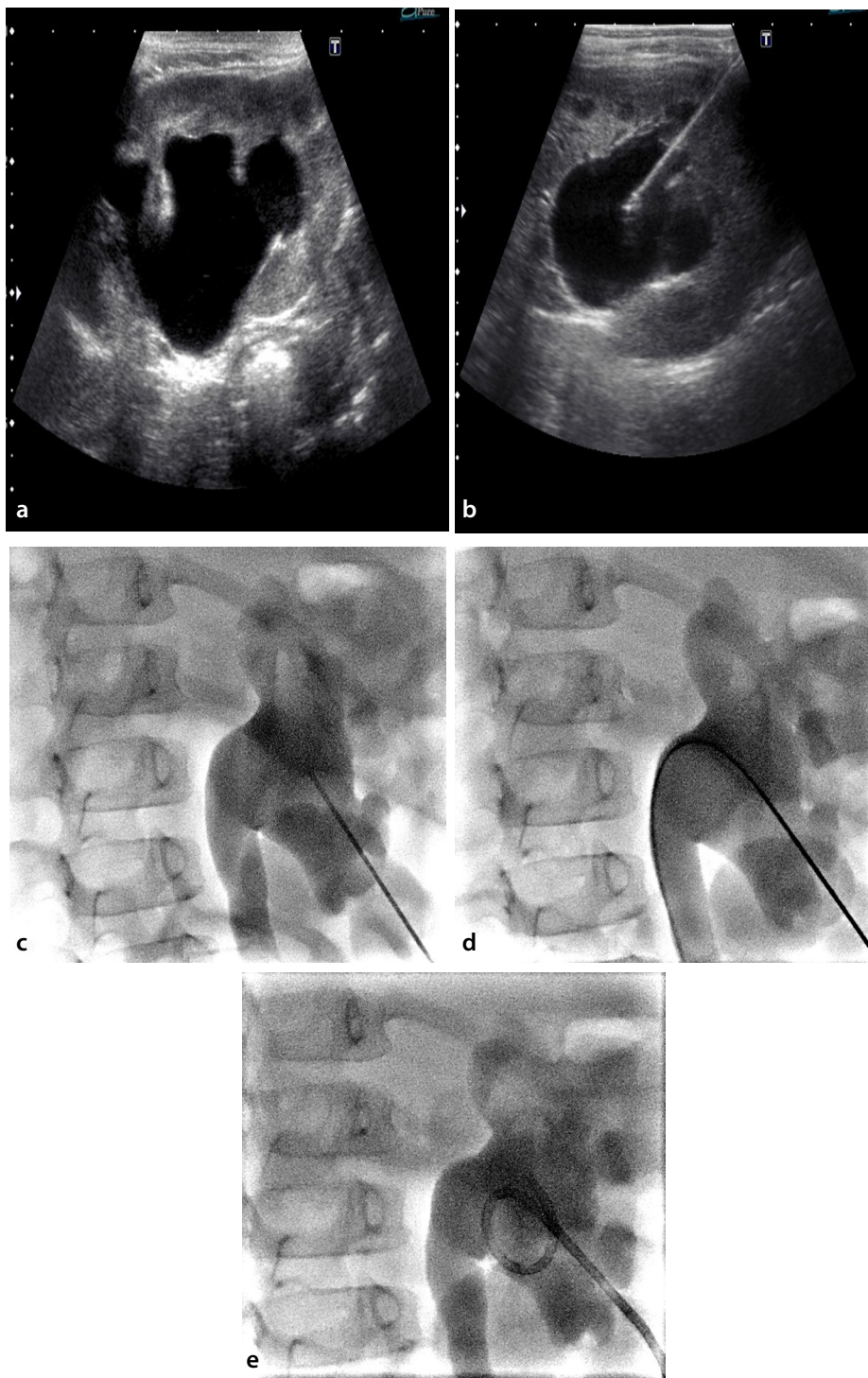
2. In patients with urinary leakage or a mild degree of hydronephrosis, a 21-G needle was used to puncture the calyx. After revealing the pelvicalyceal system under fluoroscopy, a 0.018-inch guide wire was initially introduced through the renal pelvis, and then an introducer set (AccuStick, Boston Scientific) was placed. Finally, a 0.035-inch stiff guide wire was used for tract dilatation and catheter placement (Figure 2). These patients were not given diuretics before the procedure.

The procedure was performed with moderate-to-deep sedation without intubation, under local anesthesia, and under general anesthesia in 60 (80%), 8 (10.7%), and 7 (9.3%) patients, respectively. After the procedure, the patients were taken to the observation room and monitored for 6 hours.

According to the guidelines prepared by the Society of Interventional Radiology,<sup>10</sup> complications that require interventional procedures and hospitalization are classified as major, whereas those that do not require any intervention and are resolved during follow-up are considered minor. In light of this information, we classified the complications

#### Main points

- Percutaneous nephrostomy (PCN) is the method of choice for external urinary diversion in patients with urinary obstruction or extravasation.
- Although PCN is routinely performed in adults in multiple centers worldwide, its applicability in infants is limited.
- The main indication of PCN is urinary obstruction, but this procedure also plays a crucial role in patients with urinary leakage.
- Imaging-guided PCN is a feasible and effective procedure with high technical success and low major complication rates, and it is useful in protecting kidney function in infants.



**Figure 1.** Percutaneous nephrostomy procedure in an 8-month-old girl with severe hydronephrosis caused by ureteropelvic junction obstruction. Sagittal (a) and axial (b) grayscale sonograms demonstrate severe hydronephrosis. The collecting system was punctured with an 18-G needle under ultrasonography guidance. (c-e) Contrast material was injected through the needle (c) to reveal the renal collecting system on fluoroscopy. The nephrostomy catheter was then advanced over the guide wire (d).

that developed in our patients after the procedure as major, minor, and catheter related. Catheter-related complications related to mechanical complications associated with the catheter, such as dislocation, obstruction, leakage, and malposition.

#### Statistical analysis

Statistical analysis was performed using the SPSS for Windows software package (v. 20.0; IBM, Chicago, IL, USA). Categorical variables are presented as numbers and percentages, and continuous variables are presented as average  $\pm$  standard deviation and median

(minimum and maximum) values. The Pearson chi-square test was used for the comparison of categorical variables, and continuous variables were compared using a non-parametric (Kruskal–Wallis) or parametric (One-Way analysis of variance) test according to the suitability of the data for normal distribution based on the evaluation undertaken using the Kolmogorov–Smirnov and Shapiro–Wilk tests. The results of the preprocedural and postprocedural renal function tests were compared using the Wilcoxon signed-rank test. Statistical significance was considered when a *P* value was less than 0.05.

## Results

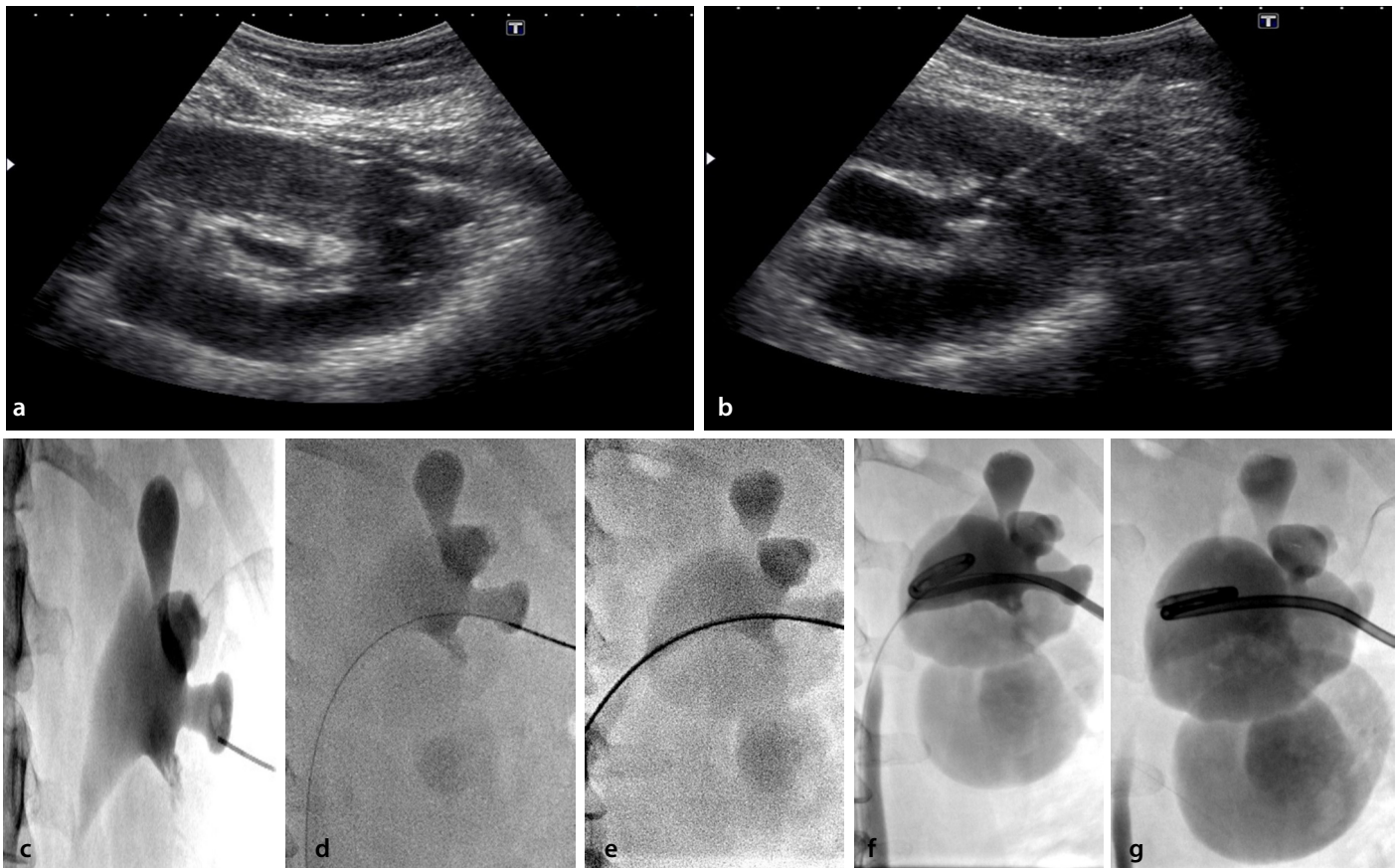
Of the 75 patients enrolled in this study, 50 were male (66.7%) and 25 were female (33.3%), with a mean age of 121 days (range, 1–351 days). Twenty-five (33.3%) of the patients were in the neonatal period. PCN was performed on a total of 86 kidneys, with 11 patients (14.7%) undergoing bilateral nephrostomies. The hydronephrosis grade was 0 in 2 patients, 2 in 15 patients, 3 in 24 patients, and 4 in 34 patients.

Ureteropelvic junction obstruction (UPJO) (54.7%) was the most common indication of PCN, followed by ureterovesical junction obstruction (UVJO) (14.7%), and vesicoureteral reflux (VUR) (10.7%). The remaining indications of PCN are presented in Table 1. The sizes of the inserted catheters ranged from 6 to 8 Fr, with the majority being 6 Fr (77.3%). The median duration of catheterization was 24 days (interquartile range, 10–38; mean, 27.9  $\pm$  45.8; range, 2–345).

There was a significant decrease in serum creatinine and BUN levels following nephrostomy ( $P < 0.001$ ) (Table 2). In the subgroup analysis, renal function recovery was more apparent in patients with UPJO ( $P = 0.001$ ) (Table 3). There was no significant relationship between the BUN and creatinine values and age ( $P = 0.235$  and  $P = 0.345$ , respectively) or the degree of hydronephrosis ( $P = 0.341$  and  $P = 0.557$ , respectively).

Procedure-related major complications were encountered in two patients: methemoglobinemia and respiratory arrest caused by the local anesthetic agent in one patient and the development of urinoma caused by leakage from the puncture site in the other. Percutaneous urinoma drainage was successful in the patient with urinoma. The only minor complication was mild urine leakage in one patient, which was resolved without further intervention.





**Figure 2.** Percutaneous nephrostomy procedure in a 6-month-old boy with mild hydronephrosis caused by vesicoureteral reflux. Sagittal (a) and axial (b) grayscale sonograms demonstrate the mildly dilated renal collecting system. The lower pole calyx was punctured with a 21-G needle under ultrasonography guidance. (c-g) Contrast material was injected to reveal the renal collecting system on fluoroscopy (c). A 0.018-inch guide wire (d) was then introduced and exchanged with a 0.035-inch guide wire (e) using an introducer set. The 0.018-inch guide wire was kept in place to not lose the access route (f). The nephrostomy catheter (g) was advanced over the 0.035-inch guide wire. Finally, the 0.018-inch guide wire was removed following the successful insertion of the catheter.

**Table 1.** Distribution of the nephrostomy etiologies of patients

	n	%
Ureteropelvic junction obstruction	41	54.7
Ureterovesical junction obstruction	11	14.7
Vesicoureteral reflux	8	10.6
Congenital anomaly	5	6.7
Posterior urethral valve	3	4
Iatrogenic stenosis	2	2.7
Urinary leakage	2	2.7
Ureteral stone	1	1.3
Kidney stone	1	1.3
Pyonephrosis	1	1.3
Total	75	100

Catheter-related complications were managed through replacement or revision surgery in 16 patients (21.3%) (Table 4). The mean duration of catheterization was significantly longer in patients who experienced catheter-related complications (mean, 20 days) than in those without such complications (mean, 9 days) ( $P = 0.0035$ ).

Following successful urinary diversion, various surgical interventions were performed to eliminate the underlying disease (Table 5). The most common procedure performed following nephrostomy was pyeloplasty (38.7%). In seven of the patients (9.3%), no further surgical intervention was performed following the removal of the nephrostomy catheter. Of these patients, three

(42.9%) had VUR, three (42.9%) had UPJO, and one (14.2%) had multiple congenital anomalies. Only one patient (1.33%), who had undergone bilateral nephrostomy, required hemodialysis, and kidney failure in this patient was caused by multiple systemic anomalies. Nephrectomy was performed in eight patients (10.7%), of whom five had UPJO and the remaining three each had UVJO, VUR, and pyonephrosis.

There was a statistically significant difference between the preprocedural and postprocedural kidney sizes. The mean renal parenchymal thickness (pre-PCN:  $8.1 \pm 2.7$  vs. post-PCN:  $9 \pm 2.6$  mm;  $P = 0.016$ ) and longitudinal kidney diameter had an inverse correlation ( $56.9 \pm 9.8$  vs.  $51.9 \pm 9.4$  mm,  $P = 0.022$ ).

## Discussion

Our results demonstrate that PCN performed on infants has a technical success rate of 100%. No procedure-related mortality was identified in our study. According to the Society of Interventional Radiology Quality Improvement standards, the technical suc-

cess rate should be above 95% in pediatric PCN and is not affected by the patient's age, degree of hydronephrosis, or presence of renal calculi.<sup>12</sup> Similar to our study, the only study in the literature that included only infant patients reported a technical success rate of 100%.<sup>13</sup> In a multicenter study, technical failure was reported at a rate of 1%, and the loss of access was determined as the cause of technical failure.<sup>14</sup> In a recent study including newborn patients, the only technical failure resulted from multiple punctures that caused the rapid decompression of the obstructed pelvocalyceal system.<sup>7</sup>

PCN can be performed using the Seldinger or trocar method.<sup>15</sup> In our study, PCN was performed using the Seldinger technique with an 18–21-G needle in all patients. Koral et al.<sup>4</sup> used a modified trocar technique in addition to the standard Seldinger technique in newborns and infants. In that study, it was argued that the modified technique might be useful, especially for patients with UPJO.<sup>4</sup> Bas et al.<sup>16</sup> reported a technical success rate of 100% using the trocar technique in 6 neonates and 16 infants with urinary obstruction. The procedures were performed without fluoroscopic guidance; however, the size of the nephrostomy catheter used was 4 Fr.<sup>16</sup> In our study, all the procedures were performed under both ultrasound and fluor-

oscopic guidance; the catheter size ranged from 6 to 8 Fr, with the majority being 6 Fr.

The main indication of PCN is urinary obstruction, but this procedure also plays a crucial role in patients with urinary leakage. There is a lack of data in the literature regarding the utility of PCN in infants with urinary extravasation. In our study, two infants underwent PCN as a result of urinary extravasation. Shellikeri et al.<sup>14</sup> also performed PCN on 34 patients with urinary extravasation, with the major and minor complication rates being determined as 0.1% and 4.4%, respectively. We did not observe any procedure-related complications in either of our patients with urinary leakage.

In our study, the most common indication of PCN was UPJO. In the literature, several studies have also reported UPJO as the most common indication of PCN in infants.<sup>4,5,8,17,18</sup> In long-standing UPJO, the kidney can be visualized as a huge cyst; therefore, it may be difficult to differentiate the calyx from the renal pelvis. The kidney may become apparent following the drainage of the pelvocalyceal system.

Prophylactic antibiotic use is generally recommended before the PCN procedure.<sup>2,5,19</sup> However, Gray et al.<sup>20</sup> reported only one case of infection among 46 patients who

had not received prophylactic antibiotics prior to PCN. Cochran et al.<sup>21</sup> suggested that the risk of sepsis could not be eliminated with prophylactic antibiotic use in patients at higher risk of urinary sepsis (e.g., those with struvite stones, a urinary ostomy, and a positive urine culture test), and Millward<sup>22</sup> recommended prophylactic antibiotic use in patients with urinary stones. In our study, all the patients received third-generation cephalosporin prior to the procedure, with nine patients (12%) already using antibiotics because of bacteriuria identified through urine culture results. We did not observe any cases of urinary sepsis or infection following PCN. A recent study by Ključevšek et al.<sup>7</sup> in the newborn patient group reported that infections developed in 16.1% of the patients after PCN. The reason for the different results reported may be related to urosepsis and pyonephrosis constituting the indications of PCN in a high number of patients in the previous study.

According to the Society of Interventional Radiology Quality Improvement Standards for Percutaneous Nephrostomy in the Pediatric Population, the major complication threshold in PCN is 5% for sepsis, 4% for hemorrhage requiring treatment, and 1% for vascular/bowel injury and pleural complications.<sup>12</sup> We did not observe any procedure-related hematomas that required a blood transfusion or an extended hospital stay. The minor complication threshold is 5% for urinary tract infection, 3% for site infection, 3% for site oozing, and 10% for urine leak.<sup>12</sup> In our study, only one patient (1.3%) developed a urinoma that required percutaneous drainage. Although successful catheterization of the pelvocalyceal system was established, it was not possible to prevent urinary leakage in this patient. This may be because of catheter malfunction or dislodgement, primarily related to changes in patient posi-

**Table 2.** Comparison of the blood urea nitrogen and creatinine values of participants before and after nephrostomy

	Mean ± SD	Median	P*
<b>Creatinine</b>			
Before nephrostomy	1.1 ± 1.4	0.5	<0.001
After nephrostomy	0.7 ± 0.8	0.4	
<b>BUN</b>			
Before nephrostomy	22.6 ± 21.5	14	<0.001
After nephrostomy	15.2 ± 12.3	11.1	

\*Wilcoxon signed-rank test; BUN, blood urea nitrogen; SD, standard deviation.

**Table 3.** Subgroup analysis of blood urea nitrogen and creatinine values according to etiology

	Creatinine before PCN	Creatinine after PCN	P	BUN before PCN	BUN after PCN	P
Ureteropelvic junction obstruction	1.3	0.7	0.001	22.9	15.3	0.001
Ureterovesical junction obstruction	1.4	1.2	0.214	25.3	22.4	0.214
Vesicoureteral reflux	1	0.9	0.145	38.2	28.3	0.087
Congenital anomaly	0.9	0.7	0.174	23.4	20.1	0.098
Posterior urethral valve	1	0.8	0.121	27.3	25.4	0.147
Iatrogenic stenosis	1.4	1.2	0.154	30.5	25.4	0.068
Urinary leakage	0.8	0.7	0.584	14.3	13.4	0.471
Ureteral stone	1	0.9	0.662	18.8	17.4	0.547
Kidney stone	0.9	0.8	0.235	15.1	15.2	0.325
Pyonephrosis	1.4	1.3	0.337	22.8	21.2	0.447

BUN, blood urea nitrogen; PCN, percutaneous nephrostomy.

Table 4. Distribution of complications that developed after nephrostomy		
	Prevalence	%
<b>Major complications (n = 75)</b>		
No major complications	73	97.4
Urinoma	1	1.3
Local anesthesia-related methemoglobinemia	1	1.3
<b>Minor complications (n = 75)</b>		
No minor complications	74	98.7
Urinary extravasation not requiring intervention	1	1.3
<b>Catheter-related complications (n = 75)</b>		
None	59	78.7
Catheter dislocation	8	10.7
Catheter obstruction	3	4
Catheter leakage	3	4
Catheter malposition	2	2.6

Table 5. Procedures performed following nephrostomy		
	n	%
Pyeloplasty	29	38.7
Double-J stent placement	12	16
Ureteroneocystostomy	8	10.7
Nephrectomy	8	10.7
Medical treatment	7	9.3
Posterior urethral valve resection	3	4
Ureterocele excision	2	2.7
Subureteric teflon injection	2	2.7
Percutaneous nephrolithotomy	1	1.3
Pyelolithotomy	1	1.3
Cystostomy	1	1.3
Dialysis	1	1.3
<b>Total</b>	<b>75</b>	<b>100</b>

tion. We observed a significant improvement in serum creatinine and BUN levels following PCN; however, renal function recovery was most significant in patients with UPJO.

We observed methemoglobinemia and respiratory arrest associated with the local anesthetic agent in a 10-day-old newborn. Methemoglobinemia following the administration of local anesthetics is a serious complication for which care should be taken, particularly in neonates and low-weight infants. The use of prilocaine is not recommended in children younger than 6 months (except for transcutaneous administration), pregnant women, patients taking other oxidizing drugs, or those with glucose-6-phosphate dehydrogenase deficiency.<sup>23</sup> The maximum recommended doses of prilocaine are 2.5, 5.0, 3.2, and 1.3 mg/kg for patients older than 6 months, adults, patients with renal insufficiency, and those using other oxidizing drugs, respectively.<sup>23</sup> Methemoglobinemia is

a hemoglobinopathy caused by high methemoglobin levels resulting from the oxidation of iron to the ferric state in hemoglobin, leading to tissue hypoxia. In addition to tissue hypoxia, it may also cause respiratory depression, especially in infants and newborns<sup>24</sup> as in our patient.

Catheter-related complications are not defined clearly enough in the literature and are generally discussed as mechanical complications<sup>14</sup> or minor complications, as in the Society of Interventional Radiology Quality Improvement Standards for Percutaneous Nephrostomy in the Pediatric Population.<sup>12</sup> However, since catheter-related complications are especially common in the infant age group, we examined them in a separate category in our study. These complications are frequently encountered during the follow-up period of patients in the form of catheter occlusion, migration, or dislocation. In the first hours of catheter dislocation, access

to the pelvicalyceal system may remain patent; therefore, the nephrostomy catheter can be placed using the guide wire under fluoroscopy guidance (without a needle).<sup>25</sup> Catheter displacement or dislodgement is more frequently encountered in younger children and infants,<sup>26</sup> and in a recent study, the catheter-related complication rate was reported to be 18.6% in neonates.<sup>7</sup> Shellikeri et al.<sup>14</sup> detected catheter-related mechanical complications in 54 out of 675 patients (8%) and noted that the rate of catheter displacement/dislodgement was higher in infants (10%) than in the non-infant population (6%). In our study, we observed catheter displacement/dislodgement in 25 patients; however, 13 of these patients were under 1 year, and five were neonates. Our results are therefore consistent with those of Shellikeri et al.<sup>14</sup> We observed catheter-related mechanical complications more frequently in neonates (32%) than in the remainder of the patient population (21.3%). Therefore, we suggest that the fixation of the catheter to the skin should be carefully undertaken in neonates.

Results reported in studies conducted in the adult patient group and those reported for the pediatric patient group also reveal some differences. The most common indication of PCN in the adult age group is urinary stone disease, not UPJO.<sup>19</sup> Although a comprehensive study<sup>27</sup> determined the major complication rate as 9.6% and the minor complication rate as 9.9%, these rates vary depending on the location of the urinary obstruction,<sup>28</sup> dilatation status of the collecting system,<sup>29</sup> and the operator performing the procedure.<sup>30</sup> In this context, further studies are required to evaluate these parameters in the pediatric patient group. In studies conducted in the adult patient group, the rate of catheter-related problems varies between 2% and 38%, but it is generally around 7%.<sup>25,31,32</sup> As demonstrated in a recent study by Shah et al.<sup>33</sup>, this may be because the catheters used are designed specifically for adults.

The most important feature that makes our study unique is that it extensively discusses the 20 years of experience of a single center together with clinical and laboratory findings; however, our study also has some limitations. The first concerns the small number of patients and the single-center design, although the results obtained can still serve as a guide for further comprehensive studies. Second, the radiation dose information could not be recorded for all patients for technical reasons. Because of the importance of radiation exposure in this age group, future stud-



ies should evaluate radiation doses in these patients. Finally, because of the retrospective nature of the study, the indications of PCN were heterogeneously distributed, and there were very few patients in some subgroups. To address this, prospective studies should be undertaken.

In conclusion, imaging-guided PCN is a feasible and effective procedure with high technical success and low major complication rates, and it is useful in protecting kidney function in infants.

### Conflict of interest disclosure

The authors declared no conflicts of interest.

## References

1. Dagli M, Ramchandani P. Percutaneous nephrostomy: technical aspects and indications. *Semin Intervent Radiol*. 2011;28(4):424-437. [\[CrossRef\]](#)
2. Farrell TA, Hicks ME. A review of radiologically guided percutaneous nephrostomies in 303 patients. *J Vasc Interv Radiol*. 1997;8(5):769-774. [\[CrossRef\]](#)
3. Trambert JJ. Percutaneous nephrostomy placement in neonates: not simply "miniature adults". *Cardiovasc Intervent Radiol*. 2020;43(9):1329-1330. [\[CrossRef\]](#)
4. Koral K, Saker MC, Morello FP, Rigsby CK, Donaldson JS. Conventional versus modified technique for percutaneous nephrostomy in newborns and young infants. *J Vasc Interv Radiol*. 2003;14(1):113-116. [\[CrossRef\]](#)
5. Hogan MJ, Coley BD, Jayanthi VR, Shiels WE, Koff SA. Percutaneous nephrostomy in children and adolescents: outpatient management. *Radiology*. 2001;218(1):207-210. [\[CrossRef\]](#)
6. Laurin S, Sandström S, Ivarsson H. Percutaneous nephrostomy in infants and children. *Acad Radiol*. 2000;7(7):526-529. [\[CrossRef\]](#)
7. Ključevšek T, Pirnovar V, Ključevšek D. Percutaneous nephrostomy in the neonatal period: indications, complications, and outcome—a single centre experience. *Cardiovasc Intervent Radiol*. 2020;43(9):1323-1328. [\[CrossRef\]](#)
8. Hwang JY, Shin JH, Lee YJ, Yoon HM, Cho YA, Kim KS. Percutaneous nephrostomy placement in infants and young children. *Diagn Interv Imaging*. 2018;99(3):157-162. [\[CrossRef\]](#)
9. Quigley R. Developmental changes in renal function. *Curr Opin Pediatr*. 2012;24(2):184-190. [\[CrossRef\]](#)
10. Sacks D, McClenny TE, Cardella JF, Lewis CA. Society of Interventional Radiology clinical practice guidelines. *J Vasc Interv Radiol*. 2003;14(9 Pt 2):199-202. [\[CrossRef\]](#)
11. Fernbach SK, Maizels M, Conway JJ. Ultrasound grading of hydronephrosis: introduction to the system used by the Society for Fetal Urology. *Pediatr Radiol*. 1993;23(6):478-480. [\[CrossRef\]](#)
12. Cahill AM, Annam A, Baskin KM, et al. Society of Interventional Radiology Quality Improvement Standards for Percutaneous Nephrostomy in the Pediatric Population. *J Vasc Interv Radiol*. 2021;32(1):146-149. [\[CrossRef\]](#)
13. O'Brien WM, Matsumoto AH, Grant EG, Gibbons MD. Percutaneous nephrostomy in infants. *Urology*. 1990;36(3):269-272. [\[CrossRef\]](#)
14. Shellikeri S, Daulton R, Sertic M, et al. Pediatric percutaneous nephrostomy: a multicenter experience. *J Vasc Interv Radiol*. 2018;29(3):328-334. [\[CrossRef\]](#)
15. Hsu L, Li H, Pucheril D, et al. Use of percutaneous nephrostomy and ureteral stenting in management of ureteral obstruction. *World J Nephrol*. 2016;5(2):172-181. [\[CrossRef\]](#)
16. Bas A, Gülşen F, Emre S, et al. Ultrasound-guided percutaneous nephrostomy performed on neonates and infants using a "14-4" (trocar and cannula) technique. *Cardiovasc Intervent Radiol*. 2015;38(6):1617-1620. [\[CrossRef\]](#)
17. Yavascan O, Aksu N, Erdogan H, et al. Percutaneous nephrostomy in children: diagnostic and therapeutic importance. *Pediatr Nephrol*. 2005;20(6):768-772. [\[CrossRef\]](#)
18. Stanley P, Bear JW, Reid BS. Percutaneous nephrostomy in infants and children. *AJR Am J Roentgenol*. 1983;141(3):473-477. [\[CrossRef\]](#)
19. Hausegger KA, Portugaller HR. Percutaneous nephrostomy and antegrade ureteral stenting: technique-indications-complications. *Eur Radiol*. 2006;16(9):2016-2030. [\[CrossRef\]](#)
20. Gray RR, So CB, McLoughlin RF, Pugash RA, Saliken JC, Macklin NI. Outpatient percutaneous nephrostomy. *Radiology*. 1996;198(1):85-88. [\[CrossRef\]](#)
21. Cochran ST, Barbaric ZL, Lee JJ, Kashfian P. Percutaneous nephrostomy tube placement: an outpatient procedure? *Radiology*. 1991;179(3):843-847. [\[CrossRef\]](#)
22. Millward SF. Percutaneous nephrostomy: a practical approach. *J Vasc Interv Radiol*. 2000;11(8):955-964. [\[CrossRef\]](#)
23. Guay J. Methemoglobinemia related to local anesthetics: a summary of 242 episodes. *Anesth Analg*. 2009;108(3):837-845. [\[CrossRef\]](#)
24. Iolascon A, Bianchi P, Andolfo I, et al. Recommendations for diagnosis and treatment of methemoglobinemia. *Am J Hematol*. 2021;96(12):1666-1678. [\[CrossRef\]](#)
25. Wah TM, Weston MJ, Irving HC. Percutaneous nephrostomy insertion: outcome data from a prospective multi-operator study at a UK training centre. *Clin Radiol*. 2004;59(3):255-261. [\[CrossRef\]](#)
26. Riedy MJ, Lebowitz RL. Percutaneous studies of the upper urinary tract in children, with special emphasis on infants. *Radiology*. 1986;160(1):231-235. [\[CrossRef\]](#)
27. Degirmenci T, Gunlusoy B, Kozacioglu Z, et al. Utilization of a modified Clavien Classification System in reporting complications after ultrasound-guided percutaneous nephrostomy tube placement: comparison to standard Society of Interventional Radiology practice guidelines. *Urology*. 2013;81(6):1161-1167. [\[CrossRef\]](#)
28. Kumar S, Dutt UK, Singh S, et al. Prospective audit of complications after ultrasonography-guided percutaneous nephrostomy for upper urinary tract obstruction using modified Clavien classification system. *Urol Ann*. 2020;12(1):31-36. [\[CrossRef\]](#)
29. Ho Won J, Jin Yang W, Hoon Shin J, et al. Percutaneous nephrostomy for nondilated renal collecting system with ultrasound and fluoroscopic guidance: the results of a 10-year experience. *Diagn Interv Radiol*. 2022;28(3):244-248. [\[CrossRef\]](#)
30. Yonguc T, Bozkurt İH, Değirmenci T, et al. Urologist directed percutaneous nephrostomy tube placement: 6 years experience. *J Clin Anal Med*. 2015;5(1):213-218. [\[CrossRef\]](#)
31. Kaskarelis IS, Papadaki MG, Malliaraki NE, Robotis ED, Malagari KS, Piperopoulos PN. Complications of percutaneous nephrostomy, percutaneous insertion of ureteral endoprosthesis, and replacement procedures. *Cardiovasc Intervent Radiol*. 2001;24(4):224-228. [\[CrossRef\]](#)
32. Montvilas P, Solvig J, Johansen TE. Single-centre review of radiologically guided percutaneous nephrostomy using "mixed" technique: success and complication rates. *Eur J Radiol*. 2011;80(2):553-558. [\[CrossRef\]](#)
33. Shah R, Minhas K, Patel PA. Is There really no kit for kids? Quantification of manufacturer recommendations regarding paediatric use for high-volume IR devices. *Cardiovasc Intervent Radiol*. 2023;46:1046-1052. [\[CrossRef\]](#)