



# Use of gelatin sponge to seal the biliary tract after percutaneous transhepatic biliary drainage in patients with liver transplants

Ali Özgen

Bahçeşehir University Faculty of Medicine, İstanbul, Türkiye

## ABSTRACT

Percutaneous transhepatic biliary drainage (PTBD) is commonly used in the treatment of malign and benign biliary pathologies. Certain complications after PTBD may occur, such as biliary fistula, biliary leakage, bilioma, and hematoma. The purpose of this study was to evaluate the safety and effectiveness of using a sterile gelatin sponge to seal the biliary tract after PTBD in patients with liver transplants to prevent complications. A total of 131 biliary drainages were introduced in 97 patients, and a sterile gelatin sponge was used to seal the biliary tract after removal of the biliary drainage catheter. The patients were immediately examined for complications using ultrasound and then followed up clinically unless imaging was required. Five fluid collections within the liver with a diameter <2 cm, consistent with hematoma or bilioma, were resolved spontaneously. No hematoma or bilioma required treatment, and no biliary leakage or fistula was detected. No complications related to the use of the sponge were observed. The use of a sterile gelatin sponge is a safe and effective method for sealing the biliary tract to prevent complications after PTBD in patients with liver transplants.

## KEYWORDS

Biliary tract, catheter, fistula, liver, transplantation

Percutaneous transhepatic biliary drainage (PTBD) is commonly used in the treatment of malign and benign biliary pathologies. Although considered rare and with an unknown probability, complications after PTBD may occur in daily practice, such as biliary fistula, biliary leakage, bilioma, and hematoma. Many interventional and surgical treatment approaches can be used when such complications are observed.<sup>1-8</sup> In daily practice, materials such as coils, liquid embolics, and vascular plugs may be used to close the biliary tract. One study demonstrated the efficacy of using a gelatin sponge to close the tract in patients with biliary drainage caused by benign or malignant diseases using a slightly different technique.<sup>9</sup> The aim of the present study was to evaluate the safety and effectiveness of using sterile gelatin sponge to seal the biliary tract after PTBD in patients with liver transplants to prevent possible complications.

## Technique

Institutional review board approval was obtained for this retrospective study, and the requirement to obtain written informed consent was waived. We included adult patients with living-donor liver transplants with long-term internal PTBD performed in two liver transplant centers. The indication for biliary drainage was anastomotic and/or non-anastomotic biliary strictures unresponsive to or not suitable for endoscopic interventions. The study involved 97 adult patients, 61 male and 36 female, requiring a total of 131 biliary drainages (30 patients with two and two patients with three biliary drainages). The catheterization time was between two and 19 weeks, with a mean of 13 weeks.

All patients were heavily sedated or placed under general anesthesia. Proper antibiotic prophylaxis was administered to all patients. All PTBDs were performed by the same interven-

Corresponding author: Ali Özgen

E-mail: draliozgen@hotmail.com

Received 03 June 2023; revision requested 28 June 2023; accepted 26 July 2023.



Epub: 31.08.2023

Publication date: 09.09.2024

DOI: 10.4274/dir.2023.232344

You may cite this article as: Özgen A. Use of gelatin sponge to seal the biliary tract after percutaneous transhepatic biliary drainage in patients with liver transplants. *Diagn Interv Radiol.* 2024;30(5):325-327.

tional radiologist, with more than 15 years' experience in hepatobiliary procedures. A 14F multipurpose drainage catheter (Cook Medical, Bloomington, IN, USA) was used in four patients with a single drainage catheter, and a 12F SKATER catheter (Argon Medical Devices, Dallas, TX, USA) was used for the rest of the patients with single drainage catheters. A 10F SKATER catheter was used for the patients who required two or three drainage catheters. This procedure was not performed in patients with skin infections near the catheter insertion site.

The catheters were flushed with saline, and a contrast medium was injected into the catheter to examine the biliary system. Amplatz stiff guidewire (Boston Scientific, Marlborough, MA, USA) was introduced into the biliary drainage catheter, and then the catheter was removed over the wire. An 11F Radifocus Introducer II sheath (Terumo Corporation, Shibuya-ku, Tokyo, Japan) for 12F and 14F catheters and 10F sheath for 10F catheters were immediately placed over the wire. Cholangiography was then performed through the sheath to fully evaluate the biliary system (Figure 1a). If and when biliary drainage was considered successful, a commercially available sterile gelatin sponge was used to seal the biliary tract.

A piece of sponge (7 x 1 x 1 cm) was cut. It was then squeezed by hand and formed into a 7-cm-long cylinder with a diameter of approximately 3 mm, similar to that described in a previous study.<sup>9</sup> The tip of the sheath was pulled back into the liver parenchyma under fluoroscopic guidance. The length of the sponge was adjusted to approximately equal the distance between the tip of the sheath and the liver capsule. The tip of the dilator was cut so that the sponge could be pushed without being punctured, and the head of the sheath was then cut-off and the sponge placed inside the sheath. Under fluoroscopic guidance and using the dilator, the sponge was pushed until it reached the tip of the

sheath (Figure 1b). If the sponge softened following long contact with bile, the procedure was repeated using a new sponge. The sheath was removed while the sponge was placed using the dilator (Figure 1c). If the patient had more than one catheter, the procedure was repeated for each catheter. The skin was cleansed and then covered using a sterile pad. Routine ultrasound examination was performed before the patient left (Figure 1d). The patients were then followed up clinically, and imaging was performed only if indicated for any other reason (Figure 2).

## Results

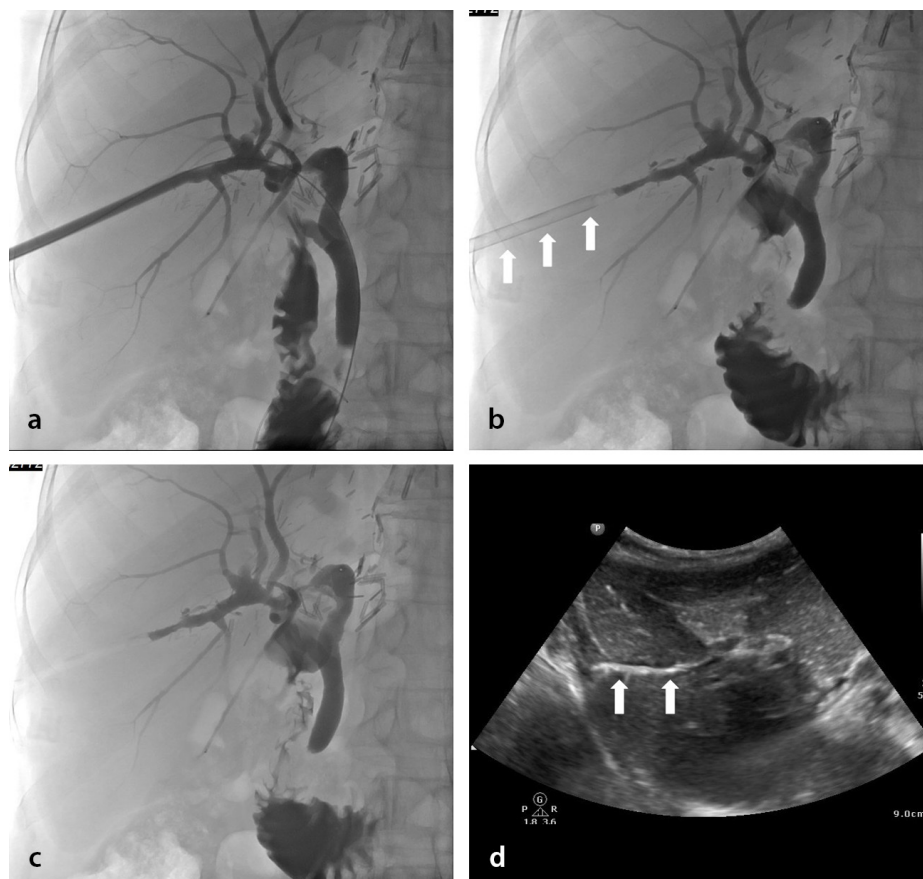
All the biliary tracts were sealed successfully using this technique. There were five local fluid collections with a diameter <2 cm near the tract in the liver consistent with bilioma or hematoma, discovered using the first ultrasound; however, no treatment was indicated. They were followed up using ultrasound and were all resolved spontaneously. No other complications, such as biliary fistula, bile leakage, or hematoma, were ob-

served. No complications related to the use of the sponge were observed.

## Discussion

This study demonstrates that using a sterile gelatin sponge after PTBD may be a safe and effective method for preventing possible complications. Using sterile gelatin sponges is also cost-effective because they are relatively cheap and widely available. The implementation of this technique is also simple and takes only a couple of minutes. To our knowledge, this is the first study to present a specific technique to prevent complications after PTBD.

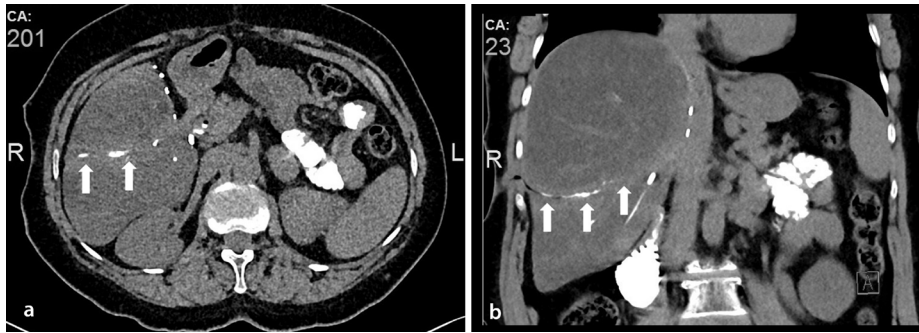
Spongostan is a sterile water-insoluble, absorbable, porcine gelatin used to maintain local hemostasis. These gelatin sponges have been used in surgical operations for decades. They have also been successfully used to close biliary tracts in patients with various benign and malignant disorders that require biliary drainage<sup>9</sup> and to occlude vessels and seal tracts in various situations. We also successfully occluded a biliary cutaneous fistula



**Figure 1.** (a-d) Fifty seven-year-old patient with a liver transplant and long-term PTBD. (a) Cholangiography through the sheath after removal of the catheter revealing filling of the intrahepatic biliary tree and passage of contrast medium through the duodenum. (b) The sheath was pulled into the liver parenchyma and the sponge inserted (arrows). (c) The sheath was removed while the sponge was placed. (d) Ultrasound showing the sponge within the liver parenchyma (arrows). PTBD, percutaneous transhepatic biliary drainage.

### Main points

- Complications after percutaneous transhepatic biliary drainage (PTBD) procedures may occur.
- Many interventional and surgical treatment approaches may be used when such complications are observed.
- Using a gelatin sponge to seal the biliary tract after removal of the PTBD catheter may help prevent some of these possible complications.



**Figure 2.** (a, b) Forty-eight-year-old patient with a liver transplant after the removal of a long-term PTBD catheter. Non-enhanced computed tomography immediately after removal of the catheter: (a) axial and (b) coronal reformatted images showing a gelatin sponge with contrast medium within the biliary tract (arrows). PTBD, percutaneous transhepatic biliary drainage.

that developed after prolonged biliary drainage in two patients using this material. In fact, we developed the concept of routinely closing the biliary tract after successfully occluding the tract of a patient with a biliary cutaneous fistula following the failure of glue and coil closure attempts at another center. The rationale behind sealing the tract with an absorbable sponge is to give the liver time to expand and then fill the tract naturally.

This study has some limitations. First, this was a retrospective study with no control group. Second, given the rarity of such complications, the number of patients was relatively limited. Third, although post-procedure imaging follow-up is not included in our routine practice, we did not perform any specific imaging follow-up other than ultrasound after the use of this material.

In conclusion, use of a sterile gelatin sponge to seal the biliary tract after PTBD may be a safe and effective method for preventing possible complications in patients

with liver transplants. This technique might also potentially be used for other patients with PTBD. Further comparative studies with a larger number of patients are necessary to confirm our findings.

#### Conflict of interest disclosure

The author declared no conflicts of interest.

#### References

1. Giurazza F, Ierardi A, Spinazzola A, et al. Percutaneous embolization of biliary leaks: initial experience with extravascular application of a PTFE-covered microplug. *Cardiovasc Intervent Radiol.* 2023;46(3):400-405. [\[Crossref\]](#)
2. Ierardi AM, Fontana F, Mangini M et al. Use of amplatzer vascular plug to treat a biliary cutaneous fistula. *Korean J Radiol.* 2013;14(5):801-804. [\[Crossref\]](#)
3. Al-Qahtani HH. Biliopleural fistula with cholethorax. A rare complication of

percutaneous transhepatic biliary drainage. *Saudi Med J.* 2011;32(11):1189-1192.

[\[Crossref\]](#)

4. Çakır MS, Guzelbey T, Kinacı E, Sevinc MM, Kilickesmez O. Delayed bilhemia complicating percutaneous transhepatic biliary drainage: successful treatment with primary coil embolization. *Radiol Case Rep.* 2018;14(2):269-272. [\[Crossref\]](#)
5. Eicher CA, Adelson AB, Himmelberg JA, Chintalapudi U. Laser ablation of a biliary duct for treatment of a persistent biliary-cutaneous fistula. *J Vasc Interv Radiol.* 2008;19(2):294-297. [\[Crossref\]](#)
6. Yu EYY, Yang FS, Chiu YJ, Tsai FJ, Lu CC, Yang JS. Late onset of biliopleural fistula following percutaneous transhepatic biliary drainage: a case report. *Biomedicine (Taipei).* 2018;8(1):6. [\[Crossref\]](#)
7. Li H, Ge N, He C, et al. Portal vein embolization in the treatment of portal vein bleeding after percutaneous transhepatic biliary drainage: a case report and literature review. *J Interv Med.* 2022;16(4):217-220. [\[Crossref\]](#)
8. Chanyaputhipong J, Lo RHG, Tan BS, Chow PKH. Portobiliary fistula: successful transcatheter treatment with embolisation coils. *Singapore Med J.* 2014;55(3):34-36. [\[Crossref\]](#)
9. Augustin AM, Cao V, Fluck F, Kunz J, Bley T, Kickuth T. Percutaneous transhepatic biliary tract embolization using gelatin sponge. *Acta Radiol.* 2019;60(10):1194-1199. [\[Crossref\]](#)