



# Quadratus lumborum block for procedural and postprocedural analgesia in renal cell carcinoma percutaneous cryoablation

Saman Fouladirad<sup>1</sup>  
 Jasper Yoo<sup>2</sup>  
 Behrang Homayoon<sup>2,3,4,5</sup>  
 Jun Wang<sup>2,3,4,5</sup>  
 Pedro Lourenço<sup>2,3,4,5</sup>

<sup>1</sup>University of Saskatchewan, Faculty of Medicine, Saskatoon, Canada

<sup>2</sup>University of British Columbia, Faculty of Medicine, Vancouver, Canada

<sup>3</sup>University of British Columbia, Department of Radiology, Vancouver, Canada

<sup>4</sup>Surrey Memorial Hospital, Surrey, Canada

<sup>5</sup>Jim Pattison Outpatient Care and Surgery Centre, Surrey, Canada

## ABSTRACT

This study assesses the efficacy of the quadratus lumborum block (QLB) in the management of procedural and peri-procedural pain associated with small renal mass cryoablation. To the best of our knowledge, this is the first study that examines the use of QLB for pain management during percutaneous cryoablation of renal cell carcinoma (RCC). A single-center retrospective review was conducted for patients who underwent cryoablation for RCC with QLB between October 2020 and October 2021. The primary study endpoint included a total dose of procedural conscious sedation and administered, postprocedural analgesia. Technical success in cryoablation was achieved in every case. No patients required additional analgesic during or after the procedure, and no complications resulted from the use of the QLB. The QLB procedure appears to be an effective locoregional block for the management of procedural and peri-procedural pain associated with renal mass cryoablation.

## KEYWORDS

Ablation, analgesic, anesthesia, anesthetics, cancer, carcinoma, cryoablation, kidney, local anesthesia, local anesthetic, malignancy, minimally invasive, oncology, quadratus lumborum block, renal, renal cell carcinoma, small renal mass, tumoral

Renal cell carcinoma (RCC) is the most common type of kidney cancer. Laparoscopic or percutaneous energy ablative therapies have become an accepted treatment for small (T1) tumors (<3.5 cm) and have outcomes similar to those of partial/radical nephrectomy in the treatment of such tumors, with lower morbidity and greater preservation of renal function. They can also be performed on an outpatient basis without general anesthesia (GA). Percutaneous renal cryoablation (PRC) reduces complications and recovery time compared with more invasive procedures, such as open/laparoscopic partial nephrectomy.<sup>1-3</sup> The quadratus lumborum block (QLB), first described in 2007, is a more recent procedure.<sup>4,5</sup> The aim of this paper is to explore QLB's potential for procedural and postprocedural pain management in PRC for RCC.

## Methods

This was a single-center retrospective study. Application for ethical approval was waived as outlined by the institutional ethical review board. Informed consent was obtained from all patients in this study.

## Patients

The data of patients who received QLB for the cryoablation of small renal masses between October 2020 and October 2021 were included in this study. The inclusion criteria were as follows: patients aged >18 y and <100 y; those with a tumor size ≤5 cm; those with a single renal tumor; and/or those with a primary renal tumor without extrarenal or vascular invasion. The exclusion criteria were as follows: those with a hypersensitivity to local anesthesia and/or those with a soft-tissue infection overlaying the needle placement site. Demographics and

Corresponding author: Pedro Lourenço

E-mail: pedro.lourenco@fraserhealth.ca

Received 09 January 2024; revision requested 10 February 2024; last revision received 26 March 2024; accepted 06 April 2024.



Epub: 02.09.2024

Publication date: xx.xx.2024

DOI: 10.4274/dir.2024.232100

**Table 1.** Patient demographic details, tumor descriptors, procedural information, and outcomes for three patients administered anesthetics for percutaneous cryoablation of small renal masses

		Patient		
		1	2	3
<b>Demographic</b>	Age (y)	73	80	79
	Gender	F	M	M
<b>Tumor description</b>	Size (cm)	2.7 × 2.4 × 2.0	3.6 × 3.1 × 3.1	2.2 × 1.8 × 2.4
	Side	L	L	L
	Location	Lower pole	Upper pole	Mid-upper pole
	Growth	Exophytic	Exophytic	Exophytic
	RCC subtype	Clear cell	Papillary	Clear cell
<b>Procedure</b>	Technique	Cryoablation	Cryoablation	Cryoablation
	Block used	Left QLB	Left QLB	Left QLB
	Success status	Technical success	Technical success	Technical success
<b>Complications</b>	Minor	0	0	0
	Major	0	0	0
<b>Disposition</b>	Length of stay (h)	4	4	4
	Follow-up	CT @ 3 mon	MRI @ 3 mon	CT @ 3 mon

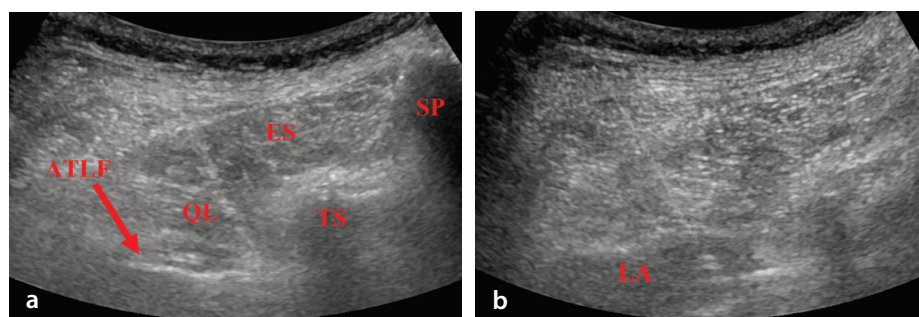
F, female; M, male; RCC, renal cell carcinoma; QLB, quadratus lumborum block; CT, computed tomography; MRI, magnetic resonance imaging.

tumor characteristics, including pathology, size, and location, were recorded (Table 1). Any complications related to the procedure were noted according to the modified Clavien–Dindo system.<sup>6</sup> Patients were referred to and assessed for PRC via interventional radiology.

## Technique

PRC with QLB was performed by a single, fellowship-trained, interventional radiologist at Surrey Memorial Hospital in Surrey, British Columbia, Canada.

A QLB comprised of 20 mL of 0.5% bupivacaine solution was used for preprocedural regional block pain management. Additionally, for the management of procedural anxiety, 50 mcg of fentanyl and 1 mg of midazolam were administered intravenously to achieve conscious sedation (CS) upon each patient’s arrival in the computed tomography (CT) ab-



**Figure 1.** Anterior QLB approach. (a) A horizontally oriented, curvilinear probe is used to identify the ES and QL muscles ipsilateral to the treatment side. (b) A 21 g Chiba needle is advanced from posterior to anterior via the ES and QL muscle to instill 20 mL of 0.5% bupivacaine solution in the ATLF, resulting in an expected distention of the ATLF. QLB, quadratus lumborum block; ES, erector spinae; QL, quadratus lumborum muscle; SP, spinous process; TS, transverse process; ATLF, anterior thoracolumbar fascia; LA, local anesthetic.

lation suite. An additional 50 mcg of fentanyl and 1 mg of midazolam were administered as needed for either preprocedural anxiety/stress, intra-procedural pain management, or postprocedural pain management. The primary outcome measured for this study was the success of QLB in the management of procedural and postprocedural pain, determined based on the need for further analgesic (in addition to the standard analgesic administered) to control patients’ pain (Table 2).

An anterior QLB approach under ultrasound was used for all cases (Figure 1). Patients were placed in a lateral decubitus or prone position and monitored by pulse oximeter, non-invasive blood pressure monitoring, and electrocardiogram. A linear transducer was placed in the axial plane in the midaxillary line and moved posteriorly until the lateral interfascial triangle (LIFT) (i.e., the fascia that surrounds the paraspinal muscles)

became visible between the latissimus dorsi and the quadratus lumborum. A needle was then introduced at the lateral end of the transducer and advanced until it was in the middle layer of the thoracolumbar fascia (i.e., the fascia that separates the quadratus lumborum from the latissimus dorsi and paraspinous muscle) close to the triangular structure of the LIFT. The local anesthetic was then injected intrafascially.

Cryoablation was performed under CT guidance (GE Revolution CT, Waukesha, WI, United States of America) and ultrasound (GE LOGIQ E10, Waukesha, WI, United States of America). Prior to ablation, single, portal venous phase, contrast-enhanced CT was conducted to better outline the lesion of interest. A variable number of cryoprobes were placed with 1–2 cm of spacing depending on the size and morphology of lesions, with single/multiple scans conducted for

### Main points

- This is the first study to successfully employ the use of the quadratus lumborum block (QLB) during percutaneous renal cryoablation (PRC) for renal cell carcinoma (RCC).
- Hospital stays with QLB were reduced compared with prior studies that used the typical analgesic options of local anaesthetic and conscious sedation or general anaesthetic. This could transform PRC for RCC into an outpatient procedure instead of requiring overnight hospitalization.
- In this study, usage of QLB during PRC for RCC allowed for decreased demand for analgesics or sedation.

**Table 2.** Type and dosage of anesthetic used based on stage of procedure

	Anesthetic	Patient		
		1	2	3
Preprocedural sedation	Bupivacaine	20 mL of 0.25%	20 mL of 0.25%	20 mL of 0.25%
	Fentanyl (mcg)	50	50	100
	Midazolam (mg)	1	1	2
Intraprocedural sedation	None	N/A	N/A	N/A
Postprocedural analgesia	None	N/A	N/A	N/A

appropriate probe positioning. The double freeze–thaw protocol-consisting of cycles that involve a double freezing cycle of 10 min separated by a passive (9 min) and active (1 min) thaw session-was conducted. Unenhanced CT images at 5 and 10 min were captured to monitor ice ball growth and identify any vulnerable structures. More probes were used as needed if the ice ball did not fully cover the tumors. Following the ablation, further non-contrast CT was performed following probe removal to assess for any complications.

## Results

### Demographics and tumor characteristics

Three patients (n = 3) with an average age of  $77.33 \pm 2.19$  y underwent cryoablation with QLB for small renal masses between October 2020 and October 2021 in this study. The mean volume of the tumors was  $19.02 \pm 7.85$  cm<sup>3</sup>, and all three were located in the left kidney. Patients had prior biopsies completed with pathology consistent with RCC-two with clear cell subtypes and one with papillary subtypes.

### Procedure and complications

Technical success with no major complications was achieved in all cases. One patient returned to the emergency department within 24 hours with postprocedural hematuria but required no additional intervention. No patient exhibited QLB-associated complications.

### Anesthesia

On average,  $66.67 \pm 16.67$  mcg of fentanyl and  $1.33 \pm 0.33$  mg of midazolam were used to manage procedural anxiety prior to the QLB of 20 mL of bupivacaine solution. Two patients required only the standard 50 mcg of fentanyl and 1 mg of midazolam before the procedure, whereas one patient needed additional dosing for preprocedural anxiety and stress. No additional analgesics were needed during the cryoablation or during the 4 h postprocedural recovery period. Although no specific survey measurements were used to assess pain severity, patient

reporting was used as an indicator of pain management, and no patients reported discomfort or pain-related symptoms.

## Discussion

With the increasing demand for regional anesthesia, QLB may reduce the need for CS and GA in the ablation of small renal masses. To the best of our knowledge, this is the first paper to evaluate the potential of QLB for pain management during percutaneous cryoablation in RCC. The QLB procedure used in our study consisted of a single administration of a small amount of bupivacaine solution prior to the placement of the cryoablation probe. Our patients received small loading doses of CS for preprocedural anxiety and did not receive additional intraprocedural or postprocedural doses. Other studies of PRC have used local anesthesia and CS induction; however, in our study, no patient reported postprocedural pain or discomfort, nor did any require intraprocedural CS titration, suggesting that the QLB procedure was effective. None of the participants in the current study who received QLB with CS required a conversion to GA for analgesia or experienced any QLB-related complications. In addition, the use of QLB allowed for reduced CS (fentanyl and midazolam) dosing.<sup>7,8</sup> Complete procedural success with QLB was achieved in all three cases, and the average length of stay following cryoablation with QLB was approximately 4 h, which is shorter than previous studies using local anesthesia and CS.<sup>8</sup> Thus, QLB may allow interventional radiologists to perform PRC on an outpatient basis instead of requiring an overnight hospital stay. The QLB procedure may be valuable in patients with contraindications to CS and/or comorbidities that make them poor surgical candidates. Thus, QLB is attractive as a safe, well-tolerated locoregional approach to anesthesia for PRC in RCC.

The limitations of this study include its small sample size and the lack of a comparison group to make a direct, objective comparison between different analgesics. Future studies are needed to confirm the benefit of QLB in PRC of T1 RCC.

### Conflict of interest disclosure

The authors declared no conflicts of interest.

## References

- Chan VW, Abul A, Osman FH, et al. Ablative therapies versus partial nephrectomy for small renal masses - A systematic review and meta-analysis. *Int J Surg.* 2022;97:106194. [\[CrossRef\]](#)
- Klatte T, Shariat SF, Remzi M. Systematic review and meta-analysis of perioperative and oncologic outcomes of laparoscopic cryoablation versus laparoscopic partial nephrectomy for the treatment of small renal tumours. *J Urol.* 2014;191(5):1209-1217. [\[CrossRef\]](#)
- Kunkle DA, Uzzo RG. Cryoablation or radiofrequency ablation of the small renal mass: a meta-analysis. *Cancer.* 2008;113(10):2671-2680. [\[CrossRef\]](#)
- Krohg A, Ullensvang K, Rosseland LA, Langesæter E, Sauter AR. The analgesic effect of ultrasound-guided quadratus lumborum block after cesarean delivery: a randomized clinical trial. *Anesth Analg.* 2018;126(2):559-565. [\[CrossRef\]](#)
- Ishio J, Komazawa N, Kido H, Minami T. Evaluation of ultrasound-guided posterior quadratus lumborum block for postoperative analgesia after laparoscopic gynecologic surgery. *J Clin Anesth.* 2017;41:1-4. [\[CrossRef\]](#)
- Dindo D, Demartines N, Clavien PA. Classification of surgical complications: a new proposal with evaluation in a cohort of 6336 patients and results of a survey. *Ann Surg.* 2004;240(2):205-213. [\[CrossRef\]](#)
- Allaf ME, Varkarakis IM, Bhayani SB, Inagaki T, Kavoussi LR, Solomon SB. Pain control requirements for percutaneous ablation of renal tumors: cryoablation versus radiofrequency ablation--initial observations. *Radiology.* 2005;237(1):366-370. [\[CrossRef\]](#)
- Okhunov Z, Juncal S, Ordon M, et al. Comparison of outcomes in patients undergoing percutaneous renal cryoablation with sedation vs general anesthesia. *Urology.* 2015;85(1):130-134. [\[CrossRef\]](#)