



Diagnostic value of qualitative and quantitative enhancement parameters on contrast-enhanced mammography

Musa Kul¹
 Selçuk Akkaya²
 Sibel Kul²

¹University of Health Sciences, Trabzon Faculty of Medicine, Kanuni Health Research Center, Department of Radiology, Trabzon, Türkiye

²Karadeniz Technical University, Faculty of Medicine, Department of Radiology, Trabzon, Türkiye

PURPOSE

To determine whether qualitative and quantitative enhancement parameters obtained from contrast-enhanced mammography (CEM) can be used in predicting malignancy.

METHODS

After review board approval, consecutive 136 suspicious lesions with definite diagnosis were retrospectively analyzed on CEM. Acquisition was routinely started with craniocaudal view and ended with mediolateral oblique view of the affected breast. Lesion conspicuity (low, moderate, high), internal enhancement pattern (homogeneous, heterogeneous, rim), contrast-to-noise ratio (CNR), percentage of signal difference (PSD) and relative enhancement from early to late view were analyzed. PSD and relative enhancements were used to determine patterns of descending, steady or ascending enhancements. Receiver operating characteristic analysis, Cohen's kappa statistics and Spearman correlation tests were used.

RESULTS

There were 29 benign and 107 malignant lesions. 64% of the malignant lesions exhibited high conspicuity compared to 14% of the benign lesions ($P < 0.001$). CNR values were higher in malignant lesions compared to benign ones ($P \leq 0.004$). CNR from early view yielded 82% sensitivity, 72% specificity and PSD yielded 79% sensitivity, 65% specificity. Descending pattern and rim enhancement observed in 44% and 21% of breast cancers, respectively, and both provided 96% positive predictive value for malignancy.

CONCLUSION

Diagnostic accuracy of quantitative parameters was higher than that of qualitative parameters. High CNR, rim enhancement, and descending pattern were features commonly seen in malignant lesions, while low CNR, homogeneous enhancement, and ascending pattern were commonly seen in benign lesions.

KEYWORDS

BI-RADS, breast cancer, contrast-enhanced mammography, enhancement parameters, pharmacokinetics

Corresponding author: Sibel Kul

E-mail: sibel_ozy@yahoo.com

Received 27 September 2023; revision requested 13 November 2023; last revision received 05 February 2024; accepted 18 March 2024.



Epub: 15.04.2024

Publication date: 08.07.2024

DOI: 10.4274/dir.2024.232472

Contrast-enhanced mammography (CEM) is a recently developed advanced digital mammography (DM) technique that uses low- and high-energy acquisitions following the administration of an intravenous iodine contrast agent. Low-energy and recombined images are finally obtained for each of the craniocaudal (CC) and mediolateral oblique (MLO) projections involved.^{1,2} The low-energy images are similar and comparable to those of conventional DM.^{3,4} Recombined images demonstrate the iodine uptake of breast lesions secondary to angiogenesis on a suppressed background of normal fibroglandular tissue. The physiological and morphological information obtained from CEM is thus similar to that yielded by dynamic contrast-enhanced magnetic resonance imaging (DCE-MRI). CEM combines the relative simplicity and low cost of mammography with the high sensitivity of contrast-enhanced imaging. The technique dramatically improves the ability of DM in the detection and characterization of breast lesions.^{5,6}

You may cite this article as: Kul M, Akkaya S, Kul S. Diagnostic value of qualitative and quantitative enhancement parameters on contrast-enhanced mammography. *Diagn Interv Radiol.* 2024;30(4):248-255.

In CEM, low-energy and recombined images are reviewed, and morphological parameters, together with the presence of enhancement, are used for lesion characterization.⁷ Since both benign and malignant lesions may exhibit enhancement, it may not be possible to differentiate them solely through enhancement.^{1,2,6} Therefore, routinely evaluated parameters of enhancement intensity, pattern, and kinetics used in the diagnosis, molecular subtyping, and prognostication of breast cancer in DCE-MRI⁸⁻¹¹ have recently become the subject of CEM research.¹²⁻¹⁸ This retrospective study aims to determine whether qualitative and quantitative enhancement parameters obtained from CEM could be used for predicting malignancy.

Methods

Patient population

This retrospective study was approved by the KTU Medical Faculty SCI Research Ethics Committee Ethics Committee (date: 12.04.2019, decision no: 24237859-295), with informed consent being waived. Consecutive cases that had undergone CEM between June 2014 and February 2022 in our hospital were retrospectively reviewed. In our practice, we offer CEM instead of DM to diagnose patients with complaints of a palpable mass and spontaneous nipple discharge or nipple retraction if our targeted fast ultrasound (US) related to the area of interest reveals suspicious findings. CEM is also performed

in some patients with suspicious findings following screening mammography if there is no contraindication for contrast administration.

The inclusion criteria of the present study were as follows:

1. CEM was performed due to suspicious breast lesions determined by clinical examination, mammography, or an US.
2. The CEM exam obtained both CC and MLO views for the breast with the suspicious lesion.
3. Definite diagnoses were provided through either a histopathological examination of the surgically excised or needle-biopsied specimens, or by follow-up for lesion stability of at least 2 years.

The exclusion criteria were as follows:

1. Patients receiving neoadjuvant chemotherapy,
2. Patients with any contraindications to contrast material administration,
3. Patients with a known or suspected pregnancy,
4. For multifocal cases, lesions that were superimposed on one another in the projections,
5. Suspicious breast lesions displayed on a single projection.

Contrast-enhanced mammography technique and analysis

CEM examinations were performed using Senographe Essential full-field DM equipment (GE Healthcare, Buc, France) in our breast imaging unit. Iopromide (Ultravist 300) (300 mg/mL at 1.5 mL/kg and not exceeding a maximum dose of 120 mL) was administered intravenously from the antecubital fossa at a rate of 3 mL/s using a power injector, followed by a 20-mL saline flush. Two minutes after the injection, the acquisition was started with a CC image of the affected breast and continued with a CC image of the normal breast and an MLO image of the normal breast, and ended with an MLO image of the affected breast. The four recombined images were generated automatically by processing low- and high-kV images.

All images were evaluated on a mammography workstation in consensus by two radiologists who were experienced in breast imaging. During these analyses, the radiologists were blinded to clinical information and the final diagnosis.

The qualitative assessment steps involved the following:

1. Lesion type [mass or non-mass enhancement (NME)],
2. Conspicuity according to the enhancement intensity of the lesion (low, moderate, or high),
3. Internal enhancement pattern (homogeneous, heterogeneous, or rim enhancement for masses, and homogeneous, heterogeneous, or clumped for NME),¹⁹
4. Assessment of the relative enhancement pattern (ascending, steady, or descending) by visual evaluation of the change in conspicuity of the lesion from the CC (early phase) to MLO (late phase) views. Increase conspicuity from the CC to MLO views was defined as an ascending pattern; if no visual alteration was present in the lesion conspicuity it was defined as steady; a decrease in the conspicuity from the CC to MLO views was defined as a descending pattern.

Examples of the enhancement parameters that were used in the qualitative assessment are shown in Figures 1 and 2.

The quantitative assessments involved the following:

1. Maximum tumor size,
2. Contrast-to-noise ratio (CNR),
3. The percentage of signal difference (PSD) from the CC to MLO views and classification of the relative enhancement patterns as ascending, steady, or descending.

To calculate the CNR, relative gray values were used. A region of interest (ROI) covering the entire lesion was manually drawn on the recombined images. A separate circular ROI was placed over the background tissue showing the most homogeneous signal, adjacent to the tumor. The following formula was applied:

$$\text{CNR} = \frac{T_{\text{mean}} - \text{BG}_{\text{mean}}}{\text{BG}_{\text{sd}}}$$

T_{mean} = mean pixel value in the ROI of the tumor

BG_{mean} = mean pixel value in the ROI of the background

BG_{sd} = standard deviation in the ROI of the background

The CNRs obtained from the recombined images of the CC and MLO views were used as a quantitative measure of early (CNR₁) and late (CNR₂) phase tumor enhancement, respectively (Figure 3).

Main points

- The conspicuity and contrast-to-noise ratio (CNR) of malignant breast lesions are usually higher than those of benign lesions.
- The diagnostic values of quantitative enhancement parameters are higher than those of the qualitative parameters, and CNR at early-phase images is the most successful among them.
- Rim enhancement is the least common internal pattern but is highly predictive of malignancy.
- Quantitatively evaluated descending patterns and negative percentage of signal difference values are highly predictive of malignancy.
- On contrast-enhanced mammography, while high enhancement intensity, rim enhancement, and the descending pattern of relative enhancement in a lesion indicate a malignancy, low enhancement intensity, homogeneous enhancement, and ascending pattern indicate a benign lesion.

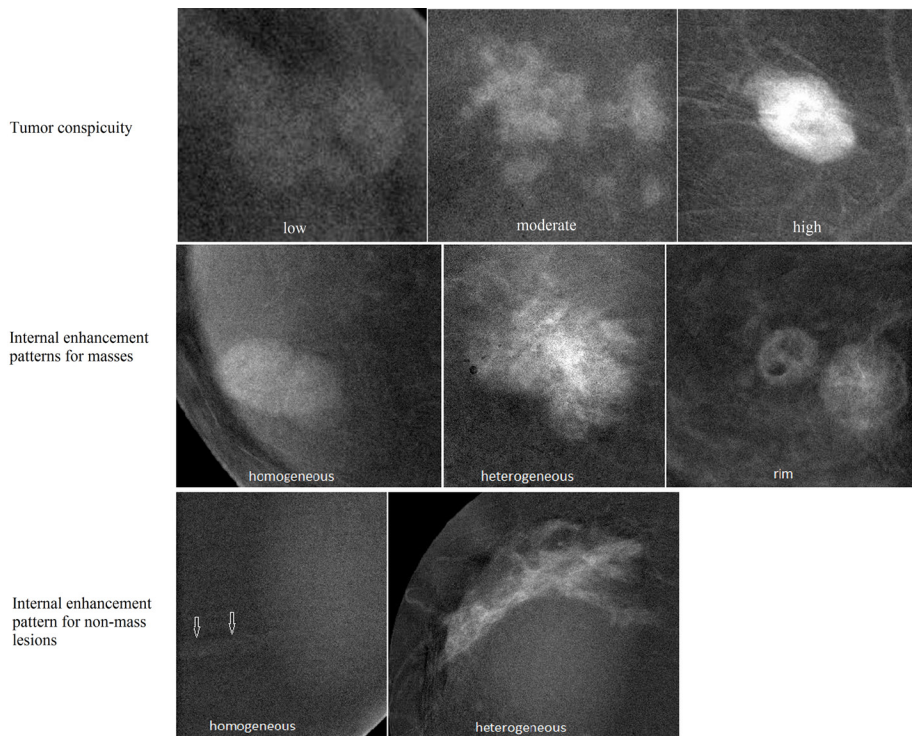


Figure 1. Examples of tumor conspicuity groups (row 1) and internal enhancement patterns for both masses (row 2) and non-mass enhancements (row 3) are demonstrated on contrast-enhanced mammography images.

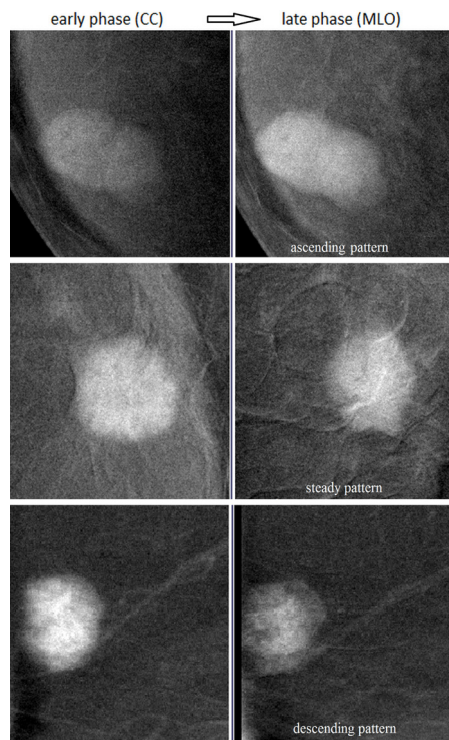


Figure 2. Examples of three qualitatively evaluated relative enhancement patterns on contrast-enhanced mammography. The images in the first column are craniocaudal views (early phase) and those in the second column are mediolateral oblique views (late phase).

The PSD was calculated using the following formula;

$$PSD = (CNR_2 - CNR_1 / CNR_1) \times 100$$

An increase in CNR from the early to late phase exceeding 10% was recorded as ascending and a decrease greater than 10% as descending, while values in between were considered to reflect a steady pattern.

Statistical analysis

Data analysis was performed using the SPSS (v.23.0, IBM, Armonk, NY, USA) software. Descriptive statistics were expressed as mean \pm standard deviation, median and minimum–maximum values for continuous variables, and as a number (n) and percentage (%) for categorical variables. The normal distribution of variables was assessed using the Kolmogorov–Smirnov test. The chi-square and Fisher’s exact tests were used to test for a significant difference between benign and malignant groups for the frequency distribution of categorical variables, and a Student’s t-test or the Mann–Whitney U test for interval variables. Interval variables were compared between the independent groups (CNR_1 with CNR_2) using the Wilcoxon test. Receiver operating characteristic (ROC) analysis was performed to determine the diagnostic accuracy of the CNR and PSD parameters by calculating the area under the curve (AUC)

values. Sensitivity and specificity were calculated after determining the optimal cut-off values for those parameters. Cohen’s kappa statistics and Spearman correlation tests were conducted to document the agreement and association between the qualitative and quantitative CEM parameters. A *P* value of <0.05 was considered statistically significant. The Power and Precision (v3.2) software was used for power calculations.

Results

A total of 136 clinically or radiologically suspicious breast lesions among 105 women (3 lesions in 1, 2 lesions in 26, and single lesions in the remaining 81 women) with a median age of 46 years (range: 26–71 years) were evaluated. Of the 136 lesions, 29 (21%) were benign and 107 (79%) were malignant. The mean size of the lesions was 26 ± 17 mm. There was no statistical difference between the sizes of benign and malignant lesions ($P = 0.390$). Final diagnoses were obtained through the histopathological examination of the surgically excised or needle-biopsied specimens in 130 lesions. A total of 71 invasive ductal carcinoma (IDC), 10 invasive lobular carcinoma, 10 IDC with ductal carcinoma in situ (DCIS), 7 pure DCIS, 4 mixed invasive ductal-lobular carcinoma, and 5 other malignancies were identified. For the benign lesions, there were 6 cases of fibrocystic changes/epithelial hyperplasia, 4 cases of mastitis, 4 fibroadenomas, 3 papillo-

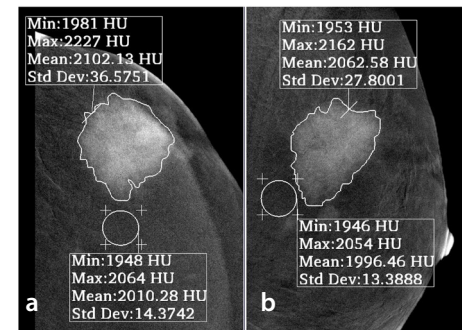


Figure 3. To calculate the enhancement intensity of the lesion, a region of interest (ROI) covering the entire lesion was manually drawn on the recombined images, and a separate circular ROI was placed over the most homogenous background tissue adjacent to the tumor. The mean pixel values of the tumor (T_{mean}) and background tissue (BG_{mean}), as well as the standard deviation of the signal from the background tissue (BG_{sd}), were used to calculate the contrast-to-noise ratio ($CNR = T_{mean} - BG_{mean} / BG_{sd}$); CNR_1 of the mass characterized as an invasive ductal carcinoma (measured on the craniocaudal view) was 6.40 (a); CNR_2 measured on the mediolateral oblique view was 5.01 (b). The percentage of signal difference was -22 , representing a descending pattern. CNR, contrast-to-noise ratio.

mas, and 6 other benign lesions. Another 6 lesions were characterized as stable during a follow-up of at least 2 years.

For the affected breasts, the mean time interval between the start of the contrast injection and CC view was 148 ± 34 s; between the start of the contrast injection and the MLO view, this interval was 270 ± 55 s. Descriptive and CEM imaging features of the lesions are documented in Table 1. Among the lesions, 121 (89%) were masses and 15 (11%) were classified as NME.

Tumor conspicuity was significantly higher in the malignant lesions compared with benign lesions ($P < 0.001$); 86% of the benign lesions had low-moderate conspicuity, whereas 64% of the malignant lesions had high conspicuity. Of the 4 benign lesions

with high conspicuity, 3 were mastitis and 1 was epithelial hyperplasia. Eight malignant tumors had low conspicuity, 2 of which were DCIS; the remainder were invasive cancer tumors smaller than 15 mm.

As quantitative parameters of tumor enhancement, both CNR_1 and CNR_2 were higher for the malignant lesions compared with the benign lesions ($P < 0.001$). In the benign lesions, CNR_2 was significantly higher than CNR_1 ($P < 0.001$), whereas CNR_1 was significantly higher than CNR_2 in the malignant lesions ($P = 0.045$) (Figure 4). The PSD was significantly higher in benign lesions compared with malignant lesions (36.3 vs. 0.6, $P < 0.001$) (Figure 5). 57% (61/107) of the malignant lesions had negative PSD values, and 86% (25/29) of benign lesions had

positive PSD values. While malignant lesions frequently tended to lose their enhancement at late acquisition, benign lesions commonly exhibited ascending enhancement. When ROC curves were plotted using the final diagnoses as a reference, AUC values of 0.816 [95% confidence interval (CI), 0.738–0.893], 0.717 (95% CI, 0.624–0.818), and 0.726 (95% CI, 0.627–0.825) were obtained for CNR_1 , CNR_2 , and PSD, respectively (Figure 6). A cut-off value of 2.50 for CNR_1 yielded 82% sensitivity and 72% specificity, whereas a cut-off value of 10% for PSD yielded 79% sensitivity and 65% specificity. The power of the study for CNR_1 and PSD was 99.4% and 94.9%, respectively.

Of the 11 malignant NMEs, 6 exhibited clumped, 4 heterogeneous, and 1 homo-

Table 1. Descriptive and contrast-enhanced mammography imaging features of the 136 breast lesions in this study

	Benign	Malignant	P value
Number of cases	29	107	
Lesion size (mm)			
Mean \pm standard deviation	23.8 \pm 21.4	27.1 \pm 16.2	
Minimum–maximum	5–96	6–100	0.390
Median	18	25	
Lesion type**			
Mass	25 (86%)	96 (90%)	
NME	4 (14%)	11 (10%)	0.019
CEM qualitative enhancement parameters			
Lesion conspicuity**			
Low	12 (41%)	8 (8%)	
Moderate	13 (45%)	30 (28%)	<0.001
High	4 (14%)	69 (64%)	
Internal enhancement pattern**			
Homogeneous	15 (52%)	22 (21%)	
Heterogeneous	13 (45%)	58 (54%)	0.001
Rim	1 (3%)	27 (25%)	
Relative enhancement pattern**			
Ascending	16 (55%)	34 (32%)	
Steady	12 (35%)	38 (35%)	0.024
Descending	3 (10%)	35 (33%)	
CEM quantitative enhancement parameters			
CNR_1 *	2.26 \pm 0.93	4.34 \pm 2.09	<0.001
CNR_2 *	2.83 \pm 1.07	4.05 \pm 1.81	<0.001
PSD*	36.3 \pm 48.8	0.6 \pm 32.6	<0.001
Relative enhancement pattern**			
Ascending	20 (69%)	36 (34%)	
Steady	7 (24%)	24 (22%)	<0.001
Descending	2 (7%)	47 (44%)	

*Data represent mean values \pm standard deviation, **Data represent numbers and percentages of cases. NME, non-mass enhancement; CEM, contrast-enhanced mammography; CNR, contrast-to-noise ratio; PSD, percentage of signal difference.

geneous enhancement. Of the 4 benign NMEs, 2 exhibited homogeneous, 1 heterogeneous, and 1 clumped enhancement. Clumped enhancement was grouped in the heterogeneous pattern for statistical analyses. The most common internal enhancement pattern was homogeneous in benign lesions (52%) and heterogeneous (54%) in malignant lesions ($P = 0.001$). Rim enhancement was seen in 28% (27/96) of malignant and 4% (1/25) of benign masses ($P = 0.020$). The benign lesion with rim enhancement was a 25-mm papilloma. Rim enhancement revealed a positive predictive value (PPV) of 96% for a breast cancer diagnosis.

Ninety percent of benign lesions exhibited an ascending-steady pattern on the visual evaluation of relative enhancements. Descending enhancement was detected in 33% of malignant and 10% of benign lesions ($P = 0.032$). In the quantitative evaluation, the most common pattern was ascending in

benign lesions (69%) and descending in malignant lesions (44%). The ascending pattern was significantly more common in benign than malignant lesions (69% vs. 35%) ($P = 0.002$). A descending pattern was observed in 44% (47/107) of malignant and 7% (2/29) of benign lesions ($P = 0.001$). All benign lesions, except for 2 papillomas, exhibited ascending or steady-type enhancement. Visually and quantitatively evaluated descending patterns had a PPV of 92% and 96% for breast cancer diagnosis, respectively.

A strong positive correlation was present between tumor conspicuity and CNR_1 values (correlation coefficient: 0.831, $P < 0.001$) (Figure 7). Additionally, visually and quantitatively analyzed relative enhancement patterns were compatible in 70% of cases (kappa: 0.548, $P < 0.001$).

For both benign and malignant lesions, tumor conspicuity and CNR_1 were found to be significantly higher in tumors equal to or larger than 20 mm in diameter compared with smaller tumors ($P < 0.010$). A statistically significant positive correlation was detected between lesion size and CNR_1 value (0.693 for benign, and 0.313 for malignant lesions, $P < 0.001$). There was no difference between the enhancement intensities of mass and non-mass-like (NML) lesions. In the benign group, the mean CNR_1 was 2.19 for masses and 2.67 for NMLs ($P = 0.647$). In the malignant group, the mean CNR_1 was 4.39 for masses and 3.93 for NMLs ($P = 0.821$). Additionally, no significant difference was observed for CNR_1 between invasive and non-invasive cancers (4.4 and 3.6, respectively, $P = 0.457$), or between benign lesions and non-invasive cancer (2.5 and 3.6, respectively, $P = 0.231$).

Discussion

In the present study, we evaluated the three enhancement parameters (degree of enhancement, internal enhancement pattern, and relative change in enhancement intensity from early to late projection) of 136 clinically or radiologically suspicious breast lesions using qualitative and quantitative analyzes on CEM. The distribution of all the enhancement parameters differed significantly between benign and malignant lesions.

In 2022, the American College of Radiology released a supplement that included the first version of the breast imaging reporting and data system lexicon for CEM to standardize the interpretation and reporting of imaging findings.¹⁹ One of the parameters investigated in the present study was an enhancement descriptor of this lexicon called "lesion conspicuity," which is defined as the degree of enhancement relative to the background. Low conspicuity, which refers to enhancement equal to or slightly greater compared with the background, was present in 41% of the benign and 8% of the malignant cases. Conversely, 64% of malignant and 14% of benign tumors had high conspicuity. Tumors with high conspicuity were more likely to be malignant and reflected 64% sensitivity and 86% specificity. Previously, Nicosia et al.²⁰ evaluated lesion conspicuity in recombined CEM images and reported 80% sensitivity and 72% specificity when moderate and high conspicuity were accepted as predictive of malignancy. Several studies were also conducted on tumor enhancement before publication of the CEM lexicon.^{2,9,15,16,21} These studies also found a significant correlation between the

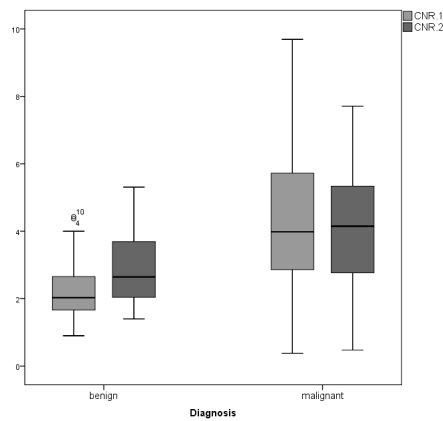


Figure 4. Comparison of early- (CNR_1) and late-phase enhancement intensity (CNR_2) values of benign and malignant lesions. Both CNR_1 and CNR_2 were higher in malignant lesions compared with benign lesions. CNR, contrast-to-noise ratio.

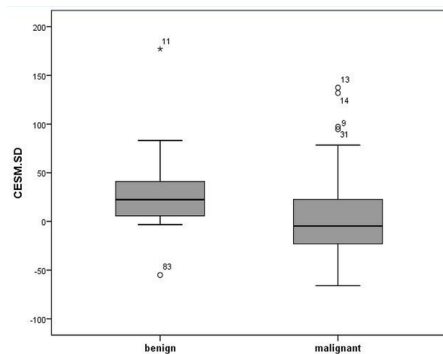


Figure 5. A comparison of the percentage signal difference (PSD) values of benign and malignant lesions; the PSD was significantly higher in benign lesions compared with malignant lesions (28.3 vs. 1.3).

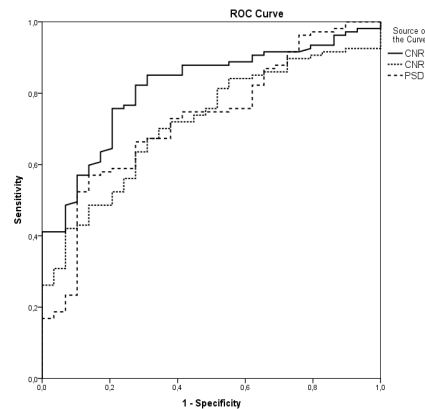


Figure 6. Receiver operating characteristic curves for CNR_1 , CNR_2 , and PSD in the diagnosis of malignant breast lesions. Area under the curve values of 0.816, 0.717, and 0.726 were obtained for CNR_1 , CNR_2 , and PSD, respectively. PSD, percentage signal difference.

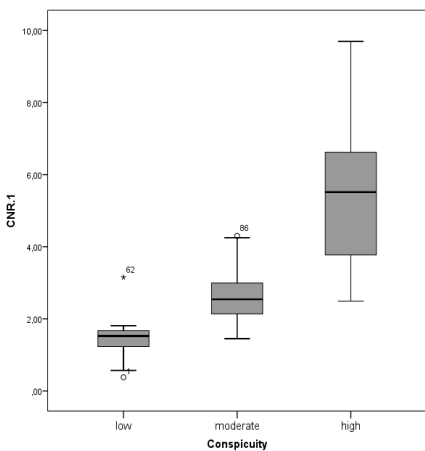


Figure 7. The correlation between lesion conspicuity and quantitative enhancement intensity (CNR_1). CNR, contrast-to-noise ratio.

degree of enhancement and the probability of a lesion being malignant. Minimal or no enhancement has been reported in 22%–73% of benign and up to 8% of malignant lesions. More than 40% of malignant lesions with minimal or no enhancement in those studies were DCISs. In the present study, only 2 of 8 lesions with low conspicuity were DCISs, and the remaining lesions were invasive cancer with a size smaller than 15 mm. Low conspicuity and the absence of enhancement, although highly predictive of benign lesions, do not exclude in situ or invasive cancer on CEM images.

We detected a strong positive correlation between tumor conspicuity and the CNR_1 value (correlation coefficient: 0.831). According to quantitatively evaluated parameters, CNR_1 (a measure of early-phase enhancement intensity) (AUC: 0.816) was more effective than CNR_2 (a measure of late-phase enhancement intensity) (AUC: 0.717) and PSD (a measure of percentage changes in the enhancement intensity from the early to late phase) (AUC: 0.726) for differentiating malignant from benign lesions. As in the case of lesion conspicuity, tumors with a higher CNR_1 were more likely to be malignant, reflecting 82% sensitivity and 72% specificity. Liu et al.¹⁴ and Rudnicki et al.¹⁵ also used quantitative methods to evaluate the enhancement intensity of lesions in two projections. Liu et al.¹⁴ reported a significant difference between the enhancement intensities in two projections and reported that earlier projections of contrast-enhanced images (AUC: 0.843) played a more important role in the differential diagnosis of breast lesions compared with later projections (AUC: 0.755), which was similar to the results obtained in our study. However, Rudnicki et al.¹⁵ could not detect a significant enhancement difference between early- and late-phase images (AUCs of 0.725 and 0.713), which was likely related to the short time interval between the images.

The optimal timing for imaging the affected breast to better differentiate benign from malignant lesions is not known. Additionally, there are many variations in the methods used to evaluate the degree of enhancement in CEM studies.^{2,14–16} These are not just at the level of formulas used to calculate enhancement level but also at the area chosen for background signal measurement and the ROI size, extent and placement. A study conducted by Lv et al.¹⁶ compared the effectiveness of relative gray values when different locations for background signal (the area around the lesion, away from the lesion, close to the chest wall, and the chest wall) were chosen.

The authors found that relative gray values were more effective when the background area around the lesion was used. In our study, we preferred using the background area around the lesion, with reference to the research of Lv et al.¹⁶ However, future studies are needed to compare the effectiveness of different techniques and methods.

Both in the present study and the study conducted by Liu et al.¹⁴, no significant difference was observed between the enhancement intensities of non-invasive and invasive cancers. However, Rudnicki et al.¹⁵ reported significantly higher enhancement levels for infiltrating compared with non-infiltrating cancers. On the other hand, tumor size emerged as an important determinant of enhancement intensity in our study. Larger tumors demonstrated higher conspicuity and CNR_1 values, which was likely related to the effect of tumor volume on the projection images. While this positive correlation between size and CNR_1 was prominent for benign tumors (correlation coefficient: 0.693), it was fair (correlation coefficient: 0.313) for breast cancers; this was likely the result of a reduced enhancement caused by tumoral necrosis, which is commonly observed in large malignant lesions.

The level of tumor enhancement is not the only enhancement descriptor that should be considered; another descriptor is the internal enhancement pattern, which is classified as homogeneous, heterogeneous, or rim types for masses and homogeneous, heterogeneous, or clumped types for NMLs.¹⁹ Different from the MRI lexicon, the internal patterns of clustered ring and non-enhancing septations are not present in the CEM lexicon. The lower resolution of CEM compared with MRI hinders the discernibility between these two patterns. In our study population, the most common internal enhancement pattern was homogeneous for benign and heterogeneous for malignant lesions. Heterogeneous and rim enhancement as indicators of malignancy exhibited 79% sensitivity. However, specificity was extremely low (52%). Although not a common finding, rim enhancement was documented in 28% of malignant and 4% of benign masses and provided 96% PPV. Previously, Chi et al.¹³ reported rim enhancement in 11% (33/312) of lesions, among which 67% were malignant and 33% were benign. Kamal et al.²² detected rim enhancement in 14% (24/168) of masses, 54% of which were benign and 46% were malignant. Contrary to these studies^{9,22} that reported rim enhancement as an unreliable sign for predicting malignancy, we found rim

enhancement to be a highly predictive feature for breast cancer.

Enhancement kinetics are routinely used for the characterization of breast tumors in DCE-MRI. In general, benign lesions exhibit a persistent pattern, whereas malignant lesions reflect a wash-out pattern. A plateau can be observed in both benign and malignant lesions. Kuhl et al.¹¹ previously reported a washout pattern in 57% of malignant and 6% of benign lesions, and a persistent pattern in 83% of benign and 9% of malignant lesions as the worst curve-type on DCE-MRI. However, a low percentage of malignant tumor volume (reported as 7%–40% for invasive cancers) shows washout pattern.^{23–25} Kim et al.²³ reported the worst curve type as wash-out in 84% of breast cancers, whereas the predominant curve type was persistent in 96% of cases.

Only two mammographic projections were used in this study to evaluate changes in the enhancement intensity of lesions from the early to late phase, which was not sufficient for conducting an actual kinetic evaluation; instead, we identified it as a relative enhancement pattern in the present study. As previously described, enhancement values that were evaluated on recombined views represented the entire tumor volume, and the mean gray values were used in the CNR calculation. The relative enhancement patterns that we obtained were more like the predominant curves of DCE-MRI studies. Therefore, the descending pattern rate in the present and previous CEM studies^{2,5,14,18,26} was not as high as the wash-out pattern reported in Kuhl's et al.¹¹ study. In the present study, ascending enhancement was significantly more common in benign lesions (69% vs. 35%), while descending enhancement was observed in 43% of malignant and 7% of benign lesions; these results reflect those of previous studies.^{2,14} The PSD was significantly lower in malignant lesions compared with benign ones (1.3 vs. 28.3, $P < 0.001$), and 94% of lesions with negative PSD values were malignant. Quantitatively evaluated descending patterns and negative PSD values were highly predictive for malignancy (PPV of 96% and 94%, respectively). The quantitative assessment of relative enhancement patterns was more effective than the qualitative assessment concerning the characterization of breast tumors. However, CNR_1 was the most valuable parameter in our study in terms of the characterization of breast lesions, in contrast with the recent study conducted by Rong et al.¹⁸, which reported a kinetic pattern as being more effective than enhancement intensity.

There are several limitations in the present study. First, it included patients from a single institution, and, specifically, the number of benign cases, non-mass lesions, and non-invasive cancers among the patients was limited. Since patients for whom there was a high suspicion of the presence of a malignancy had undergone CEM, there was an inherent bias in favor of malignancy. Nevertheless, the study had adequate statistical power. Second, the enhancement parameters in different histopathologies and lesion types were not discussed due to the small number of cases included in each subtype. To remove the bias and increase the impact of the findings, further large-scale multicenter studies including screening cohorts may be helpful. Third, two different views were applied for the analysis of relative enhancement patterns through the evaluation of changes in enhancement intensity from the early to late phases. This does not reflect a true kinetic evaluation, and we are unsure how comparable this method is with kinetics obtained from DCE-MRI. Further studies with MRI correlations are thus needed. The more accurate evaluation of enhancement kinetics could likely have been achieved if two or more acquisitions in the same projection had been used in the analysis. Additionally, the optimal time intervals for demonstrating enhancement kinetics in CEM are unclear. Although we adjusted the time intervals, in line with previous DCE-MRI studies, it was unclear whether iodine in CEM acted similarly to gadolinium in DCE-MRI. Fourth, CEM is a two-dimensional method, and the enhancement values are relative values affected by the size of the lesion, as well as the size and composition of superimposed normal breast tissue. Therefore, it might offer only limited insight into the temporal changes in tumoral enhancement. Furthermore, we used the entire tumor area and mean values for the calculation of quantitative enhancement parameters and did not compare these with other potential measurements, such as using the tumor area exhibiting the highest enhancement or using maximum values instead of means. Additionally, inter-observer variability was not evaluated. Finally, we evaluated the probable value of CEM enhancement parameters in the differentiation of benign and malignant lesions. However, these parameters may also correlate with the prognostic factors and molecular subtypes of breast cancer, which were not analyzed in the present study.

In conclusion, enhancement intensity and the relative enhancement patterns of breast tumors can be evaluated both quali-

tatively and quantitatively on CEM images. Combined with internal enhancement patterns, they can be used in the differential diagnosis of breast lesions. Quantitative parameters appear to be more diagnostic than qualitative parameters, and the relative enhancement intensity on early-phase images (CNR_r) is the most successful among them. However, it should be noted that the enhancement intensity on CEM depends on the lesion size, and although low enhancement is highly predictive of a lesion being benign, it does not exclude in situ or even invasive cancers. While high enhancement intensity at the early phase, rim enhancement, and descending patterns are features that are considered highly predictive for malignancy, low enhancement intensity, homogeneous enhancement, and ascending patterns are more predictive for benign lesions. These enhancement parameters are capable of contributing to CEM in lesion characterization and may also have prognostic value for breast cancer patients. This is a subject that requires further investigation.

Conflict of interest disclosure

The authors declared no conflicts of interest.

References

1. Polat DS, Evans WP, Dogan BE. Contrast-enhanced digital mammography: technique, clinical applications, and pitfalls. *AJR Am J Roentgenol.* 2020;215(5):1267-1278. [\[CrossRef\]](#)
2. Deng CY, Juan YH, Cheung YC, et al. Quantitative analysis of enhanced malignant and benign lesions on contrast-enhanced spectral mammography. *Br J Radiol.* 2018;91(1086):20170605. [\[CrossRef\]](#)
3. Francescone MA, Jochelson MS, Dershaw DD, et al. Low energy mammogram obtained in contrast-enhanced digital mammography (CEDM) is comparable to routine full-field digital mammography (FFDM). *Eur J Radiol.* 2014;83(8):1350-1355. [\[CrossRef\]](#)
4. Lalji UC, Jeukens CR, Houben I, et al. Evaluation of low-energy contrast-enhanced spectral mammography images by comparing them to full-field digital mammography using EUREF image quality criteria. *Eur Radiol.* 2015;25(10):2813-2820. [\[CrossRef\]](#)
5. Dromain C, Balleyguier C, Muller S, et al. Evaluation of tumor angiogenesis of breast carcinoma using contrast-enhanced digital mammography. *AJR Am J Roentgenol.* 2006;187(5):528-537. [\[CrossRef\]](#)
6. James JJ, Tennant SL. Contrast-enhanced mammography (CESM). *Clin Radiol.* 2018;73(8):715-723. [\[CrossRef\]](#)

7. Perry H, Phillips J, Dialani V, et al. Contrast-enhanced mammography: a systematic guide to interpretation and reporting. *AJR Am J Roentgenol.* 2019;212(1):222-231. [\[CrossRef\]](#)
8. Kim JY, Kim SH, Kim YJ, et al. Enhancement parameters on dynamic contrast enhanced breast MRI: do they correlate with prognostic factors and subtypes of breast cancers? *Magn Reson Imaging.* 2015;33(1):72-80. [\[CrossRef\]](#)
9. Wang C, Wei W, Santiago L, Whitman G, Dogan B. Can imaging kinetic parameters of dynamic contrast-enhanced magnetic resonance imaging be valuable in predicting clinicopathological prognostic factors of invasive breast cancer? *Acta Radiol.* 2018;59(7):813-821. [\[CrossRef\]](#)
10. Macura KJ, Ouwerkerk R, Jacobs MA, Bluemke DA. Patterns of enhancement on breast MR images: interpretation and imaging pitfalls. *Radiographics.* 2006;26(6):1719-1734. [\[CrossRef\]](#)
11. Kuhl CK, Mielcareck P, Klaschik S, et al. Dynamic breast MR imaging: are signal intensity time course data useful for differential diagnosis of enhancing lesions? *Radiology.* 1999;211(1):101-110. [\[CrossRef\]](#)
12. Mohamed Kamal R, Hussien Helal M, Wessam R, Mahmoud Mansour S, Godda I, Alieldin N. Contrast-enhanced spectral mammography: Impact of the qualitative morphology descriptors on the diagnosis of breast lesions. *Eur J Radiol.* 2015;84(6):1049-1055. [\[CrossRef\]](#)
13. Chi X, Zhang L, Xing D, Gong P, Chen Q, Lv Y. Diagnostic value of the enhancement intensity and enhancement pattern of CEM to benign and malignant breast lesions. *Medicine (Baltimore).* 2020;99(37):e22097. [\[CrossRef\]](#)
14. Liu Y, Zhao S, Huang J, et al. Quantitative analysis of enhancement intensity and patterns on contrast-enhanced spectral mammography. *Sci Rep.* 2020;10(1):9807. [\[CrossRef\]](#)
15. Rudnicki W, Heinze S, Niemiec J, et al. Correlation between quantitative assessment of contrast enhancement in contrast-enhanced spectral mammography (CESM) and histopathology-preliminary results. *Eur Radiol.* 2019;29(11):6220-62266. [\[CrossRef\]](#)
16. Lv Y, Chi X, Sun B, Lin S, Xing D. Diagnostic value of quantitative gray-scale analysis of contrast-enhanced spectral mammography for benign and malignant breast lesions. *J Comput Assist Tomogr.* 2020;44(3):405-412. [\[CrossRef\]](#)
17. Rudnicki W, Heinze S, Popiela T, Kojs Z, Luczynska E. Quantitative assessment of contrast enhancement on contrast enhancement spectral mammography (CESM) and comparison with qualitative assessment. *Anticancer Res.* 2020;40(5):2925-2932. [\[CrossRef\]](#)
18. Rong X, Kang Y, Xue J, Han P, Guang Y, Li Z. Contrast-enhanced spectral mammography:

- are kinetic patterns useful for differential diagnoses of enhanced lesions? *Diagn Interv Radiol.* 2023;29(2):244-250. [\[CrossRef\]](#)
19. American College of Radiology. ACR BI-RADS Atlas 5th edition. Published 2022. Accessed Feb 22, 2023. [\[CrossRef\]](#)
 20. Nicosia L, Bozzini AC, Palma S, et al. Breast imaging reporting and data system and contrast enhancement mammography: lesion conspicuity likelihood of malignancy and relationship with breast tumor receptor status. *Acad Radiol.* 2023;30(10):2243-2251. [\[CrossRef\]](#)
 21. Łuczyńska E, Niemiec J, Hendrick E, et al. Degree of enhancement on contrast enhanced spectral mammography (CESM) and lesion type on mammography (MG): comparison based on histological results. *Med Sci Monit.* 2016;22:3886-3893. [\[CrossRef\]](#)
 22. Kamal RM, Helal MH, Mansour SM, et al. Can we apply the MRI BI-RADS lexicon morphology descriptors on contrast-enhanced spectral mammography? *Br J Radiol.* 2016;89(1064):20160157. [\[CrossRef\]](#)
 23. Kim JY, Kim JJ, Hwangbo L, et al. Kinetic heterogeneity of breast cancer determined using computer-aided diagnosis of preoperative MRI scans: relationship to distant metastasis-free survival. *Radiology.* 2020;295(3):517-526. [\[CrossRef\]](#)
 24. Nam SY, Ko ES, Lim Y, et al. Preoperative dynamic breast magnetic resonance imaging kinetic features using computer-aided diagnosis: association with survival outcome and tumor aggressiveness in patients with invasive breast cancer. *PLoS One.* 2018;13(4):e0195756. [\[CrossRef\]](#)
 25. Song SE, Cho KR, Seo BK, Woo OH, Jung SP, Sung DJ. Kinetic features of invasive breast cancers on computer-aided diagnosis using 3T MRI data: correlation with clinical and pathologic prognostic factors. *Korean J Radiol.* 2019;20(3):411-421. [\[CrossRef\]](#)
 26. Jong RA, Yaffe MJ, Skarpathiotakis M, et al. Contrast-enhanced digital mammography: initial clinical experience. *Radiology.* 2003;228(3):842-850. [\[CrossRef\]](#)