



Volumetric segmentation analysis of the levator ani muscle using magnetic resonance imaging in pelvic floor function assessment

Ayşenur Buz Yaşar
 Rüveyde Begüm Yüzok
 Emine Dağistan

Bolu Abant İzzet Baysal University, Training and Research Hospital, Department of Radiology, Bolu, Turkey

PURPOSE

In this case-control study, we aimed to evaluate how muscle volume affects pelvic floor function by analyzing the levator ani muscle (LAM) using volumetric segmentation in addition to standard magnetic resonance (MR) defecography assessments.

METHODS

We enrolled 85 patients with varying degrees of pelvic floor dysfunction (PFD) and 85 age- and gender-matched controls in this retrospective study. All patients had MR defecography images, while all controls had pelvic MR images obtained for other reasons. Group comparisons were performed using independent samples t-tests and Mann-Whitney U tests. The receiver operating curve (ROC) was constructed to establish a cut-off value for a normal LAM volume. Interrater reliability was assessed by calculating the intraclass correlation coefficient. A *P* value of less than 0.05 was considered statistically significant.

RESULTS

Volumetric measurements revealed that the control group had higher LAM volumes, and the ROC curve analysis indicated a cut-off value of 38934.3 mm³ with a sensitivity of 0.812 and specificity of 0.8 for PFD assessment using LAM volumetric measurement. Gender did not significantly affect LAM volume in the control group.

CONCLUSION

Alongside the useful structural and functional information acquired from MR defecography images, volumetric analysis, and three-dimensional reconstructions of LAM may help to improve the accuracy of the diagnosis.

KEYWORDS

Segmentation, levator ani muscle, pelvic floor dysfunction, magnetic resonance defecography, volumetric measurement

Pelvic floor dysfunction (PFD) is a comprehensive term that refers to a broad group of medical conditions that can affect the suspensory ligaments, fascial coverings, and muscles supporting the pelvic organs.^{1,2} It is a common disorder with an estimated prevalence of 25 percent among women in the United States.³ The etiological factors of PFD include female gender, a history of vaginal childbirth, chronic constipation, pelvic surgery, obesity, genetic predisposition, menopause, and aging.^{1,3,4}

The anatomical structures in the pelvic region include the bladder, prostate, uterus, vagina, and rectum, which are evaluated in three compartments: anterior (bladder and urethra), middle (uterus and vagina), and posterior (rectum, anal canal).^{2,4} These structures are attached by the endopelvic fascia, the pelvic diaphragm, and the urogenital diaphragm and function as a single unit.¹ The levator ani muscle (LAM) is a complex funnel-shaped structure consisting of three main components: the pubococcygeus (pubovaginalis, puboprostaticus, puboperineal, puboanal), puborectalis, and iliococcygeus.⁴⁻⁶ Damage or weakening of the LAM is the most common cause of pelvic organ prolapse (POP), resulting in a distorted shape of muscle that

Corresponding author: Ayşenur Buz Yaşar

E-mail: aysenurbuz@gmail.com

Received 06 November 2023; revision requested 29 November 2023; last revision received 02 January 2024; accepted 18 January 2024.



Epub: 20.02.2024

Publication date: 08.07.2024

DOI: 10.4274/dir.2024.232586

You may cite this article as: Buz Yaşar A, Yüzok RB, Dağistan E. Volumetric segmentation analysis of the levator ani muscle using magnetic resonance imaging in pelvic floor function assessment. *Diagn Interv Radiol.* 2024;30(4):220-227.

tends to tilt more vertically and widen the levator hiatus. An insult to the pelvic floor muscles or ligaments can lead to urinary or fecal incontinence, dyspareunia, constipation, and pelvic pain.^{2,6}

Radiologically, for the assessment of these structures, magnetic resonance (MR) defecography uses sagittal balanced steady-state gradient echo (GRE) (different vendors have similar sequences with different trade names, such as True-FISP, FIESTA, and balanced-FFE) images, and a reference line called the pubococcygeal line (PCL) is drawn from the lower border of the pubic symphysis to the last coccygeal joint.^{1,2,7} The distance perpendicular from the posterior wall of the anorectal component to the PCL is called the “M line”, which corresponds to a measure of the location of the anorectal junction. The “H line” is the distance from the inferior border of the pubic symphysis to the posterior of the anorectal component and represents the anteroposterior width of the levator hiatus (Figure 1).⁷

MR defecography is a dynamic examination that allows evaluation at rest, during contraction, and defecation.^{1,2,4} In the anterior compartment, the position of the urethra and bladder can be assessed for diagnoses such as urethral hypermobility and cystocele. In the middle compartment, uterine or cervical prolapse can be observed. In the posterior compartment, pathologies like rectocele or rectal intussusception can be detected.^{4,8} The classic PCL, H, and M lines are utilized for the radiological grading of these pathologies. Additionally, measuring the anorectal angle (ARA) and its dynamic changes are important in diagnosing pelvic floor dyssynergia.⁹

The thickness and volume measurement of the LAM have been investigated through ultrasound (US), computed tomography (CT), and MR studies, and the factors influencing the muscle volume and architecture have been explored.¹⁰⁻¹² In our study, we hypothesize that the LAM volume is lower in patients with PFD than in healthy individuals. Alongside routine evaluations in MR defecography, we aimed to assess the impact of muscle volumes on the POP by conducting a volumetric segmentation analysis of the LAM.

Methods

This retrospective study was approved by the Bolu Abant İzzet Baysal University Clinical Research Ethics Committee and written informed consent was waived by it (date of project: 22.08.2023; project decision number: 262). This research study was conducted in accordance with the Declaration of Helsinki. The STARD guidelines were followed for reporting and joint recommendations of the ESUR and ESGAR Pelvic Floor Working Group

were followed for patient preparation, image acquisition, and interpretation.^{8,13-15}

Patient selection

A total of 85 patients (M: 16, F: 69), aged between 19 and 92 years old, with varying levels of PFD, as well as 85 controls (M: 16, F: 69) with ages ranging from 20 to 85 years old, were included in this study. The control group consisted of individuals without pelvic floor pathology identified in MR imaging (MRI) assessments at rest but with pelvic MRI taken for other medical reasons. The participants' MR defecography and pelvic MRI were recruited from picture archiving communication systems. All MRI were acquired at the radiology department between September 2020 and November 2023. Patients with poor quality imaging due to artifacts on MR scan, inadequate or incomplete imaging, or in whom volumetric measurements could not be performed were excluded from participation, as were control group participants with findings of PFD on pelvic MRI. There were no patients with a history of pelvic region radiotherapy or oncological surgery in the patient population and control group (Figure 2 shows a flowchart of the study).

Patient preparation

For MR defecography images, patients were asked to empty their bladders and bowels 1–2 hours before the MRI examination. The patient should be trained about the imaging steps (rest, squeeze, strain, Valsalva maneuver, and defecation) prior to the MRI examination. Immediately before imaging, 120–180 mL of rectal gel was injected gently through the anal canal in the decubitus position to fill the rectum. Preparation for a pelvic MRI involves wearing comfortable clothes, removing all metallic accessories, and discussing potential contrast allergies.

Magnetic resonance imaging protocol and image acquisition

The MRI scans of all patients participating in the study were performed on the General

Main points

- Pelvic floor dysfunction (PFD) encompasses various medical conditions affecting the supportive ligaments, fascial coverings, and the muscles in the pelvic region.
- The levator ani muscle (LAM) is a critical component, and damage or weakening of this muscle is a common cause of pelvic organ prolapse (POP) and related conditions like incontinence, dyspareunia, and pelvic pain.
- Our study indicates that individuals with PFD tend to have a lower LAM volume, with a specific cut-off value for muscle volume linked to a higher tendency for PFD.
- However, contrary to initial assumptions, no linear correlation between the severity of POP or pelvic floor relaxation and muscle volume was observed in this study.

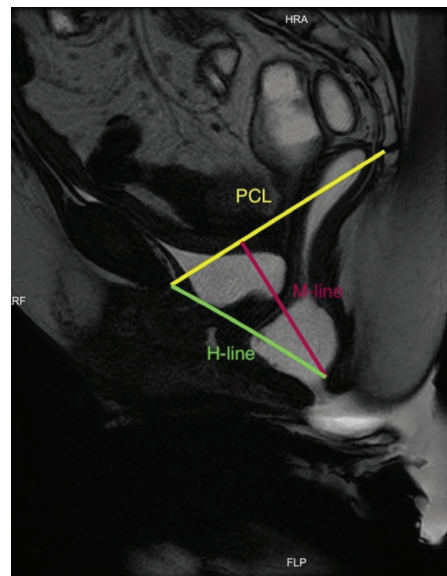


Figure 1. Reference lines of magnetic resonance defecography measurements at rest (pubococcygeal line: yellow line; H-line: green line; M-line: red line). PCL, pubococcygeal line; FLP, foot left posterior; HRA, head right anterior.

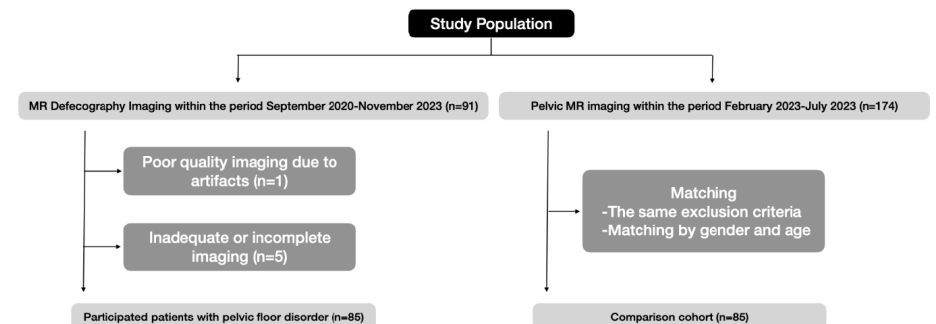


Figure 2. Flowchart of the study. MR, magnetic resonance.

Electric Signa™ Explorer MR 1.5T closed system device (GE Healthcare, Chicago, Illinois, IL, United States) using a phased array body coil without contrast material administration. The patient was positioned lying horizontally with the face and torso facing up with knees elevated on a pillow. To protect the scanner during imaging, adult diapers and disposable sheets were used. MR defecography consists of both static and dynamical sequences including sagittal, coronal, and axial static T2-weighted images at rest, sagittal and coronal cine balanced steady-state GRE while squeezing and straining, and coronal cine balanced steady-state GRE images during defecation at least three times until the rectum is emptied as much as possible (detailed information is summarized in Table 1). The entire defecography procedure duration varied between 15 to 30 minutes. Pelvic MR protocol includes sagittal and axial T2-weighted, coronal fat-saturated T2-weighted images,

axial T1-weighted fast-spin echo images, axial diffusion-weighted images with a *b* value of 50 and 800, and axial liver acquisition with volume acceleration (LAVA) images. In cases where contrast media was required, dynamic sagittal LAVA images (for female patients only) and axial contrast-enhanced LAVA images were obtained. Pelvic MRI lasts approximately 20–30 minutes (Table 2).

Routine magnetic resonance defecography and pelvic magnetic resonance imaging interpretation

Two radiologists (E.D. and A.B.Y.) evaluated the MRI in consensus. An independent radiologist (R.B.Y.), who was blinded to the outcomes, concurrently interpreted a randomly selected subset of 35 cases. All metric measurements including PCL, H, and M-lines at rest and defecation, ARA at rest, squeezing and defecation, levator plate angle (LPA, the angle between the levator plate and PCL) at

maximal straining, and urethral angle (the angle between the urethra and PCL) were completed on midline sagittal MRI. The severity of cystocele and uterine prolapse was graded according to the depth of the herniation under the PCL as mild (less than 3 cm), moderate (3 to 6 cm), and severe (greater than 6 cm).^{8,16,17} A rectocele is characterized by the rectal wall extending beyond the anticipated typical shape, with grading based on the extent of protrusion: small (<2 cm), moderate (2–4 cm), and large (>4 cm), determined by the depth of the bulge.¹⁸ The assessment of pelvic diaphragm relaxation based on M-line lengths was evaluated using the H-line, M-line, and organ prolapse (HMO) classification system. A normal hiatal position was defined as an M-line measurement between 0 and 2 cm (grade 0), while mild descent was categorized as an M-line measurement ranging from 2 to 4 cm (grade 1). Moderate descent was characterized by an M-line

Table 1. Magnetic resonance defecography protocol

Plane	MR sequence	TR/TE (ms)	Matrix size/NEX	Slice thickness (mm)	Spacing (mm)	FOV (cm x cm)	Information type	Phase
Sagittal	Static, T2 PROPELLER	7570/152.32	288 x 288/4	4	1	25 x 25	Structural	Rest
Coronal	Static, T2 PROPELLER	3859/148.99	288 x 288/4	4	1	34 x 34	Structural	Rest
Axial	Static, T2 PROPELLER	5195/121.3	320 x 320/4	4	1	35 x 35	Structural	Rest
Sagittal midline	Dynamic, Cine FIESTA	4/1.4	256 x 288/4	6	1	25 x 25	Functional	Squeeze (Kegel)
Coronal	Dynamic, Cine FIESTA	5/2.02	256 x 288/4	6	1	25 x 25	Functional	Squeeze (Kegel)
Sagittal midline	Dynamic, Cine FIESTA	4/1.91	256 x 288/4	6	1	25 x 25	Functional	Strain (Valsalva)
Coronal	Dynamic, Cine FIESTA	5/2.01	256 x 288/4	6	1	25 x 25	Functional	Strain (Valsalva)
Sagittal midline	Dynamic, Cine FIESTA	5/1.9	256 x 288/4	6	1	25 x 25	Functional	Defecation (at least 3 times)

MR, magnetic resonance; TR, time of repetition; TE, time of echo; NEX, number of excitations; FOV, field of view.

Table 2. Pelvic magnetic resonance protocol

Plane	MR sequence	TR/TE (ms)	Matrix size/NEX	Slice thickness (mm)	Spacing (mm)	FOV (cm x cm)
Sagittal	T2 PROPELLER	6.121/113.74	288 x 288/4	5	1	25 x 25
Axial	T2 PROPELLER	4.146/96.62	300 x 300/4	5	1	32 x 32
Coronal	T2 FAT-SAT PROPELLER	6.446/96.82	300 x 300/4	5	1	32 x 32
Axial	T1 fast spin echo	552/10.28	320 x 224/4	5	1	32 x 32
Axial	Diffusion-weighted imaging <i>b</i> value: 50–800	5.835/78.90	256 x 288/4	5	1	32 x 32
Axial	Apparent diffusion coefficient	5.835/78.90	128 x 128/4	5	1	32 x 32
Axial	LAVA	6/3.15	280 x 192/4	6	1	32 x 32
Sagittal* (female protocol)	Dynamic, contrast-enhanced LAVA	3/1.84	320 x 192/4	4	1	32 x 32
Axial*	Contrast-enhanced LAVA	6/3.15	280 x 192/4	4	1	32 x 32

*Only obtained for contrast-enhanced studies. MR, magnetic resonance; TR, time of repetition; TE, time of echo; NEX, number of excitations; FOV, field of view; LAVA, liver acquisition with volume acquisition.

measurement between 4 and 6 cm (grade 2), and severe descent was indicated when the M-line measurement exceeded 6 cm (grade 3).¹⁹ On the other hand, a normal hiatal width was defined as an H-line measurement between 0 and 6 cm (grade 0), while mild hiatal enlargement was categorized as an H-line measurement ranging from 6 to 8 cm (grade 1). Moderate enlargement was characterized by an H-line measurement between 8 and 10 cm (grade 2), and severe enlargement was indicated when the H-line measurement exceeded 10 cm (grade 3).¹⁹ Urethral hypermobility is a condition of excessive horizontal translation (more than 30°) of the urethra due to a weak pelvic floor.¹

Levator ani muscle manual segmentation and volumetric measurements

For analyzing the medical image data, a free and open-source imaging package software [three-dimensional (3D) Slicer version 5.2.2 for Mac OS X] was utilized. A radiologist with eight years' experience (A.B.Y.), and a radiology resident with five years' experience (R.B.Y.) manually segmented the LAM from the contiguous axial T2-weighted MRI slices using the "Segment Editor" module in the 3D Slicer software. The anterior boundary of the LAM is defined as the pubic symphysis, whereas the posterior boundary of the LAM is defined as the coccyx. The muscles surrounding the anal canal and rectum were delineated. Quantitative information, includ-

ing the number of voxels, the volume of the muscle, minimum, maximum, mean, and median values, standard deviation, and surface area, derived using the "Segment Statistics" module, was noted. For each patient and control, 3D reconstruction models of the LAM were also created (Figures 3, 4). The average time to segment the LAM required 10 minutes per patient.

Statistical analysis

All statistical analyses were conducted using the SPSS 24.0 software (IBM Corp., Armonk, NY, USA). Metric measurements and quantitative segmentation results were reported with means and standard deviations. The normality of distribution was assessed using the Shapiro–Wilk test. Normally distributed data were compared using the independent samples t-test, while non-normally distributed data were evaluated using the Mann–Whitney U test. A chi-square test was used to compare the observed frequencies of categorical data. Subgroup comparisons within the patient group were done using the Kruskal–Wallis test. The receiver operator characteristic (ROC) curve was drawn to assess the sensitivity and specificity of the volumetric measurement, and the optimal cut-off value was selected. The intraclass correlation coefficient was used to estimate the interrater reliability of the MR defecography measurements. A *P* value of less than 0.05 was considered statistically significant.

Results

Demographic characteristics

The mean age was calculated as 53.54 ± 15.7 years for the patient group and 51.99 ± 13.4 years for the control group. There was no significant difference between the groups in terms of age. In both groups, the distribution of men and women was equal. Among 69 female participants, 14 in the case and 13 in the control groups had undergone a hysterectomy (*P* value, 0.632).

Routine magnetic resonance imaging of pelvic floor and magnetic resonance defecography findings

Pelvic floor measurements were performed in both the patient and control groups where applicable. The mean PCL length was calculated as 102.24 ± 9.9 mm, the H-line at rest was 49.35 ± 9.8 mm, and the M-line at rest was 15.97 ± 11.7 mm for the patient group. Conversely, the mean PCL length was calculated as 103.06 ± 10.9 mm, the H-line at rest as 31.06 ± 5.4 mm, and the M-line at rest as 6.12 ± 3.2 mm for the control group. The remaining measurements were only performed in the patient group. The H-line at defecation was calculated as 69.07 ± 17.1 mm, and the M-line at defecation was 43.21 ± 21.3 mm. The average ARA angle at rest was 96.11 ± 17.04°, 82.71 ± 17.8° at strain, and 113.01 ± 22.4° at defecation. The mean LPA at maximal straining was 37.86 ± 20.1°; 61.2 percent of the patients (*n* = 52) had urethral hypermobility. Only 4 patients had peritoneocele (Table 3). The most common pathologies were grade 1 cystocele (*n* = 36, 42.4%) and mild hiatal enlargement (*n* = 35, 41.2%) followed by grade 1 anterior rectocele (*n* = 32, 37.6%), grade 2 anterior rectocele (*n* = 26, 30.6%), and mild pelvic floor descent (*n* = 25, 29.4%). Data regarding POP and pelvic floor relaxation are outlined in Table 4.

Interrater reliability of magnetic resonance defecography assessment

To determine interrater reliability, 35 patients were selected randomly and two re-

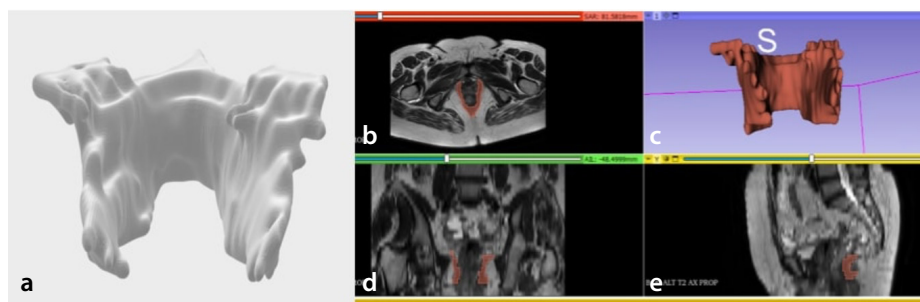


Figure 3. An example of levator ani muscle (LAM) segmentation and three-dimensional (3D) image reconstruction in a healthy individual. Image (a) represents a completed volume rendered segmentation model of the LAM. On the right is a screenshot of the 3D-Slicer software "Segment Editor" module. Image (b) shows an axial T2-weighted series, which are the source images we loaded for segmentation analysis. Images (d, e) show a coronal and sagittal view of the LAM, reconstructed by 3D-Slicer to edit the segment, and image C is a real-time 3D model of LAM.




Figure 4. Pipeline of the study. MR, magnetic resonance.

viewers (blinded to each other) interpreted the PCL line at rest, H-line at rest and defecation, M-line at rest and defecation, ARA at rest, maximal strain and defecation, and LPA. The intraclass correlation analysis revealed excellent agreement (Table 5).²⁰

Levator ani muscle volumetric measurement

The mean number of voxels was calculated as $12,896.5 \pm 5202.9$ for the patient group and $18,778.1 \pm 6784.1$ for the control group. The mean volume of LAM was quantified as $33,214.6 \pm 11,884.6 \text{ mm}^3$ for the patient group and $48,107.9 \pm 12,274.2 \text{ mm}^3$ for the control group. The mean surface area of the patient group was $15,425.8 \pm 4,022.2 \text{ mm}^2$ and $19,458.4 \pm 4,467.9 \text{ mm}^2$ for the control group (Table 3).

Association of levator ani muscle volume and pelvic floor dysfunction

Voxel numbers, LAM volumes, and surface area were higher in the control group. Since the data were not normally distributed, the number of voxels, segment volume, and surface area of the patients and controls' LAM were compared using the Mann-Whitney U test. For each variable, a statistically significant difference was observed (*P* values were <0.001). PFD is defined as the presence of conditions that may affect any compartments, including hiatal enlargement, pelvic floor descent, cystocele, uterine prolapse, rectocele, and peritoneocele. The ROC curve analyses were performed to evaluate the sensitivity and specificity of the volume and surface area measurement of the LAM on PFD. A cut-off value of $38,934.3 \text{ mm}^3$ was set

with a 0.812 sensitivity and 0.8 specificity for the LAM volume. The area under the curve (AUC) was computed as 0.834. For surface area measurement, the AUC was calculated as 0.753, and the cut-off value was set as $16,639.4 \text{ mm}^2$ with a sensitivity of 0.753 and specificity of 0.706 (Figure 5). We also compared the mean volume of the LAM in the patient group, depending on the severity of hiatal enlargement, pelvic floor descent, and POP. When the disease worsened, no statistically significant change in the muscle volume was observed (*P* values were 0.440, 0.929, and 0.732, respectively).

Effect of gender on levator ani muscle volume

No statistically significant difference was observed between female ($n = 69$) and male

	Patient group	Control group	<i>P</i> value
Age (year, mean \pm SD)	53.54 \pm 15.7	51.99 \pm 13.4	0.489 ^a
Gender distribution (M/F, n)	16/69	16/69	1 ^b
Hysterectomy rate of women (n, and percent)	14 (16.5%)	13 (15.3%)	0.632 ^b
PCL rest (mm, mean \pm SD)	102.24 \pm 9.9	103.06 \pm 10.9	0.609 ^a
H-line rest (mm, mean \pm SD)	49.35 \pm 9.8	31.06 \pm 5.4	<i>P</i> < 0.001 ^c
M-line rest (mm, mean \pm SD)	15.97 \pm 11.7	6.12 \pm 3.2	<i>P</i> < 0.001 ^c
H-line defecation (mm, mean \pm SD)	69.07 \pm 17.1	N/A	N/A
M-line defecation (mm, mean \pm SD)	43.21 \pm 21.3	N/A	N/A
ARA rest ($^\circ$, mean \pm SD)	96.11 \pm 17.04	N/A	N/A
ARA strain ($^\circ$, mean \pm SD)	82.71 \pm 17.8	N/A	N/A
ARA defecation ($^\circ$, mean \pm SD)	113.01 \pm 22.4	N/A	N/A
LPA maximal straining ($^\circ$, mean \pm SD)	37.86 \pm 20.1	N/A	N/A
LAM volume (mm^3 , mean \pm SD)	33,214.6 \pm 11884.6	48,107.9 \pm 12274.2	<i>P</i> < 0.001 ^a
LAM surface area (mm^2 , mean \pm SD)	15425.8 \pm 4022.2	19,458.4 \pm 4467.9	<i>P</i> < 0.001 ^a
LAM number of voxels (mean \pm SD)	12896.5 \pm 5202.9	18,778.1 \pm 6784.1	<i>P</i> < 0.001 ^a
	n, percentage		
Urethral hypermobility	52 (61.2%)	N/A	N/A
Peritoneocele	4 (4.7%)	N/A	N/A

^aIndependent samples t-test results; ^bFisher's exact test results; ^cMann-Whitney U test results. SD, standard deviation; M, male; F, female; n, number; PCL, pubococcygeal line; ARA, anorectal angle; LPA, levator plate angle; LAM, levator ani muscle.

	Absent (n, percent)	Grade 1 (n, percent)	Grade 2 (n, percent)	Grade 3 (n, percent)
Cystocele	41 (48.2%)	36 (42.4%)	7 (8.2%)	1 (1.2%)
Uterine prolapse	40 (72.7%)	11 (20%)	4 (7.3%)	0 (0%)
Anterior rectocele	21 (24.7%)	32 (37.6%)	26 (30.6%)	6 (7.1%)
	Healthy (n, percent)	Mild (n, percent)	Moderate (n, percent)	Severe (n, percent)
Hiatal enlargement (n, percent)	26 (30.6%)	35 (41.2%)	20 (23.5%)	4 (4.7%)
Pelvic floor descent (n, percent)	15 (17.6%)	25 (29.4%)	23 (27.1%)	22 (25.9%)

n, number.

(n = 16) controls concerning the number of voxels, LAM volumes, and surface areas (P values were 0.419, 0.449, and 0.449, respectively).

Effect of aging on levator ani muscle volume

A weak negative correlation was observed between the age and LAM volume in only the patient group ($r: -0.227$, P value, 0.037). All participants (n = 170) were divided into two groups according to their age; individuals older than 50 years comprised the first group (n = 93) and the remaining individuals represented the second group (n = 77). The average volume of the LAM was significantly lower in the first group (P value, 0.019).

Effect of history of hysterectomy on levator ani muscle volume

No statistically significant difference was observed among the women controls based on their history of hysterectomy (n = 69, and P value is 0.671).

Discussion

In the diagnosis of PFD, clinical examination is generally indefinite in isolation and may lead to the underestimation of pathologies and involved compartments.^{2,15} Various imaging modalities are employed to assess the pelvic floor, particularly the LAM, which represents the active component, including translabial–endovaginal US, CT, fluoroscopy, and MRI.^{15,21} MR defecography imaging offers exceptional spatial and contrast resolution, enabling the delineation of even small tears or injuries, and providing detailed anatomical and functional information.³ In this regard, it plays a crucial role in the concurrent assessment of pelvic organs and pelvic floor muscles without radiation exposure and contrast media administration, unlike dynamic fluoroscopic defecography.²²

In this retrospective case-control study, our primary objective was to investigate the relationship between the volume of the LAM and PFD, and its potential contribution to

routine MR defecography measurements. As we assumed, our results confirmed the presence of a correlation between a decreased LAM volume and PFD. Patients with an LAM volume calculated below 38,934.3 mm³ have a higher tendency toward PFD. However, contrary to our initial hypothesis, we did not observe a linear correlation between the severity of POP or pelvic floor relaxation and muscle volume. The small number of subgroups in the patient group may have affected the reliability of the subgroup comparison results. Further work on larger populations is thus needed to validate our results.

Previous studies focused on LAM segmentation based on transperineal or endovaginal US and MRI.^{10–12} Rabbat et al.²³ proposed using deep learning algorithms to automate LAM segmentation as a means to improve the diagnostic ability of the US. Another study utilizing MRI suggests a modified Chan–Vese segmentation model, which uses intensity information and the influence of shape to segment the LAM in axial slices.²⁴ Compared to manual segmentation, automated segmentation models may shorten the time taken to complete the procedure, which can assist physicians in executing muscle identification, segmentation, 3D reconstruction, and automatic volume measurement.²²

In the current study, we chose manual segmentation, despite the extended time of the process, because it is the reference standard. Despite employing manual segmentation, the fact that one segmentation could be completed in approximately 10 minutes demonstrates its feasibility and appropriateness for clinical work.

As predicted in prior studies, our study participants mostly included women. One of our secondary objectives was to assess the influence of gender on LAM volume in healthy participants. A publication by Cheung et al.²⁵ reports that the LAM has extraordinary androgen sensitivity in rodents and humans. We hypothesized that the volume of the LAM in women may be lower than in men, potentially giving rise to vulnerability to pelvic floor disorders. However, we found that LAM volume, LAM surface area, and the number of voxels were similar for both genders. This suggests that it is the difference in processes, such as pregnancy and childbirth, rather than gender, which may be at play. Cheung et al.²⁵ investigated the LA and walking muscle volumes in patients with prostate cancer receiving androgen deprivation therapy and found that the ther-

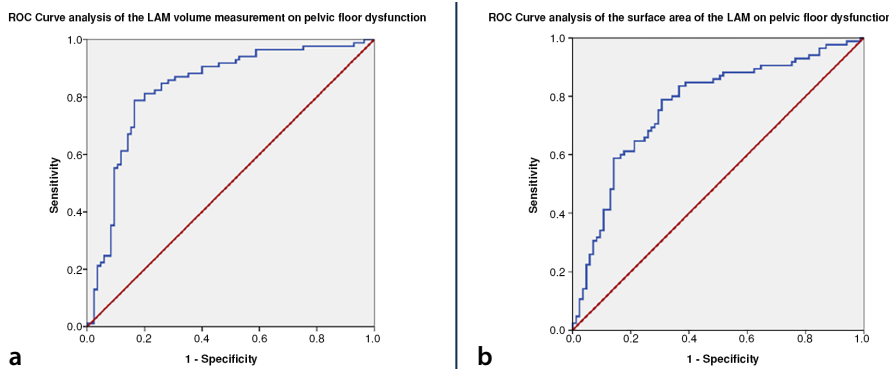


Figure 5. The receiver operating curve analyses of the LAM volume measurement and surface area in the presence of pelvic floor dysfunction. Volumetric measurement: AUC: 0.834, cut-off value: 38,934.3 mm³ with a sensitivity of 0.812 and specificity of 0.8 (a). Surface area measurement: AUC: 0.753, cut-off value 16,639.4 mm² with a sensitivity of 0.753 and specificity of 0.706 (b). LAM, levator ani muscle; AUC, area under the curve.

Table 5. Interobserver correlations of routine magnetic resonance defecography measurements

	Observer 1	Observer 2	ICC	P value
Measurements (n = 35)	(Mean ± SD)	(Mean ± SD)	(95% CI)	
PCL rest (mm)	100.49 ± 10.7	102.09 ± 10.1	0.985 (0.970–0.992)	<0.001
H-line rest (mm)	50.9 ± 9.9	51.2 ± 10.1	0.992 (0.985–0.996)	<0.001
M-line rest (mm)	19.5 ± 12.2	18.6 ± 12.1	0.976 (0.952–0.988)	<0.001
H-line defecation (mm)	71.9 ± 18.5	74.2 ± 18.5	0.955 (0.914–0.977)	<0.001
M-line defecation (mm)	47.5 ± 21.5	48.8 ± 21.2	0.967 (0.936–0.983)	<0.001
ARA rest (°)	99.8 ± 15.7	98.7 ± 14.6	0.948 (0.9–0.973)	<0.001
ARA strain (°)	84.9 ± 18.9	83.4 ± 17.2	0.943 (0.891–0.971)	<0.001
ARA defecation (°)	112.3 ± 22.8	113.7 ± 22.4	0.991 (0.982–0.995)	<0.001
LPA maximal straining (°)	35.6 ± 19.3	37.3 ± 19.6	0.967 (0.936–0.983)	<0.001

ICC, intraclass correlation coefficient; CI, confidence interval; n, number; SD, standard deviation; PCL, pubococcygeal line; ARA, anorectal angle; LPA, levator plate angle.

apy process caused muscle volume loss. The limitation of their study is that patients with prostate cancer often concurrently receive radiation therapy (RT); it should thus be kept in mind that the outcomes may have been influenced by RT rather than the androgen sensitivity of the muscle. There is therefore a need to elucidate the molecular mechanism of androgen sensitivity of the LAM.

Wyman et al.²⁶ conducted a study to evaluate the relationship between LAM volume, age, and body mass index (BMI). Interestingly, the results showed that an increased age in female participants correlated with an elevated LAM volume; however, there was no correlation between BMI and muscle volume. The study authors assumed these results to be related to a reduction in the strength and integrity of the LAM resulting from sarcopenia.²⁶ In their previous paper, the authors evaluated whether the estimated LA subtended volume (eLASV) could predict the success of POP surgical treatment. Their results indicated that patients with a higher eLASV had an increased risk of surgical failure.¹² The main question concerning this study is the absence of a clear definition of the volumetric measurement process described in their paper; accordingly, these findings must be interpreted with caution. In contrast to earlier findings presented by Wyman et al.²⁶, our study reveals that older individuals have a lower LAM volume.

A similar study to the current research was carried out by Nandikanti et al.²⁷ to evaluate the LA bowel volume variation between resting and straining states in patients with POP and healthy controls. The results indicate that hiatus size and bowel volume change during straining.²⁷ To the best of our knowledge, this is the first study comparing LAM volume and routine MR defecography measurements.

This study has some limitations. Due to the retrospective design of the research, we were unable to gather selected information, including BMI, history of pregnancy/vaginal birth, and abortion, which indicate a constant relationship with pelvic floor insufficiency. Additionally, we only assessed LAM volume; however, anal and urethral sphincters, internal obturator muscle, coccygeus muscle, and perineal muscles also play roles in PFD. Finally, the technique for the axial T2 pelvis MRI for the controls was not exactly matched to what was used for MR defecography.

In conclusion, a lower LAM volume appears to show a direct correlation with an increased probability of PFD. Our results did

not reveal a linear correlation between the severity of POP or pelvic floor relaxation and muscle volume. Future research with a larger participant pool is warranted to further investigate this matter.

Acknowledgments

We would like to thank our MRI team.

Conflict of interest disclosure

The authors declared no conflicts of interest.

References

1. Salvador JC, Coutinho MP, Venâncio JM, Viamonte B. Dynamic magnetic resonance imaging of the female pelvic floor—a pictorial review. *Insights Imaging*. 2019;10(1):4. [Crossref]
2. Kanmaniraja D, Arif-Tiwari H, Palmer SL, et al. MR defecography review. *Abdom Radiol (NY)*. 2021;46(4):1334-1350. [Crossref]
3. Wu JM, Vaughan CP, Goode PS, et al. Prevalence and trends of symptomatic pelvic floor disorders in U.S. women. *Obstet Gynecol*. 2014;123(1):141-148. [Crossref]
4. Maccioni F, Alt CD. MRI of the pelvic floor and MR defecography. 2018 Mar 21. In: Hodler J, Kubik-Huch RA, von Schulthess GK, editors. *Diseases of the Abdomen and Pelvis 2018-2021: Diagnostic Imaging - IDKD Book* [Internet]. Cham (CH): Springer; 2018. Chapter 2. [Crossref]
5. Margulies RU, Hsu Y, Kearney R, Stein T, Umek WH, DeLancey JO. Appearance of the levator ani muscle subdivisions in magnetic resonance images. Appearance of the levator ani muscle subdivisions in magnetic resonance images. *Obstet Gynecol*. 2006;107(5):1064-1069. [Crossref]
6. Gowda SN, Bordoni B. Anatomy, abdomen and pelvis: levator ani muscle. [Updated 2022 Oct 26]. In: StatPearls [Internet]. Treasure Island (FL): StatPearls Publishing; 2023 Jan-. [Crossref]
7. Li M, Wang B, Liu X, Qiao P, Jiao W, Jiang T. MR defecography in the assessment of anatomic and functional abnormalities in stress urinary incontinence before and after pelvic reconstruction. *Eur J Radiol*. 2020;126:108935. [Crossref]
8. El Sayed RF, Alt CD, Maccioni F, et al. Magnetic resonance imaging of pelvic floor dysfunction – joint recommendations of the ESUR and ESGAR Pelvic Floor Working Group. *Eur Radiol*. 2017;27(5):2067-2085. [Crossref]
9. Haliloglu N, Erden A. Magnetic resonance defecography findings of dyssynergic defecation. *Pol J Radiol*. 2022;87(1):181-185. [Crossref]
10. Zhang X, Xiang Y, Yao J, et al. Automatic segmentation of the female pelvic floor muscles on MRI for pelvic floor function

assessment. *Quant Imaging Med Surg*. 2023;13(7):4181-4195. [Crossref]

11. Asif Z, Tomashev R, Peterkin V, et al. Levator ani muscle volume and architecture in normal vs. muscle damage patients using 3D endovaginal ultrasound: a pilot study. *Int Urogynecol J*. 2023;34(2):581-587. [Crossref]
12. Wyman AM, Tanner JP, Bassaly R, Hoyte L, Greene K. Levator ani muscle (LAM) anatomical volume compared to age and body mass index (BMI) of patients. *Int Urogynecol J*. 2020;31(7):1457-1461. [Crossref]
13. Bossuyt PM, Reitsma JB, Bruns DE, et al. STARD 2015: an updated list of essential items for reporting diagnostic accuracy studies. *Radiology*. 2015;277:826-832. [Crossref]
14. <https://www.ohsu.edu/school-of-medicine/diagnostic-radiology/mr-defecography-workbody-protocol> [Crossref]
15. Lalwani N, Khatri G, El Sayed RF, et al. MR defecography technique: recommendations of the society of abdominal radiology's disease-focused panel on pelvic floor imaging. *Abdom Radiol (NY)*. 2021;46(4):1351-1361. [Crossref]
16. Chamié LP, Ribeiro DMFR, Caiado AHM, Warmbrand G, Serafini PC. Translabial US and dynamic mr imaging of the pelvic floor: normal anatomy and dysfunction. *Radiographics*. 2018;38(1):287-308.
17. Yoon I, Gupta N. Pelvic prolapse imaging. [Updated 2023 May 1]. In: StatPearls [Internet]. Treasure Island (FL): StatPearls Publishing; 2023 Jan-. [Crossref]
18. Thapar RB, Patankar RV, Kamat RD, Thapar RR, Chemburkar V. MR defecography for obstructed defecation syndrome. *Indian J Radiol Imaging*. 2015;25(1):25-30. [Crossref]
19. Picchia S, Rengo M, Bellini D, et al. Dynamic MR of the pelvic floor: influence of alternative methods to draw the pubococcygeal line (PCL) on the grading of pelvic floor descent. *Eur J Radiol Open*. 2019;6:187-191. [Crossref]
20. Landis JR, Koch GG. The measurement of observer agreement for categorical data. *Biometrics*. 1977;33:159-174. [Crossref]
21. Guo M, Li D. Pelvic floor images: anatomy of the levator ani muscle. *Dis Colon Rectum*. 2007;50(10):1647-1655. [Crossref]
22. Boyadzhyan L, Raman SS, Raz S. Role of static and dynamic MR imaging in surgical pelvic floor dysfunction. *Radiographics*. 2008;28(4):949-967. [Crossref]
23. Rabbat N, Qureshi A, Hsu KT, et al. Automated segmentation of levator ani muscle from 3D endovaginal ultrasound images. *Bioengineering (Basel)*. 2023;10(8):894. [Crossref]
24. Ma Z, Jorge RN, Tavares JM. A shape guided C-V model to segment the levator ani muscle in axial magnetic resonance images. *Med Eng Phys*. 2010;32(7):766-774. [Crossref]

25. Cheung AS, Cunningham C, Ko DD, et al. Selective loss of levator ani and leg muscle volumes in men undergoing androgen deprivation therapy. *J Clin Endocrinol Metab.* 2019;104:2229-2238. [\[Crossref\]](#)
26. Wyman AM, Rodrigues Jr AA, Hahn L, et al. Estimated levator ani subtended volume: a novel assay for predicting surgical failure after uterosacral ligament suspension. *Am J Obstet Gynecol.* 2016;214:611. [\[Crossref\]](#)
27. Nandikanti L, Sammarco AG, Chen L, Ashton-Miller JA, DeLancey JO. Levator bowl volume during straining and its relationship to other levator measures. *Int Urogynecol.* 2019;30(9):1457-1463. [\[Crossref\]](#)