



Copyright© Author(s) - Available online at dirjournal.org.
Content of this journal is licensed under a Creative Commons
Attribution-NonCommercial 4.0 International License.

Comparing ultrasound-guided intra-articular injection and medial branch block for lumbar facet joint pain: a clinical study

Hui Zhao^{1-4*}
 Yun-Long Hou^{5*}
 Le-Hang Guo¹⁻⁴
 Qiao Wang¹⁻⁴
 Tian He¹⁻⁴
 Guang-Fei Gu⁶
 Li-Ping Sun¹⁻⁴
 Feng-Shan Jin¹⁻⁴

¹Tongji University Faculty of Medicine, Shanghai Tenth People's Hospital Center of Minimally Invasive Treatment for Tumor, Department of Medical Ultrasound, Shanghai, China

²Tongji University Faculty of Medicine, Ultrasound Research and Education Institute, Clinical Research Center for Interventional Medicine, Shanghai, China

³Shanghai Engineering Research Center of Ultrasound Diagnosis and Treatment, Shanghai, China

⁴National Clinical Research Center for Interventional Medicine, Shanghai, China

⁵The First Hospital of Jiaxing, Department of Medical Ultrasound, Zhejiang, China

⁶Shanghai Tenth People's Hospital Faculty of Medicine, Department of Orthopedics, Tongji University, Shanghai, China

*Joint first authors

Corresponding authors: Li-Ping Sun, Feng-Shan Jin

E-mails: sunliping_s@126.com, jfs198497@163.com

Received 22 March 2024; revision requested 15 April 2024; last revision received 08 July 2024; accepted 29 August 2024.



Epub: 27.11.2024

Publication date: 28.04.2025

DOI: 10.4274/dir.2024.242765

PURPOSE

This study aims to compare the effectiveness of ultrasound-guided intra-articular (IA) injections with medial branch nerve blocks in treating lumbar facet joint pain.

METHODS

This retrospective study enrolled 94 patients clinically diagnosed with lumbar facet joint pain. Diagnostic blocks confirmed the diagnosis in 82 patients, evidenced by a pain visual analog score (VAS) reduction of at least 50% immediately following the injection. Of these, 42 were treated with ultrasound-guided IA injections (group 1), and 40 received ultrasound-guided medial branch blocks (group 2). Effective pain relief was defined as a VAS reduction of at least 50%.

RESULTS

Group 1 showed significantly higher pain relief rates compared with group 2 at both 1-month (54.76% versus 2.5%, $P < 0.001$) and 3-month (26.19% versus 5%, $P = 0.014$) follow-ups. Within group 1, patients aged 21–50 years experienced higher relief rates (81.25% at 1-month and 56.25% at 3-month follow-ups) compared with those over 50 (38.46% at 1-month and 7.69% at 3-month follow-ups), which was statistically significant ($P = 0.007$ at 1-month and $P = 0.001$ at 3-month follow-ups). Furthermore, in group 1, patients with sedentary jobs reported significantly greater pain relief (90.91% at 1-month and 81.82% at 3-month follow-ups) compared with those with non-sedentary jobs (41.94% at 1-month and 6.45% at 3-month follow-ups) ($P = 0.005$ at 1-month and $P < 0.001$ at 3-month follow-ups).

CONCLUSION

Ultrasound-guided IA injection provides better pain relief compared with medial branch nerve blocks. This method serves as a viable alternative for patients, especially younger and middle-aged patients with lumbar facet pain due to sedentary lifestyles.

CLINICAL SIGNIFICANCE

This study compared and analyzed the therapeutic effects of two different ultrasound intervention blockade methods on patients with lumbar facet joint pain, demonstrating that IA injection has a better pain relief effect and can be used as a pain relief method for patients who refuse radiofrequency therapy.

KEYWORDS

Lumbar facet joint pain, intra-articular injection, medial branch block, ultrasound-guided, pain visual analog score

The prevalence of chronic lower back pain (LBP) with various structural etiologies in the general population is about 80%.¹ Lumbar facet joint pain is caused by acute or chronic inflammation of the lumbar zygapophyseal joint and affects 15%–45% of patients with LBP.^{2,3} Regarding general treatment, conservative therapy includes exercise, physical methods, chiropractic care, and analgesics, which can help reduce surrounding muscle spasms and alleviate pain.⁴ Furthermore, facet joint pain relief can be achieved using therapeutic

interventions, including intra-articular (IA) injection, medial branch block (MBB), and radiofrequency ablation.^{5,6} IA injection involves a direct injection into the facet joint capsule, which can utilize the anti-inflammatory effect of hormones to alter inflammation in the joint. MBB alleviates pain by anesthetizing the medial branches of the posterior primary rami, the main nerves responsible for dual innervation to the joint.⁷ Both interventions are effective in facet joint pathology for managing LBP, but it is unclear which of them is superior.⁷ Various studies present differing views on the effectiveness of these treatments. One randomized study suggests that both approaches are equally ineffective in the long-term management of facet-joint-related back pain.⁸ Conversely, another study notes that both treatment options are beneficial,⁹ and a further prospective study indicates that IA injections are more effective than MBBs in patients with positive single-photon emission computed tomography (SPECT) scans.¹⁰

Ultrasound effectively visualizes soft tissue, neural structures, and vascular supply, offering an alternative guidance method for MBBs and IA injections. It is portable, facilitates intra-operative visualization, and does not require protective garments. Ultrasound-guided injection has widespread acceptance in regional anesthesia.¹¹ However, only a few studies have compared the long-term effects of ultrasound-guided IA injections and MBBs. This study aims to compare the effectiveness of ultrasound-guided IA and MBBs in treating lumbar facet joint pain.

Methods

Participants

The Shanghai Tenth People's Hospital Ethics Committee approved this study (protocol number: SHYS-IEC-5.0/22K203/P01, date: 26.09.2022). Before surgery, every patient was required to sign an informed consent form. These forms, along with the clinical and

imaging information pertinent to the study, were systematically archived. The hospital's medical records department will hold onto this data for 10 years. A diagram of the overall study design is shown in Figure 1.

A total of 94 patients diagnosed with lumbar facet joint pain were enrolled in this retrospective study between June 2021 and March 2022. A clinical doctor collected the patients' job types (sedentary or non-sedentary) and baseline pain visual analog score (VAS) before surgery through a questionnaire survey. Out of the 94 patients, 82 were confirmed to have lumbar facet joint pain through diagnostic blocks, which required their VAS score to decrease by at least 50% immediately after injection. Twelve patients who did not experience significant pain relief after treatment were excluded from the study. This study consisted of 40 men and 42 women, with a median age of 55.1 years and an average symptom duration of 8.5 weeks.

Among 82 patients, 42 received ultrasound-guided lumbar IA joint injections (group 1), whereas 40 received ultrasound-guided posterior MBB of lumbar spinal nerve roots (group 2). The primary outcome variable of this study was a 50% reduction in pain intensity from baseline measured at 1 month and 3 months post-operative. The pain extent was measured by a pain VAS. The evaluation at 1-month and 3-month follow-ups were recorded as short-

and medium-term efficacy of both treatment methods.

The inclusion criteria were as follows: (1) axial low back pain and tenderness during spinal extension and movement for 3 months or more, with an average back pain VAS score of more than 3 over the past week; (2) age ≥ 18 years; (3) failure to respond to more conservative therapy (e.g., physical therapy, integrative therapy, and pharmacotherapy). The exclusion criteria were as follows: (1) patients with a known specific etiology for low back pain, such as significant spinal stenosis or spondylolisthesis; (2) focal neurologic signs or symptoms; (3) patients with tuberculosis, lumbar spine tumor, osteomyelitis; (4) untreated coagulopathy; (5) poor compliance and inability to cooperate to complete treatment.

Equipment

Ultrasound guidance was conducted using a LOGIQ E9 with a 3-5MHz convex array transducer (GE Healthcare, Milwaukee, WI, USA). A 21-gauge puncture needle was used (KDL, Shanghai, China) for injection in this study.

Treatment procedure

The patient was placed in a prone position with a thin pillow on the abdomen to reduce lumbar anterior convexity. All procedures were performed by the same physician, who had more than 10 years of experience.

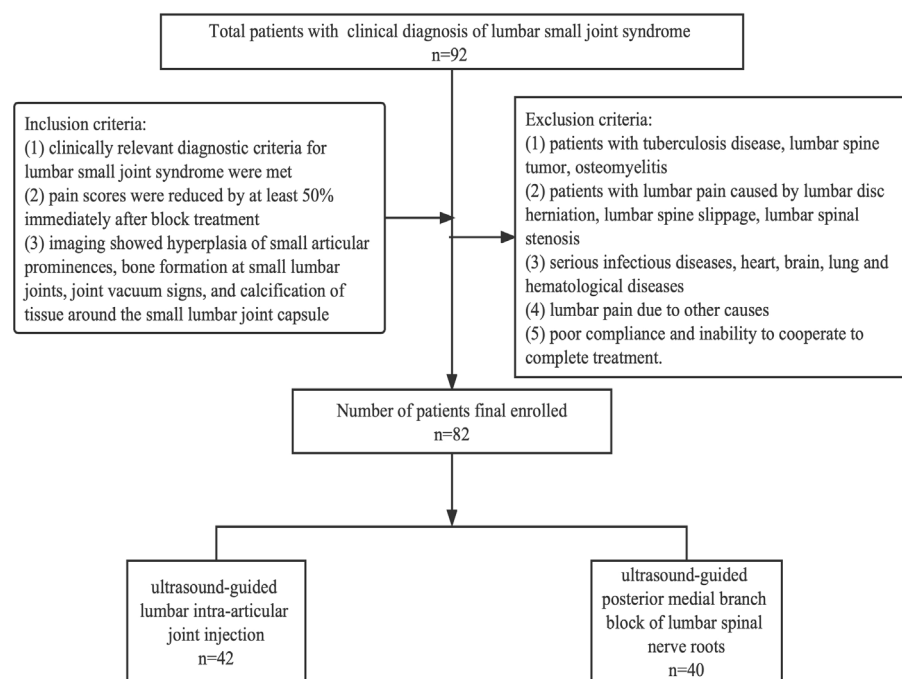


Figure 1. Study flow diagram.

Main points

- For cases that did not respond to conservative treatment, interventional therapy is used for the treatment of lumbar facet joint pain.
- Ultrasound-guided intra-articular (IA) block is effective in relieving pain in the short term.
- When radiofrequency ablation is not feasible, ultrasound-guided IA block provides a viable means of pain management.

rience in musculoskeletal system diseases ultrasound interventional therapy. First, locating the lumbar segment was essential. The transducer was placed in the midsagittal plane to visualize the spinous process of the lumbar vertebra, then moved 2 cm laterally to display the vertebral arch of the lumbar lamina and sacrum. The sacrum appeared as a continuous high-echo on ultrasound. Scanning from the sacrum, the short strip of high-echo above represented the L5 vertebral plate. Moving the probe upwards, the L4, L3, L2, and L1 vertebrae were displayed. On the parasagittal planes of the back, ultrasound clearly showed the high-echo superior and inferior articular processes with the low-echo articular cartilage between them. Then, with a rotated transducer, the transverse plane of the facet joints became visible, which was the target site for lumbar small joint injection (Figure 2).

The transducer was then moved downward to reveal the junction of the upper transverse process and the superior articular process, where the posteromedial branch of the nerve was located, which was the target for the posterior MBB (Figure 3).

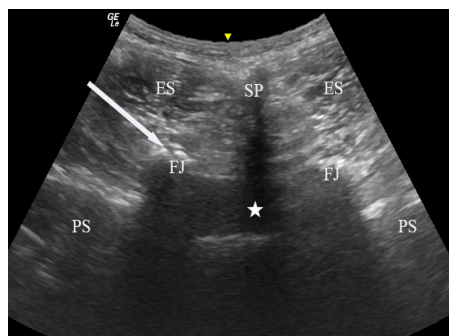


Figure 2. This figure shows the transverse plane of the facet joints. SP, spinous process; FJ, facet joint; arrows, needle; ES, erector spinae; PS, psoas; pentacle, spinal canal.

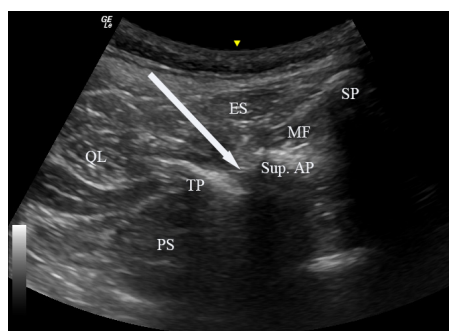


Figure 3. This figure shows the position of the posterior medial branch of the spinal nerve. SP, spinous process; TP, transverse process; Sup. AP, superior articular process; arrows, needle; ES, erector spinae; QL, quadratus lumborum; PS, psoas; MF, multifidus.

After sterile skin preparation and the placement of a fenestrated sterile drape, the needle was inserted in an “in-plane” manner under ultrasound guidance. Once the needle position was confirmed, 2 mL of solution was injected, containing 0.9 mL of 40 mg/mL triamcinolone acetonide, 0.2 mL of 2% lidocaine, and 0.9 mL of 0.9% normal saline. Following the procedure, the patient was observed in the recovery room for 30 minutes without experiencing any adverse effects before leaving. A blinded observer assessed patient pain scores at 30 minutes, 1 month, and 3 months post-treatment. A positive outcome was predefined as a 50% or greater reduction in VAS compared with baseline over the past week, indicating clinically meaningful improvement.⁹

Statistical analysis

All statistical analyses were performed using IBM, Armonk, NY, USA SPSS statistics version 25.0. Regarding demographic characteristics, continuous variables were presented as the mean and standard deviation and were compared between groups. Categorical variables were presented as frequencies and percentages

and analyzed using a chi-squared test. A value of $P < 0.05$ was considered statistically significant.

Results

Table 1 shows baseline demographic and clinical data by group assignment. There were no statistically significant differences in any variables at baseline between the groups. Treatment results following facet injection are shown in Table 2. The proportion of pain relief in group 1 (54.76%, 23/42) was significantly higher compared with that of group 2 (2.5%, 1/40) ($P < 0.001$), with a difference of 0.52 [95% (confidence interval) CI: 0.36–0.68] (Table 2). The proportion of pain relief at 3 months was 26.19% for group 1 and 5% for group 2, with a difference of 0.21 (95% CI: 0.06–0.36). There was a significant difference between the groups ($P = 0.014$). The findings reveal that IA injections, compared with posterior medial branch nerve blocks, provided superior short-term (1-month) pain relief for facet joint disorder. However, both interventions showed limited long-term (3-month) pain relief efficacy, suggesting that additional therapeutic strategies or follow-up interventions may be necessary to

Table 1. Demographic characteristics of patients in both groups

Group	Intra-articular injection group (n = 42)	Posterior medial branch block group (n = 40)	P
Age (years)	57.4 ± 17.4	52.8 ± 15.8	0.218
Gender	Men (19) Women (23)	Men (21) Women (19)	0.511
Duration of illness (months)	9.0 ± 6.5	7.9 ± 5.3	0.419
Visual analog score	6.48 ± 1.0	6.98 ± 0.8	0.052

Table 2. Treatment results and disposition after facet block

Group	Intra-articular injection group n = 42	Posterior medial branch block group n = 40	P
Effective treatment (number, %)	23 (54.76%)	1 (2.5%)	<0.001
1-month			
Age <50	13/16 (81.25%)*	1/18 (5.56%)	
Age ≥50	10/26 (38.46%)	0/22 (0%)	
Sedentary job type	10/11 (90.91%)*	1/17 (5.88%)	
Non-sedentary job type	13/31 (41.94%)	0/23 (0%)	
Visual analog score (mean ± SD)	3.36 ± 1.17	6.5 ± 1.43	<0.001
3-month			
Effective treatment (number, %)	11 (26.19%)	2 (5%)	0.014
Age <50	9/16 (56.25%)*	2/18 (11.11%)	
Age ≥50	2/26 (7.69%)	0/22 (0%)	
Sedentary job type	9/11 (81.82%)*	1/17 (5.88%)	
Non-sedentary job type	2/31 (6.45%)	1/23 (4.35%)	
Visual analog score (mean ± SD)	4.45 ± 1.66	6.7 ± 1.31	<0.001

* $P < 0.05$ within group analysis between different age stratification. * $P < 0.05$ within group analysis between different job type stratification. SD, standard deviation.

maintain or improve pain management over longer periods.

Upon stratifying the analysis by age, it was observed that for young individuals aged 21–50 years in group 1, the effectiveness rates at 1 month and 3 months were 81.25% and 56.25%, respectively. In contrast, among the elderly population aged over 50 years, the effectiveness rates were significantly lower, at 38.46% at 1 month and 7.69% at 3 months ($P_{1\text{-month}} = 0.007$; $P_{3\text{-month}} = 0.001$).

In the analysis by job type, sedentary workers showed significantly higher pain relief rates (90.91% at 1 month, 81.82% at 3 months) after IA block therapy compared with non-sedentary workers (41.94% at 1 month, 6.45% at 3 months). Notably, in group 2, only 2 young men, aged 31 and 29, showed effective outcomes—one with a non-sedentary job and the other with a sedentary job. Age and job type may influence short-term efficacy, with middle-aged and young patients in sedentary jobs more likely to benefit from this treatment.

Discussion

The main finding in this retrospective study is that ultrasound-guided IA injection shows significant posttreatment improvement in pain relief compared with MBBs at 1 month. However, neither technique produced useful sustained pain remissions at 3 months. This is similar to the findings of Robert Cornelius Marks.¹²

Based on fundamental scientific studies, it has been observed that inflammatory mediators are present in and around degenerative facet joints.^{13,14} This presence indicates the potential role of inflammation in causing pain and discomfort. Consequently, it suggests that IA steroid injections may provide short-term pain relief by alleviating synovitis or inflammation related to osteoarthritis through their anti-inflammatory effects.¹⁵

In our stratified analysis by age and job type, we discovered that middle-aged and young individuals, as well as those with sedentary work, are more likely to achieve better pain relief from IA injections. The underlying cause of low back pain in these individuals is primarily attributed to their sedentary lifestyle, which exerts prolonged pressure on the lumbar facet joint, triggering an inflammatory response and stimulating the lumbar spinal nerves around the facet joint. Consequently, administering hormones can reduce the inflammatory response, leading to therapeutic results.⁴ A study suggests that

IA injection is more effective among patients exhibiting an inflammatory process in the facet joint on SPECT imaging.¹⁰ Although our current study did not account for the impact of positive ultrasound signs on efficacy, this aspect will be thoroughly analyzed in our forthcoming study. The research results indicate that injection therapy has limited effectiveness for the elderly and non-sedentary individuals. These individuals usually have significant osteophytes or other degenerative facet joint diseases. IA steroid injections cannot change the structural pressure problem or any other problems of facet joints.

Ultrasound-guided MBB had little apparent therapeutic effect in the short or medium term. We speculate that this may be because the nerve trunk is temporarily blocked while inflammation affecting the peripheral nerves remains. When conduction is restored, the pain reappears.

This study is subject to several limitations. First, its retrospective design introduces the possibility of bias, and the non-randomized allocation of patient treatments could result in selection bias. To mitigate this, patients in the study were enrolled continuously according to strict inclusion and exclusion criteria. Furthermore, no significant statistical differences were observed in the general clinical information across the two data groups. In future studies, we aim to conduct randomized, controlled, and prospective research to further assess the effectiveness of ultrasound-guided block therapy in treating small joint disorders. Second, the relatively small sample size and brief follow-up period limit our ability to evaluate long-term treatment outcomes. Future research will aim to enlarge the sample size and extend the follow-up period.

In conclusion, ultrasound-guided IA injections are more effective than medial branch nerve blocks in patients with lumbar facet joint pain, particularly for non-degenerative lumbar facet joint pain caused by sedentary behavior in young and middle-aged patients. MBBs appear to have no significant therapeutic effect in the short or medium term. For patients who cannot undergo surgery or radiofrequency therapy, ultrasound-guided IA injection of small joints can be chosen to alleviate pain.

Footnotes

Conflict of interest disclosure

The authors declared no conflicts of interest.

References

1. Fast A. Low back disorders: conservative management. *Arch Phys Med Rehabil*. 1988;69(10):880-891. [\[CrossRef\]](#)
2. Van de Kelft E, Verleye G, Van de Kelft AS, Melis K, Van Goethem J. Validation of topographic hybrid single-photon emission computerized tomography with computerized tomography scan in patients with and without nonspecific chronic low back pain. A prospective comparative study. *Spine J*. 2017;17(10):1457-1463. [\[CrossRef\]](#)
3. Rahimzadeh P, Faiz HR, Baghaee AR, Nader ND. Sonoanatomic indices of lumbar facet joints in patients with facetogenic back pain in comparison to healthy subjects. *J Clin Anesth*. 2017;36:67-71. [\[CrossRef\]](#)
4. Seo JH, Baik SW, Ko MH, et al. Comparing the efficacy of combined treatment with medial branch block and facet joint injection in axial low back pain. *Pain Res Manag*. 2021;2021:1343891. [\[CrossRef\]](#)
5. Ogsbury JS 3rd, Simon RH, Lehman RAW. Facet “denervation” in the treatment of low back syndrome. *Pain*. 1977;3(3):257-263. [\[CrossRef\]](#)
6. Koh WU, Kim SH, Hwang BY, et al. Value of bone scintigraphy and single photon emission computed tomography (SPECT) in lumbar facet disease and prediction of short-term outcome of ultrasound guided medial branch block with bone SPECT. *Korean J Pain*. 2011;24(2):81-86. [\[CrossRef\]](#)
7. Bogduk N. International Spinal Injection Society guidelines for the performance of spinal injection procedures. Part 1: Zygapophysial joint blocks. *Clin J Pain*. 1997;13(4):285-302. [\[CrossRef\]](#)
8. Cohen SP, Doshi TL, Constantinescu OC, et al. Effectiveness of lumbar facet joint blocks and predictive value before radiofrequency denervation: the facet treatment study (FACTS), a Randomized, Controlled Clinical Trial. *Anesthesiology*. 2018;129(3):517-535. Erratum in: *Anesthesiology*. 2018;129(3):618. [\[CrossRef\]](#)
9. Cohen SP, Bhaskar A, Bhatia A, et al. Consensus practice guidelines on interventions for lumbar facet joint pain from a multispecialty, international working group. *Reg Anesth Pain Med*. 2020;45(6):424-467. [\[CrossRef\]](#)
10. Ackerman WE 3rd, Ahmad M. Pain relief with intraarticular or medial branch nerve blocks in patients with positive lumbar facet joint SPECT imaging: a 12-week outcome study. *South Med J*. 2008;101(9):931-934. [\[CrossRef\]](#)
11. Wang D. Image guidance technologies for interventional pain procedures: ultrasound, fluoroscopy, and CT. *Curr Pain Headache Rep*. 2018;22(1):6. [\[CrossRef\]](#)
12. Marks RC, Houston T, Thulbourne T. Facet joint injection and facet nerve block: a randomised comparison in 86 patients with chronic

- low back pain. *Pain*. 1992;49(3):325-328. [\[CrossRef\]](#)
13. Willburger RE, Wittenberg RH. Prostaglandin release from lumbar disc and facet joint tissue. *Spine (Phila Pa 1976)*. 1994;19(18):2068-2070. [\[CrossRef\]](#)
 14. Igarashi A, Kikuchi S, Konno S, Olmarker K. Inflammatory cytokines released from the facet joint tissue in degenerative lumbar spinal disorders. *Spine (Phila Pa 1976)*. 2004;29(19):2091-2095. [\[CrossRef\]](#)
 15. Lakemeier S, Lind M, Schultz W, et al. A comparison of intraarticular lumbar facet joint steroid injections and lumbar facet joint radiofrequency denervation in the treatment of low back pain: a randomized, controlled, double-blind trial. *Anesth Analg*. 2013;117(1):228-235. [\[CrossRef\]](#)