



Long-term outcomes of catheter-directed sclerotherapy for ovarian endometrioma

Jae Hwan Lee^{1-3*}

Jihyung Yoon^{4*}

Chong-Ho Lee^{1*}

Kun Yung Kim¹

Chang Jin Yoon¹⁻³

Minuk Kim⁵

Seul Ki Kim⁴

¹Seoul National University Bundang Hospital, Department of Radiology, Gyeonggi-do, South Korea

²Seoul National University College of Medicine, Department of Radiology, Seoul, South Korea

³Seoul National University Medical Research Center, Institute of Radiation Medicine, Seoul, Republic of Korea

⁴Seoul National University Bundang Hospital, Department of Obstetrics and Gynecology, Gyeonggi-do, South Korea

⁵Seoul Metropolitan Government-Seoul National University Boramae Medical Center, Department of Radiology, Seoul, Republic of Korea

PURPOSE

Although favorable results have been reported on catheter-directed sclerotherapy (CDS) for ovarian endometrioma, a thorough evaluation of its long-term efficacy is lacking. This study evaluates the long-term efficacy and safety of CDS with 99% ethanol for treatment of ovarian endometrioma.

METHODS

Between January 2020 and February 2022, data from 33 consecutive patients with symptomatic ovarian endometriomas who underwent CDS were retrospectively evaluated. All patients underwent pre-procedural and 6- and 12-month post-procedural ultrasonography. To assess the effect on ovarian reserve, serum anti-Müllerian hormone (AMH) levels were measured before and after the procedure. Procedure-related complications were also assessed.

RESULTS

The mean volume of endometriomas decreased from 80.22 ± 66.43 to 0.73 ± 1.10 mL ($P < 0.001$), and the mean percentage of volume reduction was $98.99\% \pm 1.53\%$. No recurrences were observed during the follow-up period. In patients whose serum AMH levels were monitored for 1 year, no significant change in AMH level before and after CDS was observed (3.07 ± 1.81 vs. 2.72 ± 2.02 ng/mL, $P = 0.190$). One patient complained of moderate abdominal pain after CDS, which was conservatively managed.

CONCLUSION

CDS remained safe and effective in treating ovarian endometrioma at the 1-year follow-up. Ovarian function after CDS was well preserved.

CLINICAL SIGNIFICANCE

CDS is a safe and effective treatment option for patients with ovarian endometrioma without compromising ovarian function.

KEYWORDS

Endometrioma, interventional, ovary, percutaneous, sclerotherapy

*Joint first authors

Corresponding author: Seul Ki Kim

E-mail: drksk80@gmail.com

Received 06 June 2024; revision requested 08 July 2024; accepted 17 July 2024.



Epub: 01.10.2024

Publication date: xx.xx.2024

DOI: 10.4274/dir.2024.242874

Endometriosis is one of the most common health problems in women of reproductive age.^{1,2} Approximately 10% of reproductive aged women, 30% of women with infertility, and 82% of women with chronic pelvic pain have endometriosis.³ Endometrial tissue lining the wall of an ovarian cyst is defined as an ovarian endometrioma;⁴⁻⁹ it consists of fluid-filled sacs that develop from the accumulation of menstrual contents^{4,5,9,10} and is observed in approximately 45% of patients with endometriosis.^{1,5} Ovarian endometrioma is known to damage adjacent ovarian tissues because it contains reactive oxygen species, proteolytic enzymes, and inflammation-mediating factors.¹¹ This results in fibrosis, a decline in

stromal cells, and a decrease in vascularity, accompanied by follicular loss.¹⁰ A previous meta-analysis of 968 patients revealed that serum anti-Müllerian hormone (AMH), a surrogate marker of ovarian reserve, was lower in patients with ovarian endometrioma than in those without endometrial cysts.¹¹

Currently, the standard treatment for ovarian endometrioma has been laparoscopic cystectomy;^{1,4,5,9,12-14} however, parenchymal injury during surgical excision inevitably results in a decline in the ovarian reserve.^{1,9,12,13,15} Furthermore, relapse is relatively frequent; a pooled analysis of 23 studies involving 4,368 patients demonstrated that the recurrence rate of ovarian endometrioma following surgery was 21.5% and 50% at 2 and 5 years, respectively.¹⁶ Therefore, the use of non-surgical treatments such as aspiration or needle-directed sclerotherapy (NDS) has been advised to treat lesions while minimizing ovarian damage.^{4,6,7,10,17}

NDS uses needles to access the cyst, remove menstrual debris-like contents, and inject sclerosants into the cavity. However, it has inherent technical drawbacks, including needle instability during the process, poor aspiration/injection capability, and the possibility of needle dislodgement and spillage of endometrial tissue debris or sclerosant into the peritoneal cavity.⁶⁻⁸ Thus, the outcomes of NDS have been variable, and the recurrence rate following NDS is relatively high, up to 62.5%.^{10,17,18}

To overcome the limitations of NDS, catheter-directed sclerotherapy (CDS) was developed.⁶⁻⁸ In a small prospective study,⁶ the technical advantages translated into superior short-term clinical results with little harm to the ovarian reserve. However, only a few papers have reported on the procedure, and data regarding the long-term outcomes of CDS and recurrence after the procedure are lacking.⁶⁻⁸ Therefore, this study aims to evaluate the long-term efficacy and safety of CDS with 99% ethanol for ovarian endometriomas.

Methods

Study design

The Seoul National University Bundang Hospital Institutional Review Board approved this retrospective study (decision no: B-2003-602-301; approved on: 05-10-2023) and waived the requirement for informed consent due to the study design. Data of patients who underwent CDS for ovarian endometrioma between January 2020 and February 2022 were obtained from the institution's electronic medical record system (date of access to patient data: 01/20/2023). The inclusion criteria for the CDS procedure were: (a) age >18 years; (b) symptoms suggesting endometriosis (dyspareunia, dysmenorrhea, and lower abdominal or pelvic pain) (c) largest diameter of cyst ≥ 3 cm; (d) ultrasound features suggestive of endometrioma; (e) no evidence of malignancy on contrast-enhanced magnetic resonance or computed tomography images; and (f) serum cancer antigen 125 (CA-125) levels <200 U/mL. Patients who lacked baseline serum AMH levels or were lost to follow-up less than 6 months after CDS were excluded (Figure 1). Following the CDS procedure, patients were required to continue taking dienogest or oral contraceptive pills for at least 2 years to prevent recurrence.¹⁸ During the follow-up period, serum AMH and CA-125 levels were monitored, and the largest diameter and mean volume of the lesion were measured using transvaginal ultrasonography.

Procedures

One board-certified radiologist (J.H.L) with 10 years of experience in interventional radiology and pelvic imaging performed the CDS. The procedure was performed as

previously described.^{6,7} Preprocedural ultrasonography was performed 1–2 weeks prior to CDS to evaluate the lesion characteristics, lesion size/volume, and access route (transvaginal or transabdominal). For transvaginal access, the target lesion was punctured using an 18-G 20 cm needle (Chiba biopsy needle, Bloomington, Cook, USA), followed by the placement of a 0.035-inch hydrophilic guidewire (Radifocus, Terumo, Japan) and 8.5-F drainage catheter (Dawson-Mueller Drainage catheter; Cook). After drainage of the contents and irrigation with normal saline, 2–3 cc of contrast was infused into the lesion to evaluate any signs of leakage or rupture.⁷ If there was no leakage or rupture, 99% ethanol was infused carefully at 25% of the drained volume, with a maximum dose of <100 mL.

The patient's position (clockwise rotation from supine to left decubitus, prone, and right decubitus) was then changed every 5 min. Finally, ethanol was aspirated and the catheter was removed. To rule out malignancy, the aspirated contents were sent to pathology for cytology evaluation.^{6,7} All patients underwent the procedure on the day of admission and were discharged the following day.

Follow-up

All patients underwent ultrasonography at 6 and 12 months after CDS to follow up on cyst size and any recurrence. To evaluate cyst size, the volume of the ovarian endometrioma was calculated using the formula for an ellipsoid, with the length and width of the lesion measured by ultrasound. Volume reduction was calculated by the percentage change in volume from pre-procedure to post-procedure measurements. Serum AMH levels were

Main points

- Catheter-directed sclerotherapy (CDS) for ovarian endometrioma shows durable outcomes at the 1-year follow-up.
- CDS does not seem to result in a decline in ovarian function as measured by anti-Müllerian hormone.
- Procedure-related complications are minimal, suggesting a favorable safety profile for CDS.

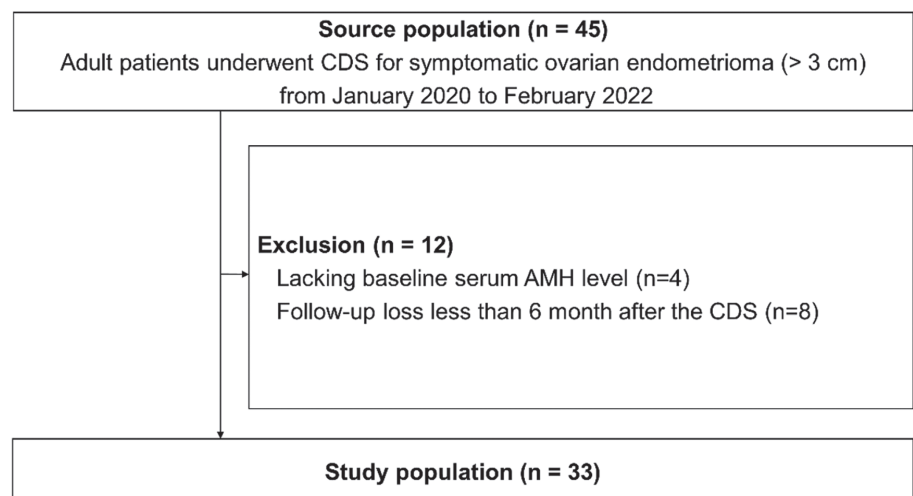


Figure 1. Patient flowchart. CDS, catheter-directed sclerotherapy; AMH, anti-Müllerian hormone.

tested 6 and 12 months after CDS to evaluate the effect of CDS on ovarian reserve. Serum CA-125 levels, which reflect endometrioma burden, were assessed at the same time points. Complications related to the procedure were recorded for each instance.

Statistical analysis

Data are presented as mean \pm standard deviation. Changes in endometrioma volume and serum AMH and CA-125 levels before and after CDS were analyzed using the paired t-test or Wilcoxon signed-rank test, depending on the normality of the variable. The PASW 18.0 software (IBM, Armonk, NY, USA) was used for all statistical analyses. A *P* value of <0.050 was considered statistically significant. Recurrence was defined as the return of symptoms and/or newly developed detectable endometrioma on follow-up ultrasound.

Results

In total, 33 of the 45 patients originally chosen were enrolled in this study; those without baseline serum AMH levels ($n = 9$) and those who were lost to follow-up less than 6 months after CDS ($n = 3$) were excluded. Table 1 summarizes the baseline characteristics of patients and lesions. The mean AMH level was 2.99 ± 2.16 ng/mL. The technical success rate of CDS was 100%. The hospitalization period for all patients was 2 days. One patient experienced moderate abdominal pain (visual analog scale score: 5), but it was resolved with conservative management. All cytological analyses of the aspirates were negative for malignant cells.

The largest diameter and mean volume of the endometriomas continuously decreased for 1 year after CDS (Table 2). The mean volume reduction percentage at 12 months after CDS was $98.99 \pm 1.54\%$. The mean follow-up period was 12 months (range: 8.36–17.5 months), with data focusing primarily on the 12-month outcomes. No recurrences were observed during the follow-up period.

The serum CA-125 level significantly decreased at 6 months and this was maintained at 1 year ($P = 0.010$); however, there was no significant difference in the serum AMH levels before and 1 year after CDS ($P = 0.302$) (Figure 2).

Discussion

This study aimed to evaluate the long-term efficacy and safety of CDS with 99% ethanol for the treatment of ovarian endo-

metriomas. We found that the endometrioma volume rapidly decreased in the first 6 months, with a 99% reduction maintained over a year. The trends in serum CA-125 levels were consistent with the changes in endometrioma volume, reflecting a decrease in the burden of disease. These findings align with previous reports.^{6,7} As the catheter is securely located, the risk of potential spillage of the contents is low, and patients can change their position to enhance the cyst wall exposure to ethanol.^{6,7,10}

Interestingly, the treated endometriomas had not recurred by the end of the follow-up period. No recurrence after CDS has been reported in the literature, including this study.^{6,7} In a review article comparing

11 studies on recurrence rates after ablation or cystectomy, recurrence rates over 1 year ranged from 4.4% to 37.0%.⁴ In previous articles on CDS, as well as in this study, patients were not prevented from continuing medication after the CDS treatment. Given the nature of ovarian endometriomas with frequent recurrence, CDS combined with hormonal treatment seems to suppress the recurrence of endometrioma effectively.

In this study, serum AMH, which reflects the ovarian reserve, was well preserved after CDS. Although laparoscopic cystectomy is the current standard treatment, it has several disadvantages, including the risk of general anesthesia, perilesional adhesions, and decline in ovarian function.^{1,7,15} In addition to

Table 1. Patient and lesion characteristics

| Characteristic | Value |
|---------------------------------|-------------------|
| Age (years) | 31.22 \pm 4.10 |
| CA-125 (U/mL) | 61.11 \pm 50.92 |
| AMH (ng/mL) | 2.99 \pm 2.16 |
| Largest diameter (cm) | 6.21 \pm 1.26 |
| Mean volume (cm ³) | 80.22 \pm 66.43 |
| Unilateral endometrioma [n (%)] | 32 (96.9%) |

Data are presented as mean \pm standard deviation. CA-125, cancer antigen 125; AMH, anti-Müllerian hormone.

Table 2. Long-term outcomes of catheter-directed sclerotherapy

| | Before CDS | 6 months after CDS | 12 months after CDS | <i>P</i> value |
|-----------------------|-------------------|--------------------|---------------------|--------------------------------|
| Largest diameter (cm) | 6.21 \pm 1.26 | 1.65 \pm 1.03 | 0.86 \pm 0.94 | $<0.010^*$ $<0.010^\dagger$ |
| Mean volume (mL) | 80.22 \pm 66.43 | 2.27 \pm 2.51 | 0.73 \pm 1.11 | $<0.010^*$ $<0.010^\dagger$ |

Data are presented as mean \pm standard deviation. *Difference between the value before and 6 months after CDS; †Difference between the value before and 12 months after CDS. CDS, catheter-directed sclerotherapy.

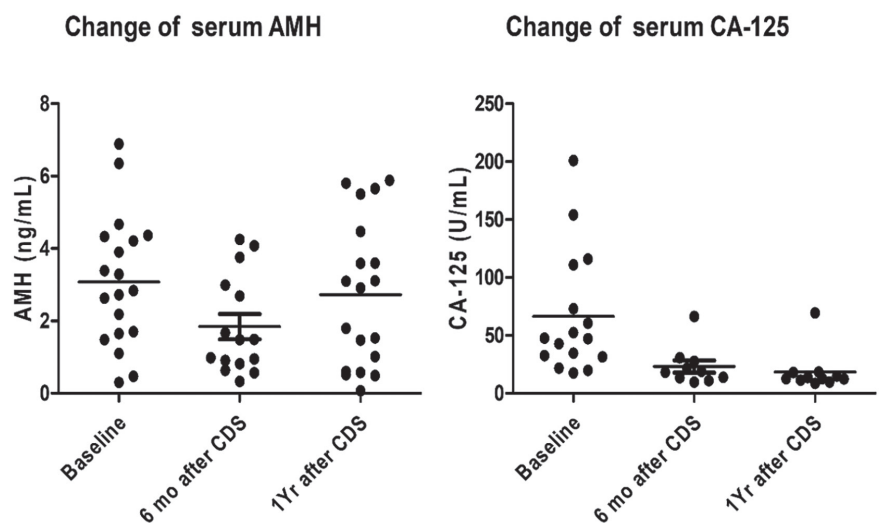


Figure 2. The serial change of serum AMH and CA-125 concentration after CDS. AMH, anti-Müllerian hormone; CA-125, cancer antigen 125; CDS, catheter-directed sclerotherapy; mo, month; Yr, year.

the inevitable removal of ovarian follicles adjacent to the endometrioma, hemostatic cauterization may add collateral damage to the ovarian circulation and cause further follicular loss.¹⁵ In CDS, catheters can be accurately placed in the lesion, and unintended injury to the adjacent healthy ovarian parenchyma can be minimized.

Previous studies have demonstrated AMH changes up to 6 months after the procedure, whereas this study included results up to 12 months, providing the most extended follow-up data available. Furthermore, this study has the advantage of having one skilled expert performing all procedures, eliminating the possibility of variation among different operators.

This study has several limitations. Due to its retrospective design, consistent and comparable data on intraprocedural and postprocedural pain were difficult to obtain. Nevertheless, medical records indicate that only one patient required additional analgesics for abdominal pain beyond conventional post-procedural management, suggesting the procedure was generally well-tolerated. Additionally, having a single operator perform all procedures and the absence of a control group limit the generalizability of the findings. Future prospective studies with standardized pain assessments and comparative analyses are needed.

In conclusion, CDS for ovarian endometrioma showed favorable safety and long-term outcomes without recurrence. The ovarian reserve was well preserved during the follow-up period of 1 year.

Conflict of interest disclosure

The authors declared no conflicts of interest.

Funding

This work was granted by the Seoul National University Bundang Hospital research fund (06-2020-0200).

References

1. Hwang H, Chung YJ, Lee SR, et al. Clinical evaluation and management of endometriosis: guideline for Korean patients from Korean Society of Endometriosis. *Obstet Gynecol Sci*. 2018;61(5):553-564. [\[CrossRef\]](#)
2. Eskenazi B, Warner ML. Epidemiology of endometriosis. *Obstet Gynecol Clin North Am*. 1997;24(2):235-258. [\[CrossRef\]](#)
3. Fauconnier A, Fritel X, Chapron C. Endometriosis and pelvic pain: epidemiological evidence of the relationship and implications. *Gynecol Obstet Fertil*. 2009;37(1):57-69. [\[CrossRef\]](#)
4. Jee BC. Efficacy of ablation and sclerotherapy for the management of ovarian endometrioma: a narrative review. *Clin Exp Reprod Med*. 2022;49(2):76-86. [\[CrossRef\]](#)
5. Chapron C, Vercellini P, Barakat H, Vieira M, Dubuisson JB. Management of ovarian endometriomas. *Hum Reprod Update*. 2002;8(6):591-597. [\[CrossRef\]](#)
6. Han K, Seo SK, Kim MD, et al. Catheter-directed sclerotherapy for ovarian endometrioma: short-term outcomes. *Radiology*. 2018;289(3):854-859. [\[CrossRef\]](#)
7. Koo JH, Lee I, Han K, et al. Comparison of the therapeutic efficacy and ovarian reserve between catheter-directed sclerotherapy and surgical excision for ovarian endometrioma. *Eur Radiol*. 2021;31(1):543-548. [\[CrossRef\]](#)
8. Lee JK, Ahn SH, Kim HI, et al. Therapeutic efficacy of catheter-directed ethanol sclerotherapy and its impact on ovarian reserve in patients with ovarian endometrioma at risk of decreased ovarian reserve: a preliminary study. *J Minimally Invasive Gynecol*. 2022;29(1):317-323. [\[CrossRef\]](#)
9. Choi SH, Kim S, Lee SW, et al. Recurrence, reoperation, pregnancy rates, and risk factors for recurrence after ovarian endometrioma surgery: long-term follow-up of 756 women. *Yonsei Med J*. 2023;64(3):204-212. [\[CrossRef\]](#)
10. Cohen A, Almog B, Tulandi T. Sclerotherapy in the management of ovarian endometrioma: systematic review and meta-analysis. *Fertil Steril*. 2017;108(1):117-124. [\[CrossRef\]](#)
11. Sanchez AM, Viganò P, Somigliana E, Panina-Bordignon P, Vercellini P, Candiani M. The distinguishing cellular and molecular features of the endometriotic ovarian cyst: from pathophysiology to the potential endometrioma-mediated damage to the ovary. *Hum Reprod Update*. 2014;20:217-230. [\[CrossRef\]](#)
12. Muzii L, Di Tucci C, Di Felicianantonio M, et al. Antimüllerian hormone is reduced in the presence of ovarian endometriomas: a systematic review and meta-analysis. *Fertil Steril*. 2018;110(5):932-940. [\[CrossRef\]](#)
13. Hue H, Kim S, Choi J, et al. Previous ovarian surgery increases the risk of tubal factor infertility. *Clin Exp Obstet Gynecol*. 2020;47(1):84-88. [\[CrossRef\]](#)
14. Lee D, Kim SK, Lee JR, Jee BC. Management of endometriosis-related infertility: considerations and options. *Clin Exp Reprod Med*. 2020;47(1):1-11. [\[CrossRef\]](#)
15. Ata B, Turkgeldi E, Seyhan A, Urman B. Effect of hemostatic method on ovarian reserve following laparoscopic endometrioma excision; comparison of suture, hemostatic sealant, and bipolar desiccation. A systematic review and meta-analysis. *J Minim Invasive Gynecol*. 2015;22(3):363-372. [\[CrossRef\]](#)
16. Guo SW. Recurrence of endometriosis and its control. *Hum Reprod Update*. 2009;15(4):441-461. [\[CrossRef\]](#)
17. García-Tejedor A, Castellarnau M, Ponce J, Fernández ME, Burdio F. Ethanol sclerotherapy of ovarian endometrioma: A safe and effective minimal invasive procedure. Preliminary results. *Eur J Obstet Gynecol Reprod Biol*. 2015;187:25-29. [\[CrossRef\]](#)
18. Hsieh CL, Shiau CS, Lo LM, Hsieh TT, Chang MY. Effectiveness of ultrasound-guided aspiration and sclerotherapy with 95% ethanol for treatment of recurrent ovarian endometriomas. *Fertil Steril*. 2009;91(6):2709-2713. [\[CrossRef\]](#)