



Comparison of three-tesla magnetic resonance imaging with pathology in detecting deep myometrial invasion in endometrial cancer and revealing causes of discrepancy

Murat Ağırlar¹
 İlkey Çamlıdağ²
 Murat Danacı²

¹Çarşamba State Hospital, Clinic of Radiology,
Samsun, Türkiye

²Ondokuz Mayıs University Faculty of Medicine,
Department of Radiology, Samsun, Türkiye

PURPOSE

To evaluate the accuracy of three-tesla (3T) magnetic resonance imaging (MRI) in determining deep myometrial invasion (DMI) in endometrial cancer (EC) cases and to reveal possible causes of discrepancy.

METHODS

Patients with EC who underwent preoperative pelvic MRI examination at a tertiary hospital were independently and blindly reviewed for DMI by two radiologists with differing levels of expertise. On MRI, the invasion of the endometrial mass into the myometrium was defined as superficial or deep (<50% or ≥50%) and was compared with the gold standard pathology reports, evaluated using the same criteria. Cases with discrepancies between MRI and pathology were re-evaluated, and the causes of the discrepancies were identified.

RESULTS

A total of 226 patients were included. The sensitivity, specificity, positive predictive value, negative predictive value, and accuracy of MRI in detecting DMI were calculated as 77%, 93%, 84%, 88%, and 87%, respectively. In cases where radiology and pathology results were incompatible, expansile masses were found in 38%, myomas located near the lesion in 27%, masses located in the uterine horn in 21%, and in 14%, a specific cause explaining the error could not be identified.

CONCLUSION

MRI is the definitive diagnostic method for determining DMI. Awareness of these causes of discrepancy in MRI reporting can increase the value of the examination and contribute to patient management.

CLINICAL SIGNIFICANCE

This study highlights that 3T MRI has a high accuracy (87%) in detecting DMI in EC and demonstrates that analyzing misinterpretations can enhance reliability in patient management.

KEYWORDS

Causes of discrepancy, deep myometrial invasion, diagnostic accuracy, endometrial carcinoma, magnetic resonance imaging

Corresponding author: Murat Ağırlar

E-mail: dr.muratagirlar@gmail.com

Received 28 February 2025; revision requested 23 March 2025; last revision received 11 June 2025; accepted 23 June 2025.



Epub: 21.07.2025

Publication date: 04.05.2026

DOI: 10.4274/dir.2025.253306

Endometrial cancer (EC) is the most common gynecological cancer in developed countries. The majority of cases occur in individuals aged between 60 and 70 years.¹⁻³ EC is categorized into two histopathological subtypes: type 1 (80%–85%) and type 2 (10%–15%). Type 1 is estrogen-dependent and primarily affects younger women in the premenopausal or perimenopausal period. It consists of grade 1–2 endometrioid adenocarcinomas. In contrast, type 2 EC affects older women in the postmenopausal period. Histologically, it includes grade 3

You may cite this article as: Ağırlar M, Çamlıdağ İ, Danacı M. Comparison of three-tesla magnetic resonance imaging with pathology in detecting deep myometrial invasion in endometrial cancer and revealing causes of discrepancy. *Diagn Interv Radiol.* 2026;32(3):242-248.

endometrioid adenocarcinomas and other rare subtypes.^{4,7} Approximately 67% of patients present with early-stage disease, and at this stage, the 5-year survival rate is 81%.⁸ The prognosis depends on several factors, including histological type and grade, deep myometrial invasion (DMI), cervical invasion, and lymphovascular invasion.

The International Federation of Gynecology and Obstetrics (FIGO) classification system used for staging EC is a surgical staging procedure involving total hysterectomy with bilateral salpingo-oophorectomy, along with a thorough examination of the omentum, peritoneum, and intra-abdominal contents. Magnetic resonance imaging (MRI) is not included in the formal staging system for EC; however, it plays a critical role in treatment planning and determining the most appropriate initial therapy.³ According to the classification updated by FIGO in 2023, DMI—defined as infiltration of 50% or more of the myometrium—is one of the criteria for stage IB EC. Additionally, a new stage IC category was introduced for aggressive histological subtypes, provided the tumor is confined to a polyp or the endometrium. Accordingly, the prognostic significance of DMI, a key factor in EC treatment and outcomes, has increased.^{9–12} DMI is a predictor of extrauterine disease and lymph node metastasis. Lymph node metastasis occurs in 30% of DMI cases, compared with only 5% in cases of superficial myometrial invasion (SMI).^{13,14}

In this context, lymph node metastasis—the strongest predictor of recurrence—is associated with DMI. Lymphadenectomy may be considered for grade 3 and other high-risk EC cases. Additionally, in patients with grade

1–2 tumors, lymph node dissection may be considered if DMI is present.¹⁵ However, it has been shown that systematic lymphadenectomy does not improve overall survival in early-stage disease. Moreover, lymphadenectomy may lead to complications such as lymphedema and lymphocysts; therefore, it should be avoided in low-risk patients.^{16,17} Identification of DMI through preoperative MRI assessment is thus clinically substantial for surgical planning.

In the literature, studies comparing MRI with intraoperative frozen section evaluation and postoperative pathological evaluation for determining DMI have reported high sensitivity, specificity, and accuracy for MRI, supporting its use as a superior diagnostic tool. MRI is the recommended imaging modality for preoperative radiological evaluation in EC.^{9,16,18–20} However, to our knowledge, no studies have specifically focused on the underlying causes of diagnostic errors in MRI.

One objective of this study is to evaluate the sensitivity, specificity, and accuracy of three-tesla (3T) MRI in detecting DMI by comparing its findings with postoperative pathological evaluations in cases of EC. Another goal is to identify the causes of discordant results by re-evaluating cases with incorrect radiological assessments through a secondary review.

Methods

Patient selection

This retrospective study was approved by the Ondokuz Mayıs University Clinical Research Ethics Committee (protocol number: 2022/450, date: 13.10.2022). The requirement for informed consent was waived due to the retrospective nature of the study. Patients with a pathological diagnosis of EC who underwent pelvic staging MRI between January 2016 and June 2022, and who subsequently underwent hysterectomy as part of surgery following the MRI, were eligible for inclusion (n = 240).

Cases with tumors extending beyond the uterus and serosa (n = 8) and those with artifacts hindering proper evaluation due to intestinal peristalsis or hip prosthesis (n = 5) were excluded. Additionally, cases in which the interval between MRI and surgery exceeded 1 month (n = 2) were also excluded. The remaining patients underwent surgery within 1 month after MRI. The study workflow is summarized in the flowchart (Figure 1).

Multiparametric magnetic resonance imaging protocol

To reduce artifacts caused by peristalsis, the patients were instructed to fast for 6

Main points

- Three-tesla magnetic resonance imaging (MRI) has a high accuracy (87%) in detecting deep myometrial invasion in endometrial cancer (EC).
- Identifying misinterpretations in imaging can improve diagnostic reliability and enhance patient management.
- MRI-based assessment of myometrial invasion can aid in preoperative planning, potentially reducing unnecessary extensive surgeries.
- Understanding the limitations and pitfalls of MRI interpretation is crucial for radiologists and clinicians in optimizing patient outcomes.
- A systematic approach to image analysis and error reduction can lead to better decision-making in EC management.

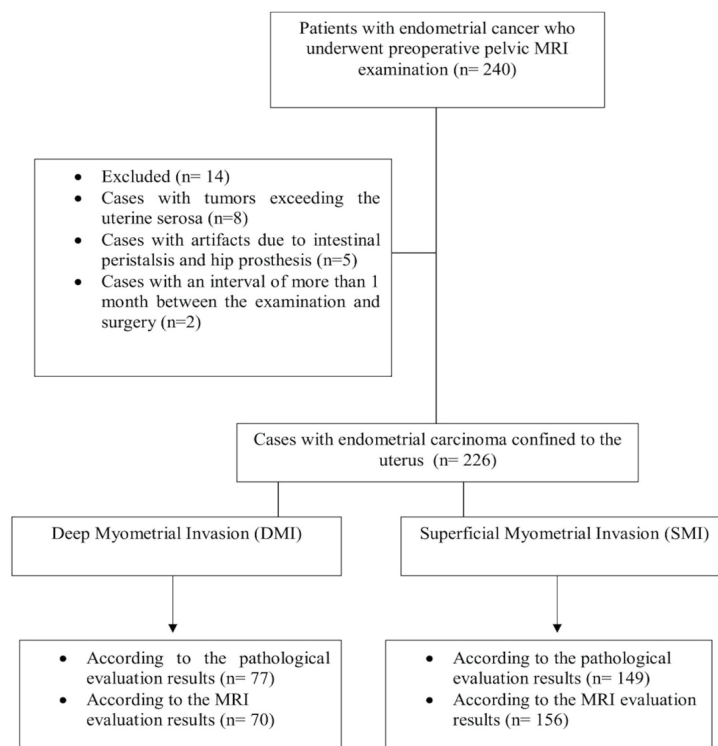


Figure 1. Flowchart of the study. MRI, magnetic resonance imaging.

hours and to empty their bladders approximately half an hour before the examination. All examinations were performed using a 3T MRI scanner (Philips Ingenia, Netherlands) with a 16-channel torso coil. The patients were scanned in the supine position. High-resolution oblique axial and coronal images, sagittal T2-weighted images, axial T1-weighted images, axial diffusion-weighted images, and dynamic contrast-enhanced 3D T1-weighted images were obtained. For contrast-enhanced imaging, 0.1 mmol/kg of gadoteric acid was intravenously injected at a rate of 2 mL/s using a power injector, and images were acquired at 30, 60, 90, and 120 seconds. Imaging parameters are summarized in Table 1.

Image analysis

All images were independently analyzed by an abdominal radiologist with 20 years of experience and a general radiologist with 5 years of experience in abdominal/pelvic MRI interpretation. Both were blinded to the histopathological results. Preoperative MRI staging was performed according to the revised 2023 FIGO criteria. The degree of myometrial invasion was primarily assessed on high-resolution T2-weighted images obtained at a specific angle. Correlation was then made with non-angled diffusion-weighted imaging and contrast-enhanced series. The component of the endometrial lesion invading the myometrium was measured in millimeters and normalized to the myometrial thickness (Figure 2). It was documented whether myometrial invasion was $<50\%$ or $\geq 50\%$. During comparison of MRI results with histopathological findings, cases with discordant assessments were re-evaluated jointly by the two radiologists, and reasons for discrepancies were identified.

Histopathological examination

All pathological examinations were performed by an expert gynecological pathologist. Diagnoses were determined according to the 2014 World Health Organization classification of tumors of the uterine corpus. In the hysterectomy specimens, the depth of tumor invasion into the myometrium and the corresponding myometrial thickness were measured microscopically in a manner consistent with MRI assessment. DMI was considered present when the depth of invasion was $\geq 50\%$.

Statistical analysis

Statistical analyses were performed using the Statistical Package for the Social Sciences version 22.0 (IBM, New York, USA). Descriptive statistics were expressed as numbers and percentages for categorical variables and as mean, standard deviation, minimum, and maximum for continuous variables.

The chi-square test was used to assess differences between categorical variables. The sensitivity, specificity, positive predictive value (PPV), negative predictive value (NPV), and accuracy of MRI in detecting the depth of myometrial invasion were calculated. A P value of <0.05 was considered statistically significant.

Results

A total of 226 patients with EC were eligible for the study. The mean age of the patients was 60 ± 10 years (range: 36–94 years). The average size of mass lesions was 27 ± 14 mm (range: 10–92 mm). Following histopathological evaluation, 25% of patients had endometrial adenocarcinoma, endometrioid type, grade 1 ($n = 58$); 42% had grade 2 ($n = 94$); 11% had grade 3 ($n = 24$); and 22%

had other less commonly observed histopathological diagnoses ($n = 50$).

According to EC types, the mean age of 152 patients (67%) with type 1 was 58 ± 9.5 years, and the mean age of 74 patients (33%) with type 2 was 64 ± 9.7 years.

In type 1 EC, 24.4% ($n = 38$) of patients had DMI and 75.6% ($n = 114$) had SMI. In type 2 EC, 56.6% ($n = 43$) had DMI and 43.4% ($n = 33$) had SMI. The difference between type 1 and type 2 with regard to DMI was statistically significant ($P < 0.001$). There was no statistically significant difference between type 1 and type 2 clinical classifications regarding discordant results between MRI and histopathology in detecting DMI ($P = 0.307$).

According to histopathological examination, DMI was detected in 77 patients (34%), whereas 149 patients (66%) had SMI.

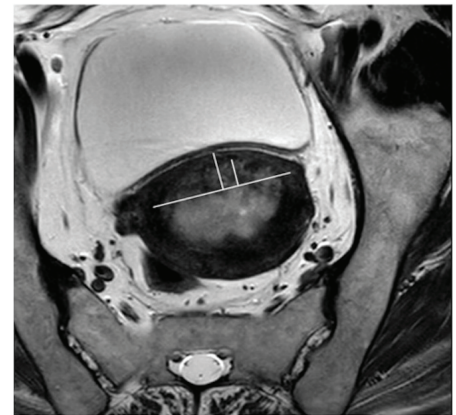


Figure 2. The long vertical line perpendicular to the plane and parallel to the inner border of the myometrium illustrates the thickness of the myometrium, whereas the short line represents the depth of extension of the mass into the myometrium in millimeters. A ratio of 0.5 or greater between the depth of extension and the thickness of the myometrium indicates deep myometrial invasion.

Table 1. Magnetic resonance imaging protocol for imaging of endometrial cancer

	TR (ms)	TE (ms)	ST (mm)	SS (mm)	FOV (mm)	FA (degrees)	Matrix	b value (s/mm ²)
T2 TSE sagittal	3000–5000	90	5	1	300	90	300 × 264	
T2 TSE oblique coronal	3000–5000	90	3	0.3	200	90	308 × 252	
T2 TSE oblique axial	3000–5000	90	3	0.3	200	90	308 × 253	
mDIXON–IP/OP axial	3.2	TE1: 1.12 TE2: 2	3	-1.5	350	none	196 × 144	
DWI axial	5704	77	5	0	375	none	124 × 106	0, 200, 800
mDIXON axial (contrast-enhanced, fat-suppressed)*	3.2	TE1: 1.13 TE2: 2	3	-1.5	350	none	200 × 165	

*0.1 mmol/kg gadoteric acid was administered intravenously with a power injector at a rate of 2 mL/sec.

TR, recovery time; TE, echo time; ST, slice thickness; SS, slice spacing; FOV, field of view; FA, flip angle; TSE, turbo spin echo; IP, in-phase; OP, out-of-phase; DWI, diffusion-weighted imaging.

On MRI, 70 patients (31%) were found to have DMI, whereas 156 patients (69%) had SMI. In 11 patients with SMI on histopathological evaluation, MRI was interpreted as DMI. In 18 patients with DMI identified on histopathological evaluation, MRI was incorrectly interpreted as not having DMI, leading to understaging (Table 2). MRI had a sensitivity of 77%, specificity of 93%, PPV of 84%, NPV of 88%, and an accuracy of 87% in detecting DMI.

In 197 of 226 patients evaluated with MRI, the results were compatible with pathology in terms of DMI. In 29 patients with discrepant results, we investigated the causes of discrepancy through secondary retrospective evaluation (Table 3).

In 11 patients with incorrect staging on MRI, mass lesions were observed, causing thinning of the myometrium due to expansion. As a result, six of these patients were understaged and five were overstaged (Figure 3).

Eight patients had fibroids located in contact with or within 1 cm of the endometrial mass. Uterine fibroids disrupted the homogeneous structure of the myometrium, making it difficult to determine the extent of the lesion's invasion. As a result, six patients were understaged and two were overstaged (Figure 4).

In 6 patients, the mass lesions were located in the uterine horn. The thinning of the myometrium at the level of the uterine horn made it difficult to determine the depth of myometrial invasion. As a result, three

patients were understaged and three were overstaged (Figure 5).

In MRI evaluations of 4 patients where misclassification occurred, we could not identify any substantial factor that might have caused the discrepancy. We classified the cause in this group as "personal factors" (Figure 6).

We analyzed the frequency of previously identified factors leading to erroneous eval-

uations in the 197 cases where radiology and pathology results were consistent. Expansive masses were observed in 19 cases, masses near the uterus in 8 cases, and masses in the uterine horn in 5 cases. The frequencies of these findings were statistically significant in the group with erroneous evaluations ($P < 0.001$). The interobserver agreement in MRI evaluation was assessed using Cohen's kappa coefficient, which was calculated as 0.831, indicating excellent agreement.

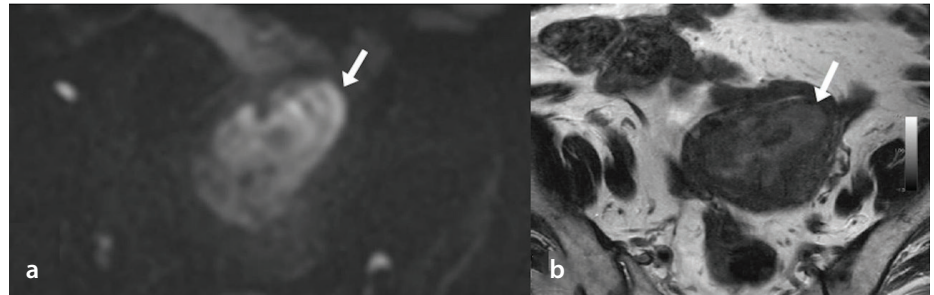


Figure 3. In a 69-year-old patient with a mixed tumor consisting of grade 1 endometrial adenocarcinoma of the endometrioid type and undifferentiated carcinoma, a mass lesion causing expansion in the uterine cavity is observed on MRI (white arrows). On DWI, the mass shows high signal intensity (a), whereas in T2-weighted oblique axial sections (b), it shows slightly higher signal intensity than the muscle. The lesion was concluded to have SMI, but pathological evaluation revealed DMI. MRI, magnetic resonance imaging; DWI, diffusion-weighted imaging; SMI, superficial myometrial invasion; DMI, deep myometrial invasion.

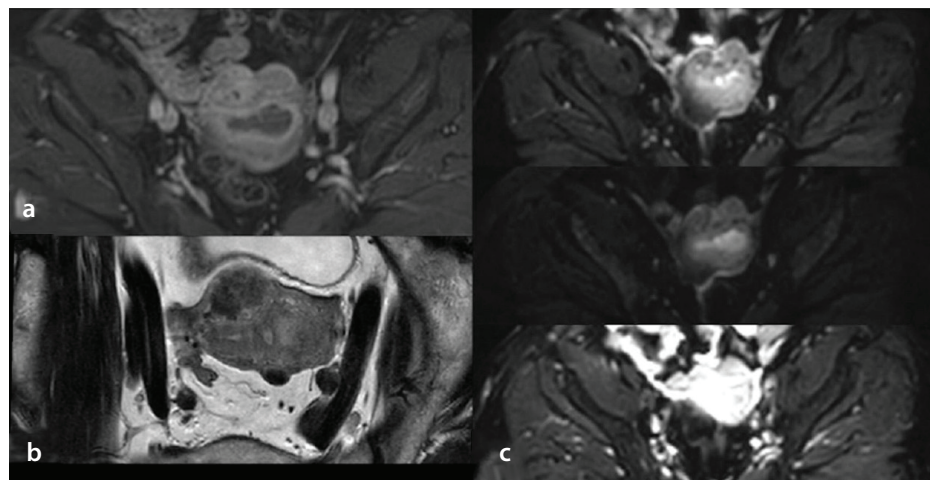


Figure 4. In a 63-year-old patient with a pathological diagnosis of grade 1 endometrial adenocarcinoma of the endometrioid type, the contrast-enhanced series (a) shows a weakly enhancing endometrial mass relative to the myometrium in the arterial phase and heterogeneous subserosal myomas at the uterine fundus. On T2-weighted oblique axial series (b), a mildly hyperintense mass lesion is observed; on DWI (c), a high signal intensity mass is seen. Based on MRI evaluation, the lesion was concluded to have DMI; however, the pathological evaluation showed SMI. DMI, deep myometrial invasion; DWI, diffusion-weighted imaging; MRI, magnetic resonance imaging; SMI, superficial myometrial invasion.

Table 2. Comparison of magnetic resonance imaging with pathology in the detection of deep myometrial invasion

		Pathology		
		SMI	DMI	Total
MRI	SMI	138	18	156
	DMI	11	59	70
	Total	149	77	226

MRI, magnetic resonance imaging; SMI, superficial myometrial invasion; DMI, deep myometrial invasion.

Table 3. Causes of discrepancy between magnetic resonance imaging and pathology with regard to deep myometrial invasion in patients with endometrial cancer

Causes	Understaged	Overstaged	Total
Expansile lesions	6	5	11
Myoma associated with mass	6	2	8
Mass located in the uterine horn	3	3	6
Personal factors	3	1	4

Discussion

In this study, which was conducted with EC cases, we compared MRI and histopathology results for determining DMI and successfully identified DMI with MRI in most patients, consistent with other studies in the literature.

In most cases where we misidentified myometrial invasion on MRI, there were mass lesions causing expansion. A mass lesion expanding within the uterine cavity results in thinning of the myometrium. In thin myometrium, it is expected that there will be a higher likelihood of measurement errors than

in the normally thickened myometrium. In other studies, a frequently mentioned factor contributing to DMI evaluation errors is the presence of an expansile mass. Our review of the literature also identified postmenopausal atrophic myometrium as a potential error factor in some studies. In our cases, however, the error factors did not include isolated atrophic myometrium.

Lesions located in the uterine horn have also been identified as error factors in other studies. Myometrial thickness is low at the horn level, and its flexibility is limited. Therefore, even small masses can cause expansion

and may hinder accurate evaluation. Subserosal or intramural myomas can disrupt the homogeneous structure and zonal anatomy of the myometrium, leading to possible mismeasurement of myometrial thickness and incorrect determination of DMI. Although some studies have cited the presence of adenomyosis as an error factor, it did not appear in the cases where we made incorrect staging.^{4,6,21-25}

In a recent study, Liyanage et al.²⁶ analyzed 235 women with EC and reported that MRI detected DMI with an overall accuracy of 86%, sensitivity of 72%, and specificity of 91%. They also showed that the presence of subserosal or intramural leiomyomas or adenomyosis reduced sensitivity while leaving specificity essentially unchanged.

In the literature, apart from the present study, there are numerous studies comparing preoperative MRI with postoperative histopathological assessment in cases of EC in terms of DMI. In these studies, the sensitivity of MRI in detecting DMI ranged from 50% to 91%, specificity from 72% to 94%, accuracy from 77% to 93%, PPV from 63% to 92%, and NPV from 81% to 92%.^{9,16,19,27-31} In our study, although the sensitivity rate is lower than in some studies, we observed high specificity and accuracy rates.

In the 2023 revision of the FIGO staging system, stage 1 was further detailed, and additional subcategories were introduced. In this classification, both the presence of DMI and the aggressiveness of the histological subtype are taken into consideration.¹² In our study, we found that aggressive histological subtypes did not negatively affect the accuracy of MRI assessments.

We demonstrated the high accuracy of MRI in determining myometrial invasion in EC cases, consistent with previous studies. We believe that considering the error factors identified in this study during MRI evaluation can enhance the reliability of the examination. Accordingly, recognizing MRI-pathology mismatches is essential: overstaging can expose patients to unnecessary lymphadenectomy, whereas understaging may delay adjuvant therapy, potentially affecting survival. Since DMI is an important marker for determining the risk of lymph node metastasis, it can assist in deciding whether lymphadenectomy should be performed prior to surgery. This approach may help prevent unnecessary lymphadenectomy and its associated complications.

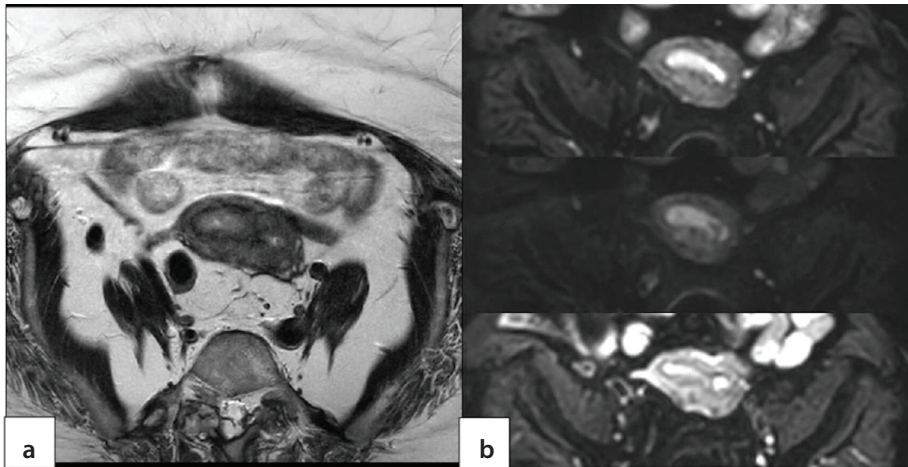


Figure 5. In a 54-year-old patient with a pathological diagnosis of grade 2 endometrial adenocarcinoma of the endometrioid type, a mildly hyperintense mass lesion is observed on T2-weighted oblique axial series (a), and a high signal intensity mass is seen on diffusion-weighted imaging (b), located in the right uterine horn and causing expansion at this level. Based on the MRI examination, the lesion was interpreted as not having DMI. However, the pathological evaluation revealed the presence of DMI. MRI, magnetic resonance imaging; DMI, deep myometrial invasion.

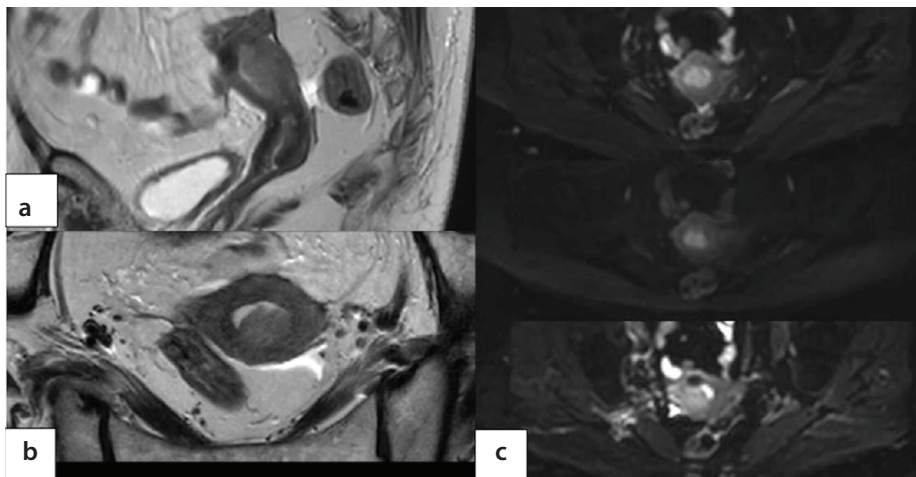


Figure 6. In a 64-year-old patient with a pathological diagnosis of high-grade mixed carcinoma, a mildly hyperintense endometrial mass lesion is observed on T2-weighted sagittal (a) and oblique axial (b) series, and it appears as a high signal intensity lesion on diffusion-weighted imaging (c). Based on the MRI examination, the lesion was concluded not to exhibit DMI. However, pathological evaluation confirmed DMI. No specific factors were identified on MRI that could explain the incorrect assessment. MRI, magnetic resonance imaging; DMI, deep myometrial invasion.

In the literature, several studies have investigated the success of MRI in determining DMI, and as we mentioned in our article, various factors contributing to errors have been discussed. However, we did not find any other studies that specifically analyzed the causes of MRI errors and provided statistical data on these factors. Based on our literature review, our study includes one of the largest patient groups, which we consider a strength.

Our study has some limitations. First, it is a retrospective study. Second, in our MRI protocol, T2-weighted series were acquired in oblique axial and coronal views, but diffusion-weighted and dynamic contrast-enhanced series were not obtained in oblique planes. This may be considered a limitation, as it reduces the contribution of contrast-enhanced and diffusion-weighted sequences in determining DMI.

In conclusion, MRI has high accuracy in determining DMI in EC cases. However, erroneous interpretation of myometrial invasion may occur due to large expansile lesions, accompanying large myomas, and lesions located in the horn. We think that these factors should be mentioned in the radiology report when present, as they may act as misleading factors in evaluating DMI. This would enable more reliable treatment planning for the patient based on MRI findings.

Footnotes

Conflict of interest disclosure

The authors declared no conflicts of interest.

References

- Faria SC, Devine CE, Rao B, Sagebiel T, Bhosale P. Imaging and staging of endometrial cancer. *Semin Ultrasound CT MR*. 2019;40(4):287-294. [\[Crossref\]](#)
- Cubo-Abert M, Díaz-Feijoo B, Bradbury M, et al. Diagnostic performance of transvaginal ultrasound and magnetic resonance imaging for preoperative evaluation of low-grade endometrioid endometrial carcinoma: prospective comparative study. *Ultrasound Obstet Gynecol*. 2021;58(3):469-475. [\[Crossref\]](#)
- Maheshwari E, Nougaret S, Stein EB, et al. Update on MRI in evaluation and treatment of endometrial cancer. *Radiographics*. 2022;42(7):2112-2130. [\[Crossref\]](#)
- Dokter E, Anderson L, Cho SM, et al. Radiology-pathology correlation of endometrial carcinoma assessment on magnetic resonance imaging. *Insights Imaging*. 2022;13(1):80. [\[Crossref\]](#)
- Meissnitzer M, Forstner R. MRI of endometrium cancer - how we do it. *Cancer Imaging*. 2016;16:11. [\[Crossref\]](#)
- Otero-García MM, Mesa-Álvarez A, Nikolic O, et al. Role of MRI in staging and follow-up of endometrial and cervical cancer: pitfalls and mimickers. *Insights Imaging*. 2019;10(1):19. [\[Crossref\]](#)
- Amant F, Mirza MR, Koskas M, Creutzberg CL. Cancer of the corpus uteri. *Int J Gynaecol Obstet*. 2018;143(Suppl 2):37-50. [\[Crossref\]](#)
- Makker V, MacKay H, Ray-Coquard I, et al. Endometrial cancer. *Nat Rev Dis Primers*. 2021;7(1):88. [\[Crossref\]](#)
- Yin XH, Jia HY, Shi M, Wu H, Li YM. Magnetic resonance imaging for detection of depth of myometrial invasion and cervical invasion in patients with endometrial carcinoma. *Int J Clin Exp Med*. 2015;8(10):19501-19505. [\[Crossref\]](#)
- Aracki-Trenkic A, Stojanov D, Petric A, Benedeto-Stojanov D, Trenkic M, Ignjatovic J. The role of magnetic resonance imaging in the evaluation of endometrial carcinoma. *J BUON*. 2016;21(3):542-548. [\[Crossref\]](#)
- Berek JS, Matias-Guiu X, Creutzberg C, et al. FIGO staging of endometrial cancer: 2023. *Int J Gynaecol Obstet*. 2023;162(2):383-394. [\[Crossref\]](#)
- Avesani G, Bonatti M, Venkatesan AM, Nougaret S, Sala E. RadioGraphics update: 2023 FIGO staging system for endometrial cancer. *Radiographics*. 2024;44(7):e240084. [\[Crossref\]](#)
- Larson DM, Connor GP, Broste SK, Krawisz BR, Johnson KK. Prognostic significance of gross myometrial invasion with endometrial cancer. *Obstet Gynecol*. 1996;88(3):394-398. [\[Crossref\]](#)
- Iitsuka C, Asami Y, Hirose Y, et al. Preoperative magnetic resonance imaging versus intraoperative frozen section diagnosis for predicting the deep myometrial invasion in endometrial cancer: our experience and literature review. *J Obstet Gynaecol Res*. 2021;47(9):3331-3338. [\[Crossref\]](#)
- Ota T, Tsuboyama T, Onishi H, et al. Diagnostic accuracy of MRI for evaluating myometrial invasion in endometrial cancer: a comparison of MUSE-DWI, rFOV-DWI, and DCE-MRI. *Radiol Med*. 2023;128(6):629-643. [\[Crossref\]](#)
- Karataşlı V, Çakır I, Şahin H, Ayaz D, Sancı M. Can preoperative magnetic resonance imaging replace intraoperative frozen sectioning in the evaluation of myometrial invasion for early-stage endometrial carcinoma? *Ginekol Pol*. 2019;90(3):128-133. [\[Crossref\]](#)
- Wright JD, Huang Y, Burke WM, et al. Influence of lymphadenectomy on survival for early-stage endometrial cancer. *Obstet Gynecol*. 2016;127(1):109-118. [\[Crossref\]](#)
- Zamani F, Goodarzi S, Hallaji F, et al. Diagnostic value of pelvic MRI for assessment of the depth of myometrial invasion and cervical involvement in endometrial cancer: comparison of new versus old FIGO staging. *Iran J Radiol*. 2012;9(4):202-208. [\[Crossref\]](#)
- Cade TJ, Quinn MA, McNally OM, Neesham D, Pyman J, Dobrotwir A. Predictive value of magnetic resonance imaging in assessing myometrial invasion in endometrial cancer: is radiological staging sufficient for planning conservative treatment? *Int J Gynecol Cancer*. 2010;20(7):1166-1169. [\[Crossref\]](#)
- Rei M, Rodrigues I, Condeço P, Igreja F, Verissimo C, Mendinhos G. Endometrial cancer: preoperative versus intraoperative staging. *J Gynecol Obstet Hum Reprod*. 2019;101647. [\[Crossref\]](#)
- Hricak H, Stern JL, Fisher MR, Shapeero LG, Winkler ML, Lacey CG. Endometrial carcinoma staging by MR imaging. *Radiology*. 1987;162(2):297-305. [\[Crossref\]](#)
- Andreano A, Rechichi G, Rebora P, Sironi S, Valsecchi MG, Galimberti S. MR diffusion imaging for preoperative staging of myometrial invasion in patients with endometrial cancer: a systematic review and meta-analysis. *Eur Radiol*. 2014;24(6):1327-1338. [\[Crossref\]](#)
- Kinkel K, Forstner R, Danza FM, et al. Staging of endometrial cancer with MRI: guidelines of the European Society of Urogenital Imaging. *Eur Radiol*. 2009;19(7):1565-1574. [\[Crossref\]](#)
- Lee JH, Dubinsky TJ, Andreotti RF, et al. ACR appropriateness Criteria(R) pretreatment evaluation and follow-up of endometrial cancer of the uterus. *Ultrasound Q*. 2011;27(2):139-145. [\[Crossref\]](#)
- Nougaret S, Lakhman Y, Vargas HA, et al. From staging to prognostication: achievements and challenges of MR imaging in the assessment of endometrial cancer. *Magn Reson Imaging Clin N Am*. 2017;25(3):611-633. [\[Crossref\]](#)
- Liyanage A, Cardoza S, Kasabia D, Moore H. Accuracy of MRI in predicting deep myometrial invasion in endometrial cancer and the influence of leiomyoma, adenomyosis and the microcystic elongated and fragmented tumour pattern. *J Med Imaging Radiat Oncol*. 2024;68(3):235-242. [\[Crossref\]](#)
- Chung HH, Kang SB, Cho JY, et al. Accuracy of MR imaging for the prediction of myometrial invasion of endometrial carcinoma. *Gynecol Oncol*. 2007;104(3):654-659. [\[Crossref\]](#)

28. Cabrita S, Rodrigues H, Abreu R, et al. Magnetic resonance imaging in the preoperative staging of endometrial carcinoma. *Eur J Gynaecol Oncol.* 2008;29(2):135-137. [\[Crossref\]](#)
29. Sato S, Itamochi H, Shimada M, et al. Preoperative and intraoperative assessments of depth of myometrial invasion in endometrial cancer. *Int J Gynecol Cancer.* 2009;19(5):884-887. [\[Crossref\]](#)
30. McComiskey MH, McCluggage WG, Grey A, Harley I, Dobbs S, Nagar HA. Diagnostic accuracy of magnetic resonance imaging in endometrial cancer. *Int J Gynecol Cancer.* 2012;22(6):1020-1025. [\[Crossref\]](#)
31. Wu CY, Tai YJ, Shih IL, et al. Preoperative magnetic resonance imaging predicts clinicopathological parameters and stages of endometrial carcinomas. *Cancer Med.* 2022;11(4):993-1004. [\[Crossref\]](#)