













Copyright© Author(s) - Available online at dirjournal.org.  
Content of this journal is licensed under a Creative Commons  
Attribution-NonCommercial 4.0 International License.

# Gastrostomy tube check radiographs: performance of an alternative diagnostic exam

 Muhammad Y. Hameed<sup>1</sup>  
 Charles A. James<sup>2</sup>  
 Kevin Wong<sup>2</sup>  
 Paul S. Lewis<sup>2</sup>  
 Paula K. Roberson<sup>3</sup>  
 Kelli R. Schmitz<sup>4</sup>  
 Sateesh Jayappa<sup>2</sup>  
 Amy C. Rowell<sup>2</sup>  
 Marcene McVay-Gillam<sup>5</sup>  
 Mary B. Moore<sup>2</sup>

<sup>1</sup>University of Arkansas for Medical Sciences, College of Medicine, Little Rock, USA

<sup>2</sup>University of Arkansas for Medical Sciences, Arkansas Children's Hospital, Department of Radiology, Little Rock, USA

<sup>3</sup>University of Arkansas for Medical Sciences, Department of Biostatistics, Little Rock, USA

<sup>4</sup>University of Arkansas for Medical Sciences, Arkansas Children's Northwest Hospital, Department of Radiology, Springdale, USA

<sup>5</sup>Arkansas Children's Northwest Hospital, Department of Surgery, Springdale, USA

Corresponding author: Charles A. James

E-mail: JamesCharlesA@uams.edu

Received 18 April 2025; revision requested 02 June 2025; accepted 27 July 2025.



Epub: 15.09.2025

Publication date: xx.xx.2025

DOI: 10.4274/dir.2025.253399

## PURPOSE

The traditional imaging exam to check a gastrostomy tube (G-tube) used fluoroscopy, which requires the presence of a radiologist. Evaluate the effectiveness of an alternative 2-view abdominal radiograph exam protocol instituted to replace the prior fluoroscopic G-tube contrast check exam and provide 24/7 coverage at 2 affiliated hospitals.

## METHODS

An alternative 2-view G-tube check radiograph exam following stratified contrast administration was introduced at 2 affiliated children's hospitals. Gastrostomy-tube radiograph exams performed between December 2019 and May 2022 at 2 affiliated hospitals were identified, and a retrospective chart review was performed to delineate exam test yield, accuracy, sensitivity, specificity, positive predictive value (PPV), and negative predictive value (NPV). Additional data collected included exam adherence to the protocol, 30-day adverse events, reporting time, and the years of experience of the reporting pediatric radiologist.

## RESULTS

A total of 227 exams were performed among 186 patients. The 2-view radiograph protocol was followed in 81.9% (186/227). Additional radiograph views were performed for 18.1% (41/227) of cases, and additional contrast volume for 9.3% (21/227) of cases. A fluoroscopic G-tube contrast check was requested for 7 of 13 indeterminate readings with high clinical suspicion. Following the reclassification of indeterminate exams based on clinical suspicion, exam performance results were as follows: test yield, 94.3%; accuracy, 97.8%; sensitivity, 90.0%; specificity, 98.2%; PPV, 69.2%; NPV, 99.5%. The 1 false negative exam required a second hospital visit 7 days after the initial exam to detect and correct G-tube malposition. Reporting time under 1 hour occurred in 79.7% (181/227). Delayed radiology reporting in 1 patient led to endoscopic confirmation of abnormal G-tube alignment. Furthermore, 5.7% (13/227) exams were reported as indeterminate, adding a median time delay of 40 minutes (interquartile range, 90). Indeterminate exam reporting did not correlate with the years of experience of the reporting pediatric radiologist ( $P = 0.189$ ). Reporting time over 1 hour occurred more often in the after-hours group ( $P = 0.032$ ).

## CONCLUSION

This alternative diagnostic exam performed well in terms of high test yield, accuracy, sensitivity, specificity, and NPV. The exam mostly followed protocol, allowed for the timely and safe resumption of G-tube use, and provided the remote coverage needed for a new satellite hospital.

## CLINICAL SIGNIFICANCE

This diagnostic radiograph exam replaced the on-site fluoroscopic exam as the initial imaging exam for G-tube checking in our pediatric population.

## KEYWORDS

Fluoroscopy, G-tube check, gastrostomy, pediatrics, radiographs

Shortages in the pediatric radiologist and technologist workforce in North America have increased the remote reading of diagnostic imaging exams.<sup>1,2</sup> Concurrently, healthcare leaders have demanded increased evening/overnight final reads of diagnostic imaging exams.<sup>3</sup> To avoid peritoneal leakage complications, imaging checks of a replaced or malfunctioning gastrostomy tube (G-tube) are often requested to ensure appropriate tube alignment prior to resuming tube use for hydration, nutrition, and medications. Imaging verification of G-tube alignment has traditionally been a fluoroscopic exam performed by an on-site pediatric radiologist. An alternative approach is a diagnostic abdominal radiograph exam following protocolized contrast administration.<sup>4</sup> An unpublished survey from the Society of Chiefs of Radiology at Children's Hospitals (SCORCH) in 2019 provided support for this alternative approach, but clinical validation is needed to support practice implementation. The following report describes our experience using a 2-view abdominal radiograph exam with stratified contrast administration for 2 affiliated children's hospitals, as the satellite hospital lacked after-hours radiologist availability for an on-site fluoroscopic exam.

## Methods

Institutional Review Board (IRB) approval (protocol number: 263194) was obtained to collect retrospective data of all G-tube abdominal radiograph exams performed using an alternative protocol between December 2019 through May 2022 at an established central children's hospital and a new satellite children's hospital with a shared Epic electronic health record (Epic Systems, Verona, WI, USA). Need for informed consent was waived by the IRB for this retrospective study. Both hospitals had pediatric radiology staff coverage during daytime hours; the satellite hospital lacked after-hours pediatric

radiologist or radiology resident coverage. Radiograph examinations ordered with the description "XR G-TUBE CHECK W CONTRAST ABD 2VW" were identified in a shared picture archiving and communications system (PACS, Fuji Synapse, FUJIFILM, Lexington, MA, USA); a Research Electronic Data Capture (REDCap, Vanderbilt University, Nashville, TN, USA) database was created. Study inclusion criteria comprised a completed radiograph exam for a G-tube check. Exclusion criteria were cancelled radiograph exams or the use of this radiograph exam for enteric tubes other than G-tubes [e.g., nasojejunum or gastrojejunostomy (GJ) tube] (Figure 1).

The radiograph exam protocol (Figure 2) was developed in consultation with physicians from the emergency department and pediatric surgery service; a collaborating radiology department supervisor ensured protocol understanding of the existing and new radiology technologists (RTs). Our approach included a 2-view abdominal radiograph exam following contrast administration [Cysto-Conray II, 17.2% (Guebert, Princeton, NJ, USA)] by the RT, stratified by patient age: 10 mL for patients under 1 year, 15 mL for 1–5 years, and 20 mL for patients over 5 years old.<sup>5</sup> A cross-table lateral radiograph (Figure 3a) was followed by a frontal radiograph with the patient in a right lateral decubitus position (Figure 3b). Upon exam completion, the RT contacted the pediatric radiologist covering the fluoroscopy work assignment or the on-call pediatric radiologist via a phone call, beeper page, or a Secure Chat message in Epic. The reviewing radiologist could request additional views and/or additional contrast as needed. Overnight radiology residents at the central hospital reviewed some exams

and provided a preliminary report note in Epic, which was subsequently reviewed by the reporting pediatric radiologist.

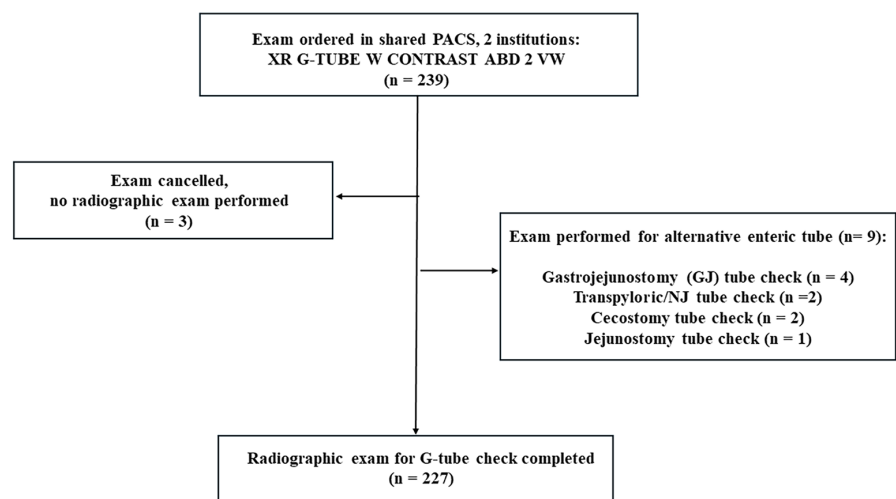
Report results were classified as positive (abnormal exam with abnormal G-tube retention component alignment, peritoneal air, or extraluminal contrast leakage; see Figure 4), negative (normal exam with normal intraluminal contrast flow and normal G-tube retention component alignment; see Figure 3), or indeterminate (equivocal G-tube retention component alignment or uncertainty of intraluminal contrast; Figure 5a). To determine exam sensitivity and specificity, indeterminate exams were reclassified based on clinical suspicion, a method suggested by several researchers.<sup>6,7</sup> Specifically, when an indeterminate exam was accompanied by low clinical suspicion of G-tube malposition/malfunction by the consulted pediatric surgery team or other referring service, no further imaging was performed, and the study was reclassified as a negative (normal) radiograph exam. When there was high clinical suspicion of G-tube malfunction (such as pain with G-tube use) by the consulted pediatric surgery team or requesting service, a fluoroscopic G-tube contrast check was requested, and the radiograph study was reclassified as a positive (abnormal) radiograph exam.

## Fluoroscopic exam protocol

For indeterminate radiograph exams with high clinical suspicion, a referring physician ordered a fluoroscopic G-tube contrast check, and the RT contacted the pediatric radiologist to perform an on-site exam. The pediatric radiologist traveled to the fluoroscopy suite from off-site or an on-site assignment

**Main points**

- Gastrostomy-tube (G-tube) check radiograph exam performance: test yield, 94.3%; accuracy, 97.8%; sensitivity, 90.0%; specificity, 98.2%; positive predictive value, 69.2%; negative predictive value, 99.5%.
- The alternative radiograph exam capably replaced fluoroscopy as the initial imaging exam for G-tube checking.
- Remote readings allowed for after-hours coverage in a satellite hospital 3 hours away, which lacked the presence of an on-site after-hours pediatric radiologist or radiology resident.



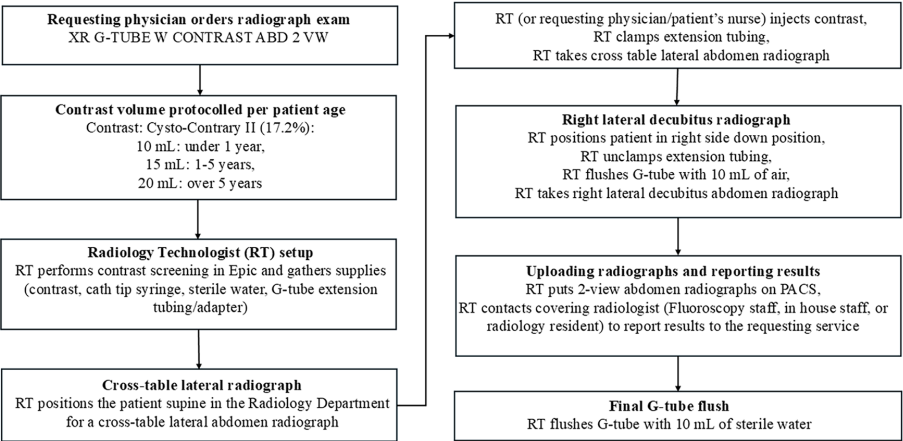
**Figure 1.** Study flowchart. PACS, picture archiving and communications system; XR, X-ray; G-TUBE, gastrostomy tube; W, with; ABD, abdomen; VW, view; GJ, gastrojejunostomy; NJ, nasojejunum.

and protocolled the exam contrast in Epic [favoring a water-soluble contrast: Cysto-Conray II, 17.2%, or Cystografin-Dilute, 18% (Bracco Diagnostics, Princeton, NJ, USA)]. This pediatric radiologist then obtained fluoroscopic images following the injection of a contrast through the G-tube in both lateral and frontal positions. The exam was tailored to confirm intraluminal contrast flow (gastric or gastroduodenal per the pediatric radiologist's judgement), confirm appropriate G-tube retention component alignment within the gastric lumen, and detect any extraluminal contrast leakage. The G-tube was then flushed with 10 mL of sterile water, and the images were sent to the PACS.

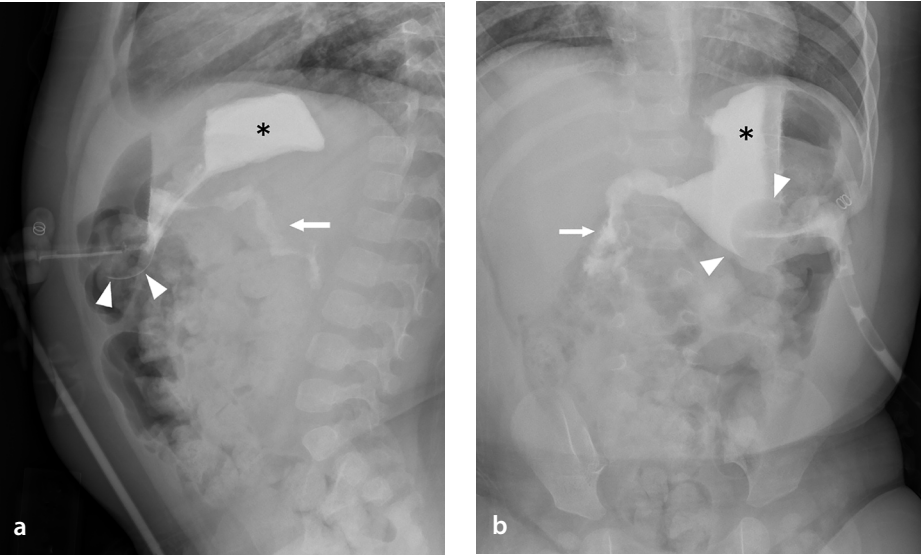
Epic data collection included demographics (age, weight, biological sex), clinical indication, referral location (Table 1), number of radiograph views, contrast volume administered, and exam reporting times (under or over 1 hour). Reporting time was defined as the time from exam uploading into PACS to pediatric radiologist report completion; for after-hours exams, reporting time was defined as the time of the radiology resident's preliminary report completion. Reporting times over 1 hour were compared between exams performed during daytime hours (Monday–Friday, 08:00–17:00) and those performed after-hours.

Any additional time delay for indeterminate exams was calculated as the time between the reporting of the radiograph exam as indeterminate to the onset of a fluoroscopic exam or resumption of G-tube use. After-hours exams performed at the satellite hospital and read remotely by the pediatric radiologist at the central children's hospital were identified, as a lack of this radiograph exam may have required an ambulance transport to the established children's hospital 3 hours away. Indeterminate exam readings by a pediatric radiologist with less experience (5 years or less) were compared to indeterminate exam readings by pediatric radiologists with greater experience (more than 5 years).

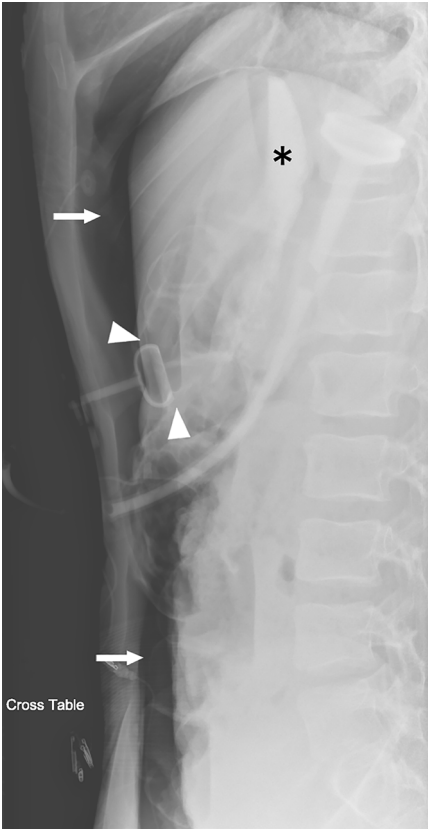
To confirm a negative radiograph exam, a chart review was performed to identify any 30-day adverse events, a standard used by the Society of Interventional Radiology.<sup>8</sup> Positive (abnormal) G-tube radiograph exams were acted on accordingly by a subspecialist



**Figure 2.** Gastrostomy-tube checks using radiographs: exam protocol.<sup>5</sup> XR, X-ray; G-TUBE, gastrostomy tube; W, with; ABD, abdomen; VW, view; mL, milliliter; PACS, picture archiving and communications system.



**Figure 3.** A 17-month-old male had gastrostomy tube (G-tube) dislodgement 4 months following surgical placement. After the surgery team placed a new G-tube button, a G-tube check radiograph exam was ordered, which was observed to be normal. (a) A cross-table lateral abdomen radiograph shows intraluminal contrast flow into the gastric lumen (\*) and duodenum (arrow). Intraluminal gastric contrast outlines the tube retention balloon (arrowheads). (b) A right-lateral decubitus radiograph shows gastric luminal contrast (\*) and contrast flow into the proximal duodenum (arrow). Gastric luminal contrast outlines the G-tube retention balloon (arrowheads) on this normal exam.



**Figure 4.** Cross-table abdominal radiograph shows the gastrostomy tube (G-tube) retention component appears to be within the gastric lumen (arrowheads), and gastric luminal contrast flow (\*) is seen. However, a large pneumoperitoneum is seen (arrows) in this patient with pain and tenderness at the G-tube site 2 days after percutaneous endoscopic gastrostomy tube placement. This patient required surgical revision of a loose G-tube gastric entry site that was leaking into the peritoneal cavity.



[pediatric surgery team, pediatric interventional radiology (IR) team] to obtain a normal G-tube alignment and resume G-tube use.

Statistical analysis

Diagnostic test characteristics [yield, accuracy, sensitivity, specificity, positive predictive value (PPV), and negative predictive value (NPV)] were calculated according to a standard formula,<sup>9</sup> excluding the 13 exams reported as indeterminate, and again after reclassifying the indeterminate exams based on clinical suspicion, as described in the “Methods” and “Discussion” sections. Confidence intervals (CI) for sensitivity and specificity were calculated according to the score CI formulae of Agresti and Coull<sup>9</sup> as described in Zhou et al.<sup>10</sup> The association between indeterminate reports and staff experience (5 years or less vs. more than 5 years), as well as the association of after-hours exams with reporting times (less than 1 hour vs. more than 1 hour), was assessed by chi-square using the software package StatXact-12 [v.12.0; Cytel Studio, 2019 (Cytel, Cambridge, MA, USA)]. A value of  $P \leq 0.05$  was considered statistically significant.

Results

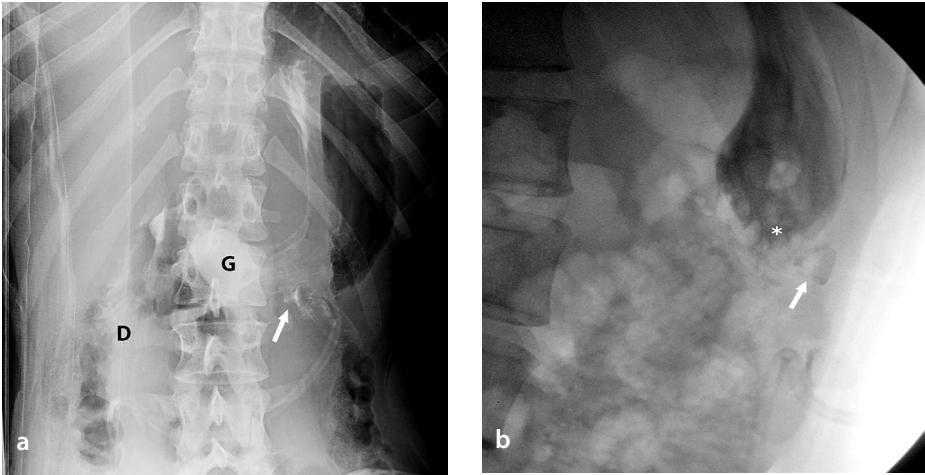
A total of 239 G-tube check exams were identified, and 12 were found to meet exclusion criteria, leaving 227 exams among 186 patients over the 2.5-year study period (Figure 1). Patient demographic details, referral location, and clinical indication are provided in Table 1.

The overall test yield was 94.3% (214/227), with a normal or abnormal exam reported. Normal exams (true negative) were found in 93.8% (213/227) of cases (Table 2); all negative exams were confirmed at a 30-day chart review. Five of the 227 radiograph exams (2.2%) were positive (abnormal) at the initial (primary) analysis. Findings on true positive exams at the initial analysis included a G-tube retention component in the abdominal wall or superficial gastrostomy tract anterior to the stomach (n = 3), intraperitoneal contrast leakage (n = 1), and large pneumoperitoneum (n = 1). Free extraluminal (peritoneal) air was seen on 3 exams, all within 7 days of the primary G-tube placement. In one of these cases, free air was a large volume in a symptomatic patient, and surgical revision was required. In the 2 other cases, the post-operative free air was minor and of no clinical significance.

Thirteen exams were reported as indeterminate, predominantly due to uncertain-

ty related to G-tube retention component alignment within the gastric lumen. The indeterminate exams had a median time delay of 40 minutes [interquartile range (IQR): 90]. Indeterminate exam reporting did not correlate with years of experience as a pediatric radiologist ( $P = 0.189$ ). Of the 13 indeterminate exams, 5 had no follow-up imaging (low clinical suspicion) and were reclassified as true negatives. Seven indeterminate exams with high clinical suspicion underwent fluo-

roscopy, 4 of which confirmed normal G-tube placement and were reclassified as false positives. An additional 3 indeterminate exams with high clinical suspicion revealed malpositioned G-tubes at fluoroscopy and were reclassified as true positive exams. The remaining indeterminate exam was particularly challenging to re-classify due to a delayed radiology report and differing clinical suspicion of the surgery and intensive care referring services. Specifically, the radiograph re-



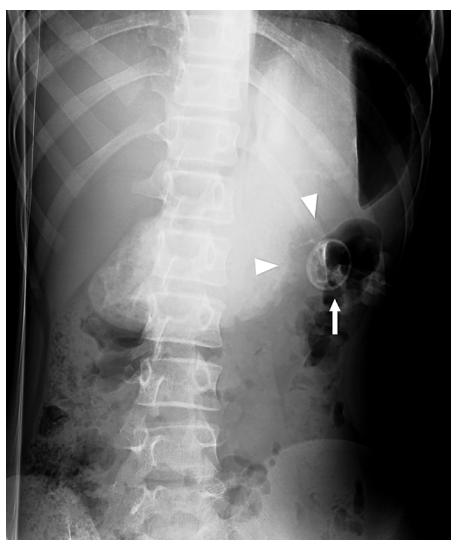**Figure 5.** A 17-year-old female with an indeterminate abdomen radiograph exam and high clinical suspicion who underwent a fluoroscopic gastrostomy tube (G-tube) contrast check exam confirming a true positive (abnormal exam).<sup>5</sup> (a) Right lateral decubitus abdomen radiograph shows definitive intraluminal contrast flow into the gastric lumen (G) and duodenum (D). However, alignment of the G-tube retention component (arrow) within the gastric lumen is uncertain. (b) Left posterior oblique view during a fluoroscopic G-tube contrast check shows the G-tube retention component (arrow) outside of the gastric luminal contrast (\*).

Table 1. Patient characteristics	
Variable	Overall (n = 227)
Age (years), median (IQR)	1.5 (8.3)
Weight (kg), median (IQR)	10 (16.8)
<b>Biological sex</b>	
Female – n (%)	98 (43.2%)
Male – n (%)	129 (56.8%)
<b>Indications</b>	
G-tube dislodged with routine replacement, n (%)	90 (40.1%)
G-tube dislodged with difficult replacement, n (%)	40 (17.6%)
G-tube leaking, n (%)	32 (14.1%)
Pain with G-tube feeds, n (%)	23 (10.1%)
Vomiting with G-tube feeds, n (%)	23 (10.1%)
G-tube partially dislodged, n (%)	9 (4%)
G-tube malfunction (not specified), n (%)	4 (1.8%)
Resistance to G-tube flush/infusion, n (%)	2 (0.9%)
Other, n (%)	26 (11.5%)
<b>Referral location</b>	
Emergency department	154 (67.8%)
Inpatient	57 (25.1%)
Outpatient	16 (7%)

IQR, interquartile range; kg, kilogram; G-tube, gastrostomy tube.

port described the presence of a small bowel contrast but no visualization of gastric luminal contrast and raised suspicion of transpyloric malposition of the distal G-tube segment (note: this patient had a longer G-tube type that was atypical for this study cohort with a variable tract length). This indeterminate exam was reported 2 hours after the exam was uploaded into PACS; the surgery team had already completed their consultation, had low clinical suspicion, and concluded that the radiograph exam was normal (no fluoroscopic exam recommended). However, the intensive care team remained concerned due to high gastric residuals via the nasogastric tube and requested an endoscopy, which confirmed gastric obstruction due to migration of the retention balloon of the G-tube. This indeterminate radiograph exam was, therefore, reclassified as a true positive exam.

The one 30-day adverse event involved a patient with autism, where the initial radiograph exam was read as normal. This patient returned to the emergency department 7 days later with increased abdominal pain and leakage at the ostomy site, and G-tube retention component malposition was confirmed on a repeat G-tube abdominal radiograph exam. Subsequent peer review of the initial G-tube check exam demonstrated G-tube retention component tract malpositioning, resulting in reclassification of this exam as a false negative exam (Figure 6).



**Figure 6.** A 14-year-old male with autism and abdominal pain at the gastrostomy tube (G-tube) site. The right lateral decubitus radiograph shows separation between the G-tube retention component (arrow) and gastric luminal contrast (arrowheads). This exam was reclassified as a false negative exam on pediatric radiology group peer-review assessment.<sup>5</sup>

Excluding indeterminate results, the exam performance metrics were as follows: sensitivity, 83.3%; specificity, 100%; PPV, 100%; NPV, 99.5%; accuracy, 99.5%. After reclassifying the indeterminate exams based on clinical suspicion, the performance metrics were as follows: sensitivity, 90.0%; specificity, 98.2%; PPV, 69.2%; NPV, 99.5% (Table 2); [95% CI for sensitivity (59.4%, 98.1%); 95% CI for specificity (94.5%, 98.4%)]. Test accuracy (true positives + true negatives/total exams) was 99.5% when excluding indeterminate results and decreased slightly to 97.8% after reclassification of the indeterminate exams.

Table 3 provides data on protocol adherence and shows that the standard 2-view radiograph protocol was followed in 81.9% (186/227) of cases. On a retrospective review of additional radiograph views, a majority appeared to have been performed for diagnostic purposes (to confirm G-tube retention component alignment or duodenal contrast flow) and less commonly for technical factors (radiograph coverage, faintly administered contrast, radiograph exposure issue). Furthermore, 78.9% (179/227) of the exams adhered to the contrast volume protocol. A contrast volume greater than the stratified volume was administered in 9.3% (21/227) of the studies.

Exam reporting time occurred under 1 hour in 79.7% (181/227). Reporting times longer than 1 hour occurred more often in the after-hours group ( $P = 0.032$ ). Radiology resident preliminary readings were found in 36.1% (82/227) of the exams and concurred with the final pediatric radiologist report in 96.3% (79/82) of the exams. Conversely, 5.7% (13/227) exams were reported as indeterminate, adding a median time delay of 40 minutes (IQR: 90). Ten exams, performed after-hours at the satellite hospital, were interpreted remotely at the central children's hospital, thereby potentially avoiding an inter-hospital ground transport.

## Discussion

In this retrospective study of 227 G-tube radiograph exams, we found a high overall exam yield (94.3%), with high accuracy (97.8%), sensitivity (90.0%), specificity (98.2%), and NPV (99.5%). These results demonstrate that a 2-view abdominal radiograph exam with stratified contrast administration can reliably evaluate G-tube positioning. With a shared PACS workstation, 2 affiliated hospitals received 24/7 reporting, despite limited on-site pediatric radiologist and radiology resident coverage.

The current shortage of pediatric radiologists is expected to continue into future

**Table 2.** G-tube check radiographs: exam performance

Primary analysis		
	+	-
	(G-tube malfunction)	(G-tube in normal position)
+	5	0
(Positive)	True positive	False positive
Indeterminate (13)		
-	1	208
(Negative)	False negative	True negative
Secondary analysis (indeterminate exams re-classified with clinical suspicion)		
	+	-
	(G-tube malfunction)	(G-tube in normal position)
+	9	4
(Positive)	True positive	False positive
-	1	213
(Negative)	False negative	True negative
Test yield	94.3%	
Accuracy	97.6%	
Sensitivity*	90.0%	
Specificity**	99.2%	
Positive predictive value	69.2%	
Negative predictive value	99.5%	

\*Sensitivity: 95% confidence interval (59.4%, 98.1%); \*\*Specificity: 95% confidence interval (94.5%, 98.4%); G-tube, gastrostomy tube.

years, as the number of pediatric radiology fellowship trainees has been decreasing for several years and the advancing age of pediatric radiologists nearing retirement.<sup>11,12</sup> This shortage comes at a time when the leadership of children's hospitals has greater expectations of 24/7 final reads of imaging exams, as well as expectations of coverage for a greater number of affiliated institutions.<sup>13,14</sup> During the coronavirus disease 2019 pandemic, the remote reporting of pediatric radiology exams experienced a marked increase, as evidenced by a SCORCH survey; 95.8% of groups now incorporate remote reading work assignments into their staffing schedules, up from 50% prior to the pandemic.<sup>1</sup>

At our institution, a change from the traditional fluoroscopic contrast checking of a G-tube by an on-site pediatric radiologist was necessitated after a new affiliated satellite children's hospital opened that lacked after-hours pediatric radiologist availability for an on-site fluoroscopic exam. Prior to this alternative protocol, such after-hours exams usually required a pediatric radiologist traveling to the hospital for an on-site fluoroscopic G-tube check. This study validates the prior single institution report of a radiograph exam performance where patients received either a radiograph exam or a fluoroscopic exam for both G-tube and GJ-tube checks, based on the availability of an attending radiologist in the hospital.<sup>4</sup> At our institution, the radiograph exam was the initial imaging exam for all G-tube checks; potential GJ-tube malfunctions at our institution are assessed by the IR service and were not intended to be included in this radiograph exam protocol.

Regarding the 2-view abdominal radiograph exam, the cross-table lateral view was chosen to look for pneumoperitoneum, G-tube alignment relative to the gastric lumen (Figure 3a), and intraluminal contrast flow. The subsequent right lateral decubitus radiograph was chosen to optimize detecting the duodenal contrast flow (Figure 3b). An age-based protocol for the volume of contrast to administer was devised to simplify this step for the RT performing the study, as an up-to-date weight may be lacking in the medical record at the time the study is ordered.

Indeterminate exams were mainly related to the uncertainty of the position of the G-tube retention component in the gastric lumen or the gastrostomy tract (Figure 4). Publications reporting the performance of a diagnostic study often exclude or mishandle

Table 3. Protocol adherence/variance		
Correct radiograph views per protocol, 81.9% (186/227)		
Additional radiograph views, 18.1% (41/227)		
View	Total	
Cross-table lateral	27	
Right lateral decubitus	16	
Frontal supine	11	
Left-lateral decubitus	5	
Total	59*	
Potential reasons for additional radiograph views on retrospective review		
Diagnostic interpretation		31
	Retention component alignment	15
	Duodenal contrast flow	14
	Interpreter judgement (need more definitive findings)	2
Technical exam factors		15
	Radiograph coverage incomplete	6
	Faint contrast on radiograph	5
	Exposure issue (radiograph too light/too dark)	4
RT protocol deviation		6
	Incorrect initial view	4
	Scout view incorrectly obtained	2
Correct contrast volume per protocol documented, 79.3% (180/227)		
Additional contrast documented, 9.3% (21/227)		
Administered contrast not documented, 11.5% (26/227)		
*59 additional radiograph views were performed in 41 radiograph exams; RT, radiology technologist.		

the indeterminate exams. One study found that only 35% of the published studies reviewed reported indeterminate results accurately.<sup>6</sup> Excluding indeterminate exams may falsely elevate exam performance parameters, as observed with the PPV of this cohort, which decreased from 100% to 69.2% when including the indeterminate exams on secondary analysis. Handling of indeterminate results is a complex issue, and clinical suspicion is considered a reasonable approach to reclassify indeterminate exams<sup>6</sup> and is supported by the Standard for Reporting Diagnostic Accuracy 2015 guidelines.<sup>7</sup> Specifically, if an indeterminate exam had high clinical suspicion (such as pain during G-tube use), a fluoroscopic G-tube contrast check exam was performed, and the abdominal radiograph exam was reclassified as a positive (abnormal) exam. If the indeterminate abdominal radiograph exam had low clinical suspicion, no fluoroscopic exam was performed, and the radiograph exam was reclassified as a negative (normal) exam. After this secondary analysis, including all exams, the new abdominal radiograph exam performed well, with particularly high accuracy (97.8%), sen-

sitivity (90.0%), specificity (98.2%), and NPV (99.5%). This study builds on a prior report of G-tube radiograph exam performance (75% sensitivity and 100% specificity) in a larger number of patients (227 vs. 126), while effectively managing indeterminate exams.<sup>4</sup> To improve the sensitivity of the exam, our group intermittently reviewed abnormal exam findings at our monthly peer-review meetings.

Deviations from the prescribed 2-view exam protocol occurred when the interpreting radiologists asked for additional radiographs or contrast to improve the diagnostic information of the exam, or exam technical factors (exposure issue, RT error). Given the equivocal gastric intraluminal alignment of the G-tube retention component on all 13 indeterminate exams, consideration of a different view (left lateral decubitus view) may be a helpful consideration, providing a different view to potentially outline the G-tube retention component with contrast. This alternative radiograph exam replaced fluoroscopy as the initial imaging exam for G-tube checking, which was well received by our pediatric radiologists providing after-hours



fluoroscopy call coverage. This transition was also well-received by our RTs, who were also short-staffed during the study period. Only one 30-day adverse event (repeat hospital visit to detect and correct G-tube malposition) occurred with this diagnostic exam transition.

Exam reporting time was studied, given its relation to the resumption of G-tube use for nutrition, hydration, and medications in a timely fashion. Here, 79.7% (181/227) of exams were reported under 1 hour, allowing for the timely resumption of G-tube use for hydration, medications, and nutrition in a majority of patients. Delayed reporting (over 1 hour) of exams occurred more often in the after-hours group, when pediatric radiologist coverage was reduced. Delay in reporting time can impact clinical management, as described for the patient with a delayed radiology report entry (after surgery team consult entry), leading to endoscopic (not fluoroscopic) confirmation of transpyloric G-tube malposition, causing gastric outlet obstruction.

The limitations of this study start with the inherent limitations of a retrospective chart review. For instance, when reviewing the reason for additional radiograph views, a given patient may have had an overlapping need for more diagnostic information in addition to the technical limitations of the initial 2-view exam (faintly administered contrast). Regarding protocol adherence, the contrast volume was not documented in Epic in 26 of the 227 exams. A limitation affecting exam reporting time occurred as the study period was before our pediatric radiology group converted to 24/7 attending pediatric radiologist reads of diagnostic radiology exams; a portion of study exams included an overnight preliminary reading made by radiology residents. Following completion of this study, our institution eliminated the beeper paging system. Epic Secure Chat is now used to message pediatric radiologists, a factor that could also influence reporting times in the future. A limitation regarding adverse events would be if a patient presented to a different institution during that 30-day period for any G-tube-related issue; this scenario should be

infrequent, as the 2 affiliated hospitals comprise the only comprehensive pediatric care system across the state. Comparison of radiation doses among the alternative radiograph exam and the traditional fluoroscopic exam is not addressed, but was reported using the limited data of this study cohort.<sup>5</sup>

This new exam was efficiently incorporated by RTs and pediatric radiologists (as well as radiology residents) on 2 campuses. The same standard of care was maintained, despite reductions in the number of pediatric radiologists and RTs.

In conclusion, this alternative diagnostic exam performed well with a high test yield, accuracy, sensitivity, specificity, and NPV. The exam mostly followed protocol, allowed for the timely and safe resumption of G-tube use, and provided the remote coverage needed for a new satellite hospital.

## Footnotes

## Conflict of interest disclosure

The authors declared no conflicts of interest.

## Funding

Clinical and Translational Science Awards to the University of Arkansas for Medical Sciences [National Institutes of Health (NIH) grants: UM1TR004909 and UL1TR003107] partially supported the statistical analysis and Research Electronic Data Capture (REDCap) database creation/management for this study.

## References

1. Seghers MC, Seghers VJ, Sher AC, et al. Working from home during the COVID-19 pandemic: surveys of the Society for Pediatric Radiology and the Society of Chiefs of Radiology at Children's Hospitals. *Pediatr Radiol*. 2022;52(7):1242-1254. [\[Crossref\]](#)
2. Culbertson J, Jennings, Culp M, Faguy, K. Mapping the Future of Medical Imaging and Radiation Therapy: White Paper on the 2024 Consensus Committee Meeting Outcomes. American Society of Radiologic Technologists, 2024. [\[Crossref\]](#)

3. Rosenkrantz AB, Hanna TN, Steenburg SD, Tarrant MJ, Pyatt RS, Friedberg EB. The current state of teleradiology across the United States: a national survey of radiologists' habits, attitudes, and perceptions on teleradiology practice. *J Am Coll Radiol*. 2019;16(12):1677-1687. [\[Crossref\]](#)
4. Tompe AP, Lee GM, Noel-Macdonnell JR, Chan SS. Retrospective cohort comparison between fluoroscopic and radiograph-only exams for evaluation of gastrostomy and gastrojejunostomy tubes. *Pediatr Radiol*. 2023;53(10):2021-2029. [\[Crossref\]](#)
5. Hameed M, James C, Wong K, et al. G-tube contrast check: transition from fluoroscopy to abdominal radiographs. *Res Sq [Preprint]*. 2024;rs.3.rs-5632134. [\[Crossref\]](#)
6. Shinkins B, Thompson M, Mallett S, Perera R. Diagnostic accuracy studies: how to report and analyse inconclusive test results. *BMJ*. 2013;346:f2778. [\[Crossref\]](#)
7. Cohen JF, Korevaar DA, Altman DG, et al. STARD 2015 guidelines for reporting diagnostic accuracy studies: explanation and elaboration. *BMJ Open*. 2016;6(11):e012799. [\[Crossref\]](#)
8. Baerlocher MO, Nikolic B, Sze DY. Adverse event classification: clarification and validation of the society of interventional radiology specialty-specific system. *J Vasc Interv Radiol*. 2023;34(1):1-3. [\[Crossref\]](#)
9. Agresti A, Coull B. Approximate is better than "exact" for interval estimation of binomial proportions. *Am Stat*. 1998;52:119-126. [\[Crossref\]](#)
10. Zhou XH, Obuchowski NA, McClish DK. Statistical Methods in Diagnostic Medicine. John Wiley & Sons, Inc., New York, 2002.
11. Farmakis SG, Chertoff JD, Barth RA. Pediatric radiologist workforce shortage: action steps to resolve. *J Am Coll Radiol*. 2021;18(12):1675-1677. [\[Crossref\]](#)
12. Dinh ML, Pfeifer CM, Gokli A. Promoting pediatric radiology at multiple levels. *Pediatr Radiol*. 2021;51(9):1556-1558. [\[Crossref\]](#)
13. Aquino MR, Maresky HS, Amirabadi A, et al. After-hours radiology coverage in children's hospitals: a multi-center survey. *Pediatr Radiol*. 2020;50(7):907-912. [\[Crossref\]](#)
14. Taylor GA, Ayyala RS, Coley BD. How did we get here? Thoughts on health care system drivers of pediatric radiology burnout. *Pediatr Radiol*. 2022;52:1019-1023. [\[Crossref\]](#)