



Computed tomography-guided irreversible electroporation for a pubic bone metastasis: a technical note and early experience

Claudio Pusceddu¹
 Eliodoro Faiella²
 Claudio Cau¹
 Pierluigi Rinaldi¹
 Paolo Cossu³
 Salvatore Marsico⁴

¹Mater Olbia Hospital, Clinic of Radiology, Olbia, Italy

²Campus Bio Medico, Department of Radiology, Rome, Italy

³Mater Olbia Hospital, Clinic of Anesthesiology, Olbia, Italy

⁴Hospital del Mar, Clinic of Radiology, Barcelona, Spain

ABSTRACT

Bone metastases are common in advanced solid tumors and often require local control strategies in addition to systemic therapy. Although thermal ablation is an established method for selected lesions, its use may be limited in anatomically complex or heat-sensitive locations. Irreversible electroporation, a non-thermal ablative technique widely used in visceral oncology, has not yet been reported for the treatment of bone metastases.

KEYWORDS

Ablation, bone, interventional, metastases, oncology

Bone metastases are a frequent and challenging complication of advanced malignancies, particularly in patients with breast, prostate, or lung cancer. These lesions often cause severe pain, impaired mobility, and pathological fractures, considerably reducing patients' quality of life and functional autonomy. In the multidisciplinary management of such patients, local tumor control remains a key objective, especially for symptomatic, progressive, or weight-bearing lesions.

Traditional local therapies include external beam radiotherapy, surgical stabilization, and image-guided percutaneous ablation. Among these, thermal ablation methods—radiofrequency ablation (RFA), microwave ablation (MWA), and cryoablation—have been widely adopted due to their efficacy, minimal invasiveness, and rapid recovery profiles. These techniques are recommended by current practice guidelines for treating painful or oligometastatic bone lesions and are particularly useful when systemic options are exhausted or contraindicated.^{1,2}

However, thermal ablation has important limitations. It is contraindicated in anatomical regions where adjacent critical structures—such as nerves, vessels, hollow organs, or joint capsules—are susceptible to thermal injury. The anterior pelvic ring, sacrum, spine, and skull base are examples of areas where thermal techniques pose a substantial risk of collateral damage. Moreover, thermal spread can be difficult to control, especially in heterogeneous or poorly vascularized tissues such as bone.

In this context, irreversible electroporation (IRE) represents a promising alternative. It is a non-thermal technique that induces apoptosis by delivering high-voltage electric pulses across cell membranes, creating permanent nanopores that disrupt cellular homeostasis.^{3,4} Its primary advantage lies in the preservation of the extracellular matrix and surrounding connective tissues. Unlike thermal energy, electrical fields do not denature collagen, elastin, or basement membranes, enabling tumor ablation near neurovascular bundles or urogenital organs with a reduced risk of collateral injury.⁵

IRE has already been validated in visceral oncology, particularly for pancreatic, hepatic, and renal tumors located in anatomically complex regions. Despite these promising applications, its use in the treatment of bone metastases has not been previously reported.

Corresponding author: Salvatore Marsico

E-mail: salvatore.marsico@hotmail.it

Received 14 April 2025; revision requested 21 April 2025;
last revision received 24 May 2025; accepted 22 June 2025.



Epub: 21.07.2025

Publication date: 02.01.2026

DOI: 10.4274/dir.2025.253402

You may cite this article as: Pusceddu C, Faiella E, Cau C, Rinaldi P, Cossu P, Marsico S. Computed tomography-guided irreversible electroporation for a pubic bone metastasis: a technical note and early experience. *Diagn Interv Radiol.* 2026;32(1):115-118.

In this case, the lesion's proximity to the urethra and pubic symphysis rendered it unsuitable for thermal techniques. The procedure demonstrated technical feasibility, safety, and early oncologic efficacy, supporting the potential role of IRE in musculoskeletal oncology.

Technique

A 55-year-old woman presented with a history of hormone receptor-positive, human epidermal growth factor receptor 2-negative breast cancer, diagnosed in 2013 and initially managed with radical mastectomy, axillary dissection, adjuvant chemotherapy, radiotherapy, and long-term endocrine therapy. She later developed widespread osseous metastatic disease, managed palliatively with capecitabine.

During restaging, pelvic magnetic resonance imaging revealed a 21 mm osteolytic lesion in the right pubic bone. Fluorodeoxyglucose (FDG) positron emission tomography/computed tomography (PET/CT) showed intense uptake, confirming the lesion's metabolic activity. The tumor was located in immediate proximity to the distal urethra and the anterior capsule of the pubic symphysis. Due to these anatomical constraints, further thermal ablation (previously attempted at another site) was contraindicated (Figure 1).

The patient was referred for percutaneous ablation and, after interdisciplinary tumor

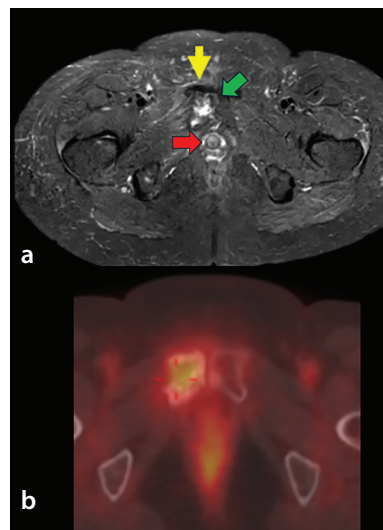


Figure 1. (a) Axial fat-suppressed T2-weighted (DP-FS) MRI of the pelvis demonstrating a hyperintense osteolytic lesion (yellow arrow) involving the right pubic bone. The anatomical relationship to adjacent critical structures, including the urethra (red arrow) and pubic symphysis (green arrow), was a key factor in selecting a non-thermal ablation approach (IRE). (b) Axial fused PET/CT image of the pelvis showing intense FDG uptake in a lytic lesion of the right pubic bone, consistent with metabolically active bone metastasis. DP-FS, dual phase fat suppression; IRE, irreversible electroporation; PET/CT, positron emission tomography/computed tomography; FDG, fluorodeoxyglucose; MRI, magnetic resonance imaging.

board discussion, was selected for CT-guided IRE as a non-thermal, structurally preserving approach.

The pubic metastasis was selected for treatment due to intense localized pain that severely impaired ambulation and its close proximity to the urethra, which posed a risk of urinary obstruction and functional decline.

Radiotherapy was excluded following a multidisciplinary team consensus evaluation due to the anatomical proximity of critical structures and the associated risk of collateral damage. Surgical resection was not indicated given the patient's advanced disease burden and limited functional reserve.

All procedures performed in studies involving human participants were in accordance with the ethical standards of the institutional and/or national research committee and with the 1964 Helsinki declaration and its later amendments or comparable ethical standards. Written informed consent was obtained for both the procedure and publication of data.

The patient was positioned supine on the CT table, with slight abduction of the legs to optimize access to the anterior pelvic region. General anesthesia was induced to ensure complete immobility during pulse delivery and to minimize discomfort. Electrocardiogram gating was employed to synchronize electrical pulses with the cardiac cycle (R-wave), minimizing the risk of arrhythmia during high-voltage delivery.

A contrast-enhanced pelvic CT was obtained to delineate tumor margins, measure safe access corridors, and plan the needle trajectory. The target lesion extended into both the cortical and medullary components of the right pubic bone and was in direct contact with the distal urethra.

Access was obtained via a percutaneous transosseous route using two Bonopt® (Apriomed, Upsala, Sweden) biopsy systems. The systems were drilled into the anterior cortical bone under CT guidance, creating stable channels for subsequent electrode insertion.

Two 19-gauge monopolar IRE electrodes (NanoKnife®, AngioDynamics®) were inserted through the coaxial access. The electrodes were positioned in parallel, flanking the lesion with an inter-electrode distance of 1.0–2.2 cm, adjusted according to lesion size and geometry. Positioning was confirmed in axial, coronal, and sagittal CT planes (Figure 2).

A test phase with 20 low-voltage pulses was performed to assess impedance. After confirming acceptable impedance (<1,500 ohms), full ablation was conducted with 70 pulses at 1,500 V/cm, 90-microsecond pulse duration, and a frequency of 1 Hz.

The electrode exposure length was 15 mm, and no pullbacks or repeat ablations were necessary.

Following ablation, a CT scan was acquired to exclude complications such as hemorrhage, pneumoperitoneum, or injury

Main points

- This is the first reported clinical case of irreversible electroporation (IRE) applied to a bone metastasis, specifically in the pubic bone.
- IRE enabled safe and effective ablation in an anatomically complex site where thermal techniques were contraindicated due to proximity to critical structures such as the distal urethra and pubic symphysis.
- The procedure was technically successful and well-tolerated, with no peri-procedural complications and complete metabolic response on positron emission tomography/computed tomography at 3-month follow-up.
- IRE preserved surrounding connective and neurovascular tissues, demonstrating its potential advantage in musculoskeletal oncology for lesions near heat-sensitive areas.
- This pioneering case provides proof-of-concept for the use of IRE in skeletal tumors and highlights the need for further clinical investigation and protocol development.

to adjacent organs. The patient awoke from anesthesia without complications or pain and was discharged the following day.

At 3-month follow-up, whole-body PET/CT showed complete metabolic response with no residual FDG uptake in the treated area (Figure 3). The patient reported a baseline visual analog scale pain score of 7/10, which improved to 2/10 at 48 hours post-procedure and 0/10 at 3-month follow-up, with preserved mobility and no new symptoms related to the ablation.

No delayed complications or local recurrence were identified, confirming both the safety and early efficacy of the procedure.

Two supporting procedural videos are available: Supplementary Video 1 illustrates transosseous CT-guided cannula placement and electrode deployment; Supplementary Video 2 demonstrates real-time pulse delivery using the IRE system interface.

Discussion

This case represents a pioneering application of IRE in the field of musculoskeletal interventional oncology. Pubic metastasis was prioritized due to its symptomatic burden, risk of functional compromise, and accessibility for safe percutaneous intervention.

The successful ablation of a pubic bone metastasis without thermal damage to adjacent urogenital structures highlights several important technical and clinical considerations.

First, IRE's non-thermal mechanism makes it particularly valuable in regions where heat or cold could cause unacceptable damage. The preservation of connective tissue, vasculature, and neural structures is a unique feature not shared by any other ablation modality.^{3,4} In the pelvis, this translates into potential applications near the bladder, urethra, sacral plexus, or neurovascular bundles—areas commonly involved by metastatic disease.

Second, the centripetal geometry of IRE allows for the precise definition of the ablation zone. Unlike the radial energy propagation of thermal techniques, IRE confines ablation to the area between the electrodes, enabling better control in irregular or constrained anatomical regions.⁴

Third, the mechanical integrity of bone may be better preserved with IRE compared with thermal methods. Although RFA and MWA are known to affect trabecular struc-

ture and increase fracture risk, IRE preserves bone scaffolding,⁶ potentially reducing the need for cementoplasty or other reinforcement procedures.

Preclinical studies have shown some risk of nerve injury with IRE—particularly in spinal or paraspinal locations—but also evidence of subsequent axonal regeneration.⁷ In our case, no neurological symptoms were observed post-procedurally; however, caution is warranted when planning procedures near major nerves.

Another interesting aspect is IRE's immunogenic potential. Several studies have shown that IRE-induced cell death may promote antigen presentation and immune activation, supporting possible synergy with immunotherapy or immune-modulating agents.⁷ This could be especially valuable in metastatic disease, where systemic control is also desired.

Although one case of IRE for a primary malignant bone tumor (Ewing sarcoma) has been reported, to our knowledge, this represents the first clinical application of IRE for

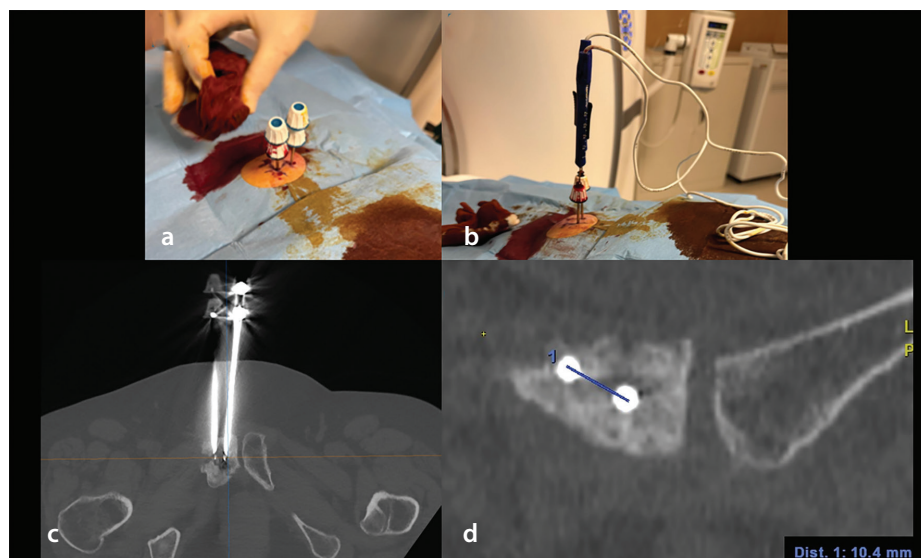


Figure 2. (a) Intraoperative view of the sterile setup showing the insertion of two Bonopt® 12-gauge coaxial bone access cannulae (Primed®) for a transosseous approach to the right pubic bone under CT guidance. (b) Intraoperative view showing coaxial insertion of the 19-gauge Nanoknife® IRE electrodes (AngioDynamics®) through the Bonopt® bone access cannulae. (c) Axial MIP reconstruction showing aligned placement of the right-sided 19-gauge IRE electrode targeting the osteolytic metastasis. (d) Coronal CT reconstruction demonstrating that the two IRE electrodes are positioned at an appropriate distance from each other, ensuring correct inter-electrode spacing for optimal electric field distribution. CT, computed tomography; IRE, irreversible electroporation; MIP, maximum intensity projection.

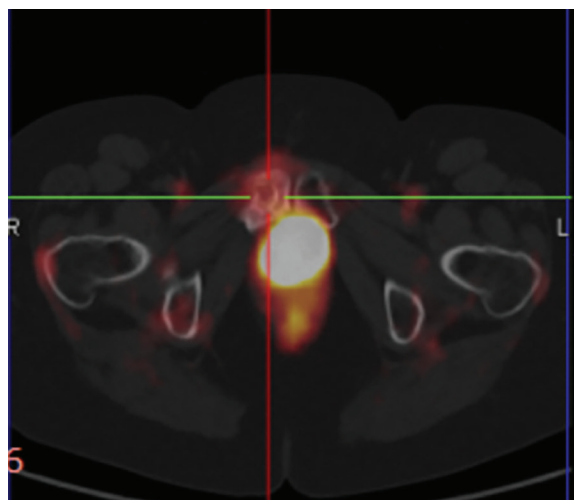


Figure 3. Axial fused PET/CT image obtained 3 months after IRE treatment showing complete metabolic response of the previously treated pubic bone metastasis. No residual FDG uptake is observed at the ablation site, consistent with successful local tumor control. PET/CT, positron emission tomography/computed tomography; IRE, irreversible electroporation; FDG, fluorodeoxyglucose.

a metastatic bone lesion.⁸ This distinction is important in terms of anatomical context, procedural planning, and therapeutic intent.

However, large-scale data are lacking, and this application remains investigational.

In conclusion, standardization is urgently needed for musculoskeletal IRE procedures, including optimal electrode design, energy delivery parameters, patient selection, and integration with other therapies. Prospective multicenter registries or trials would help define long-term outcomes and safety profiles.

Footnotes

Conflict of interest disclosure

The authors declared no conflicts of interest.

References

1. Callstrom MR, Charboneau JW, Goetz MP, et al. Image-guided ablation of painful metastatic bone tumors: a new and effective approach to a difficult problem. *Skeletal Radiol.* 2006;35(1):1-15. [\[Crossref\]](#)
2. Ryan A, Byrne C, Pusceddu C, Buy X, Tsoumakidou G, Filippiadis D. CIRSE standards of practice on thermal ablation of bone tumours. *Cardiovasc Intervent Radiol.* 2022;45(5):591-605. [\[Crossref\]](#)
3. Davalos RV, Mir IL, Rubinsky B. Tissue ablation with irreversible electroporation. *Ann Biomed Eng.* 2005;33:223-231. [\[Crossref\]](#)
4. Scheffer HJ, Nielsen K, de Jong MC, et al. Irreversible electroporation for nonthermal tumor ablation in the clinical setting: a systematic review of safety and efficacy. *J Vasc Interv Radiol.* 2014;25(7):997-1011; quiz 1011. [\[Crossref\]](#)
5. Martin RC 2nd, Kwon D, Chalikhonda S, et al. Treatment of 200 locally advanced (stage III) pancreatic adenocarcinoma patients with irreversible electroporation: safety and efficacy. *Ann Surg.* 2015;262(3):486-494; discussion 492-494. [\[Crossref\]](#)
6. Bazzocchi A, Aparisi Gómez MP, Taninokuchi Tomassoni M, et al. Musculoskeletal oncology and thermal ablation: the current and emerging role of interventional radiology. *Skeletal Radiol.* 2023;52(3):447-459. [\[Crossref\]](#)
7. Tam AL, Figueira TA, Gagea M, et al. Irreversible electroporation in the epidural space of the porcine spine: effects on adjacent structures. *Radiology.* 2016;281(3):763-771. [\[Crossref\]](#)
8. Steinbrecher K, Arslan B, Nassin ML, Kent P. Irreversible electroporation in the curative treatment of Ewing's sarcoma. *BMJ Case Rep.* 2016;2016:bcr2016216585. [\[Crossref\]](#)



Supplementary Video 1. Axial CT-guided procedure showing percutaneous insertion of irreversible electroporation electrodes into a lytic pubic bone lesion. Accurate intralesional positioning is confirmed by sequential axial imaging prior to electrical pulse delivery. CT, computed tomography.



Supplementary Video 2. Irreversible electroporation procedure: visualization of electrical pulse delivery with electrodes already positioned within the pubic lesion. Muscle contractions (involuntary spasms) induced by irreversible electroporation are clearly visible during pulse application.