



# Preoperative arterial and venous embolization of heterotopic ossification of the hip: a case-control study

Thomas Le Tat<sup>1,2</sup>  
 Fabien Cale<sup>3</sup>  
 Mostafa El Hajjam<sup>1</sup>  
 François Genêt<sup>4</sup>  
 Robert-Yves Carlier<sup>1</sup>  
 Raphaël Amar<sup>1</sup>

<sup>1</sup>Raymond Poincaré Hospital, Clinic of Radiology, Garches, France

<sup>2</sup>Percy Army Training Hospital, Clinic of Radiology, Clamart, France

<sup>3</sup>Raymond-Poincaré Hospital, Clinic of Orthopedic Surgery, Garches, France

<sup>4</sup>Raymond Poincaré Hospital, Clinic of Physical and Rehabilitation Medicine, Garches, France

## PURPOSE

Heterotopic ossification (HO) is an abnormal bone mass in soft tissue, often complicating spinal cord or brain injuries with paralysis. When ossification limits joint amplitudes and becomes symptomatic, surgical excision may be necessary, although it carries a high risk of hemorrhage. This study evaluates the role of preoperative arterial embolization on peri-operative bleeding.

## METHODS

A retrospective case-control study was conducted on patients undergoing hip HO resection between September 2019 and April 2024. Only anteromedial or circumferential HO were included. Data on blood loss, transfusion requirements, duration of surgery, and length of hospital stay were analyzed. Embolization was performed with microspheres 500–700 µm and/or coils. Statistical significance was determined using the Mann–Whitney U test ( $P < 0.05$ ).

## RESULTS

A total of 18 resections of HO and 9 preoperative embolizations were performed. Embolization was technically successful in all cases, with an average of 1.2 embolized arteries per patient. Venous embolization was performed in three specific cases. The mean surgical time was 127 min. The estimated mean blood loss was 1.789 mL, with no significant reduction with embolization ( $P = 0.25$ ). However, embolized patients had a significantly shorter hospital stay (6.2 vs. 8 days,  $P = 0.03$ ). One complication (arterial thrombosis downstream of the puncture site) was reported and successfully treated.

## CONCLUSION

Preoperative embolization may improve recovery by shortening hospital stay; however, its impact on surgical bleeding remains unclear. Further studies are needed to refine embolization strategies and evaluate long-term outcomes, including recurrence rates.

## CLINICAL SIGNIFICANCE

Preoperative embolization is a promising adjunct to complex HO hip resections, with a favorable safety profile that justifies its consideration in multidisciplinary surgical planning.

## KEYWORDS

Heterotopic ossification, preoperative arterial embolization, hip surgery, interventional radiology, surgical outcomes

**Corresponding author:** Thomas Le Tat

**E-mail:** letat.thomas@yahoo.fr

Received 06 May 2025; revision requested 08 June 2025; accepted 16 July 2025.



Epub:16.12.2025

Publication date: 04.05.2026

DOI: 10.4274/dir.2025.253416

You may cite this article as: Le Tat T, Cale F, El Hajjam M, Genêt F, Carlier R-Y, Amar R. Preoperative arterial and venous embolization of heterotopic ossification of the hip: a case-control study. *Diagn Interv Radiol.* 2026;32(3):322-327.

**H**eterotopic ossification (HO) is a proliferation of heterotopic extra-articular calcifications.<sup>1</sup> It is a common complication following brain or spinal cord injury with paralysis, appearing within the first 6 months in nearly 20% of patients.<sup>2</sup>

When HO significantly impairs quality of life by limiting joint mobility and causing pain, surgery is often required.<sup>3,4</sup> Surgical resection, though effective, is associated with substantial intraoperative bleeding due to the hypervascular nature of HO, and the presence of multiple vessels feeds these ossifications. Although tranexamic acid can reduce bleeding in orthopedic surgery, its efficacy in HO resection remains limited.<sup>5</sup> One way of limiting peri-operative bleeding could be preoperative embolization. However, although preoperative embolization is well-documented in reducing bleeding in malignant bone tumors, its role in HO resection remains underexplored, with only a few cases reported.<sup>6</sup>

The primary objective of this study is to evaluate the efficacy of pre-operative arterial embolization in reducing peri-operative bleeding during HO resection. Secondary objectives include assessing the safety of the procedure and its impact on operative time and hospital stay.

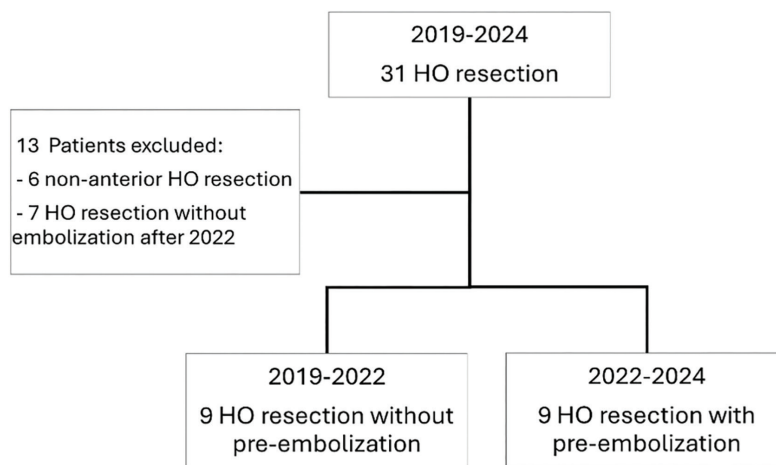
## Methods

### Study design

This retrospective case-control study included 18 surgical resections of symptomatic HO of the hip between September 2019 and April 2024. The inclusion criteria were age > 18 years and symptomatic circumferential or antero-medial HO requiring anterior surgical resection (Figure 1). HO was considered symptomatic when it caused functional discomfort or persistent pain or when signs of neuronal or vascular compression appeared.

#### Main points

- Preoperative embolization is feasible and technically successful in all cases of high-risk hip heterotopic ossification.
- Hospital stay was significantly shortened in embolized patients compared with those who were non-embolized.
- Venous embolization has been performed in selected cases and requires further studies to assess its efficacy.



**Figure 1.** Flowchart. HO, Heterotopic ossification.

Nine non-embolized cases came from a previous study in which patients underwent surgery between September 2019 and January 2022.<sup>7</sup> From January 2022 onward, a multidisciplinary meeting including the surgical team and the interventional radiology teams took place before any resection of HO considered by the surgeon to be at high risk of bleeding to decide if preoperative embolization was required for the patient. High hemorrhagic risk was defined by the presence of major vessels embedded within the HO mass, making surgical exposure and potential ligation in case of bleeding particularly difficult. Nine preoperative arterial embolization operations were performed between January 2022 and April 2024; 7 patients underwent surgical resection of circumferential or antero-medial HO without preoperative embolization after January 2022 but were not included in this study, as they were considered by the surgeon to be at moderate risk of bleeding.

The following data were collected: age, sex, weight, height, body mass index, etiology of HO, size of HO, time from surgery to hospital discharge, preoperative and postoperative hemoglobinemia, blood transfusion details, and operative time. For embolized patients, the following data were also collected: procedure length (time from preparation of the patient's groin until the time of the last image acquired), dose area product, fluoroscopy time, and number of embolized vessels. Blood mass was estimated at 70 mL/kg. Blood loss was calculated using Gross' formula, based on the difference between preoperative hemoglobinemia and the lowest postoperative hemoglobinemia during hospitalization.<sup>8</sup>

Prior to embolization and surgery, computed tomography (CT) angiography was performed in all patients to plan the embolization and surgical procedure [SOMATOM Definition AS (Siemens Healthineers, Erlangen, Germany)]. A biphasic CT scan was performed, with a first injection of 120 mL of iodinated contrast medium (Iomeron 400 mg/mL, Bracco Imaging) at a speed of 1.5 mL/s immediately followed by a second injection of 80 mL at a speed of 3 mL/s. The CT scan was triggered 135 s after the start of the first injection. Multi-planar reconstructions were produced, along with three-dimensional images showing bone and the vascular tree. In a single acquisition, this protocol enables the radiologist and surgeon to locate the vessels in the surgical pathway easily and to plan embolization.<sup>9</sup>

### Arterial and venous embolization and the surgical procedure

All procedures were performed under local anesthesia in an angiographic unit (Azurion®, PHILIPS, Amsterdam, Netherlands) by two interventional radiologists with 8 (RA) and 25 (EHM) years' experience in interventional radiology. After percutaneous introduction of a 5 Fr sheath into the femoral artery contralateral to ossification, a 5 Fr Cobra 2 catheter was used to cross-over and catheterize the deep femoral artery. Selective catheterization was then performed with a microcatheter (2.4 Fr and 2.7 Fr Progreet®, Terumo, Tokyo, Japan; 2.4 Fr Maestro®, Merit Medical, South Jordan, USA). Microspheres 500–700 µm (Embogold®, Merit Medical, South Jordan, USA) were then injected until the tumor blush disappeared, followed by coils (Nester® CookMedical, Bloomington,

USA; Mreye® CookMedical, Bloomington, USA). Technical success was defined as complete occlusion of the feeding vessels in the surgical pathway. As the surgical approach was anterior, only feeding vessels located anterior to the HO were considered on the surgical path.

Venous embolization was requested by the surgeon when one of the main branches of the femoral veins he planned to clamp was surrounded by HO, as these veins present a particular surgical challenge due to their proximity to ossified tissue, making them difficult to isolate and clamp during dissection. Venous embolization was intended to facilitate surgical exposure and potentially minimize intraoperative bleeding. Venous embolization was performed under local anesthesia by the same interventional radiologists. After percutaneous introduction of a 5 Fr sheath into the femoral vein contralateral to ossification, a 5 Fr Cobra 2 catheter was used to cross-over and catheterize the lateral circumflex vein. Embolization was then performed with coils.

Surgery was scheduled shortly after embolization, usually the following day, before any new vascularization occurred. Surgery was performed via an anterior approach similar to an extended Hueter approach, extending proximally along the iliac crest to the medial gluteal tuberosity and distally to the junction between the middle and upper thirds of the thigh.<sup>4,10</sup>

The French Ethics Committee for Medical Imaging Research (CERIM) approved this retrospective study and waived the require-

ment for written informed consent (approval number: CRM-2501-462, date: 23.03.2025).

### Statistical analysis

Due to the small size of the study, the non-parametric Mann–Whitney U test was used for quantitative values. A *P* value of < 0.05 was defined as statistically significant. Statistical analyses were performed using R version 4.4.2 (R Foundation for Statistical Computing, Vienna, Austria).

## Results

Of the 18 cases of HO included, 16 were neurogenic HO and 2 were related to prolonged hospitalization in an intensive care unit (Table 1); 9 pre-operative embolizations were performed (Figure 2). All embolizations were technically successful, defined as embolization of vessels in the surgical tract, with an average of 1.2 arteries embolized (Table 2). HO was generally supplied by branches of the medial and lateral circumflex femoral arteries as well as by perforating branches of the deep femoral artery. Embolization most frequently involved branches of the lateral circumflex femoral artery, with additional vessels targeted when they were located within the planned surgical field (Figure 3). Three patients also benefited from embolization of the lateral circumflex vein, which was located on the operative path (Figure 4). The estimated mean blood loss was 1.789 mL, with no significant difference between embolized and non-embolized patients (*P* = 0.25). Six patients (33%) required transfusion during their hospital stay. The mean operative time was 127 min, with no significant dif-

ference between groups. The mean length of hospital stay after surgical resection was 7.1 days and was significantly shorter in embolized patients than in non-embolized patients: 6.2 days vs. 8 days (*P* < 0.05).

One complication was reported in the embolization group, classified as Grade 3 according to the Cardiovascular and Interventional Radiological Society of Europe classification system.<sup>11</sup> This involved the thrombosis of a distal artery downstream of the puncture site, which was effectively treated with thrombolytics. However, surgery had to be postponed for 2 months.

## Discussion

This study evaluated the efficacy and safety of preoperative embolization on peri-operative bleeding prior to resection of HO. Only patients presenting with circumferential or anteromedial HO were included in this study, as these patterns are associated with the highest risk of bleeding.<sup>12</sup>

Preoperative embolization was associated with a significantly shorter hospital stay compared with patients without embolization. However, no significant differences were observed in terms of blood loss or blood transfusion requirements. This differs from the case-control study by Papalexis et al.,<sup>6</sup> who found a reduction in transfusion requirements and hemoglobin loss after pre-embolization with cyanoacrylate glue. In our study, the mean number of arteries embolized was 1.2. The interventional radiologist endeavored to embolize only vessels located in the surgical pathway, thereby limiting

**Table 1.** Continuous data are presented as the mean and standard deviation. Categorical data are shown as the number and percentage

Baseline characteristics	Embolization n = 9	No embolization n = 9	Total n = 18	<i>P</i> value
Age (years)	41 (13.7)	51.7 (12.1)	46.3 (13.7)	
Male, n (%)	8 (88.9%)	8 (88.9%)	16 (88.9%)	
Body mass index	23 (3.9)	24.3 (4.1)	23.7 (4)	
Etiology				
- Brain injury, n (%)	3 (33.3%)	3 (33.3%)	6 (33.3%)	
- Spinal injury, n (%)	5 (55.6%)	5 (55.6%)	10 (55.6%)	
- Prolonged stay in intensive care, n (%)	1 (11.1%)	1 (11.1%)	2 (11.1%)	
Pre-operative hemoglobinemia (g/dL)	13.6 (1.1)	13.3 (1.3)	13.5 (1.2)	
Estimated blood volume (mL)	5,024 (876)	5,616 (1219)	5,320 (1,074)	
Heterotopic ossification volume (mL)	757 (471)	570 (305)	664 (397)	
Post operative follow-up				
Operative time (min)	115 (38)	139 (38)	127 (39)	0.31
Hospital stay duration (days)	6.2 (3.1)	8 (3.9)	7.1 (3.5)	0.03
Estimated blood loss (mL)	2,097 (1,150)	1,497 (683)	1,796 (968)	0.25
Units of blood transfused	1.2 (2)	0.9 (1.5)	1.1 (1.7)	0.87

**Table 2.** Continuous data are presented as the mean and standard deviation

Endovascular procedures	
Number of embolized arteries	1.2 (0.8)
Procedure length (min)	81 (32)
Fluoroscopy time (min)	20 (8)
Dose area product (Gy.cm <sup>2</sup> )	63 (33)

the risk of osteonecrosis in healthy bone. In the study by Papalexis et al.,<sup>6</sup> the operator embolized an average of 2.6 arteries and > 90% of the arteries feeding the ossification. Thus, intraoperative bleeding also depends on the complexity of the surgical procedure, which is difficult to quantify. The retrospective case-control design of our study, with selection based on perceived bleeding risk, introduces a strong selection bias, which may explain why we did not achieve a significant reduction in bleeding. Other possible explanations are the use of particles rather than glue and the limited number of arteries embolized. Future studies could determine the best strategy.

The embolization procedure demonstrated a favorable safety profile, with only one

complication observed across all cases, related to arterial puncture. None of the other cases reported in the literature had complications related to embolization.<sup>13-17</sup>

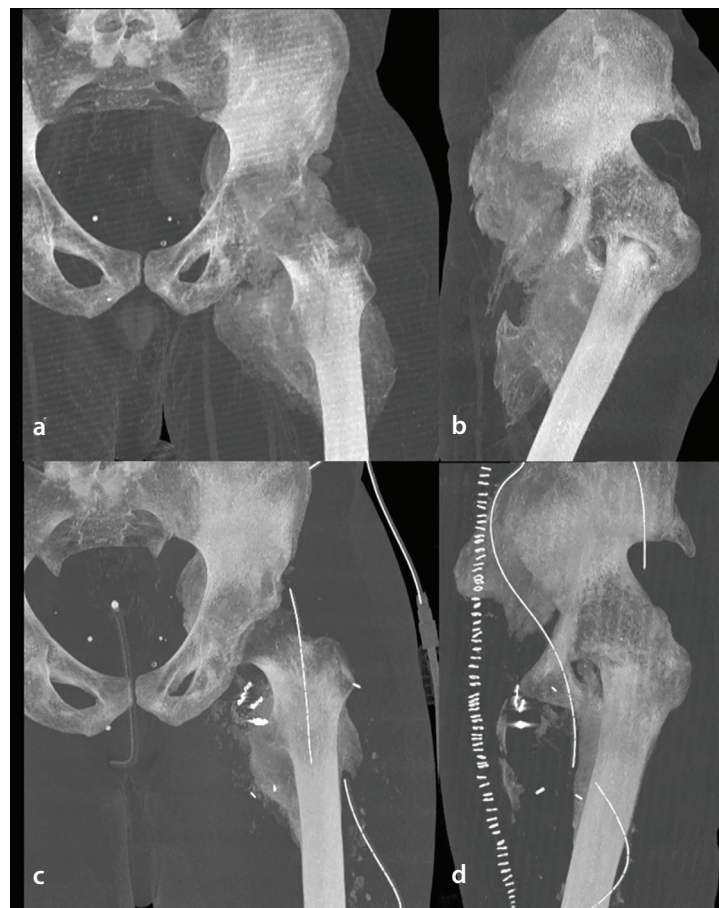
We only studied patients operated on via the anterior approach, in whom the risk of bleeding is highest.<sup>12</sup> However, given the safety profile of embolization, it would be interesting for further studies to examine the effect of preoperative embolization for other surgical approaches. Nevertheless, preoperative embolization of the HO has the same disadvantages and risks as other preoperative embolizations, including non-targeted embolization, risk of vascular complications, and increased overall cost.

The three cases of venous embolization in this study are the first published in the literature for this indication. Although this study does not assess the efficacy of this embolization, this technique could perhaps be of interest in special anatomical circumstances, notably when large veins are embedded in the ossification, as they are difficult to manage by the surgeon and can lead to life-threatening bleeding.<sup>18,19</sup>

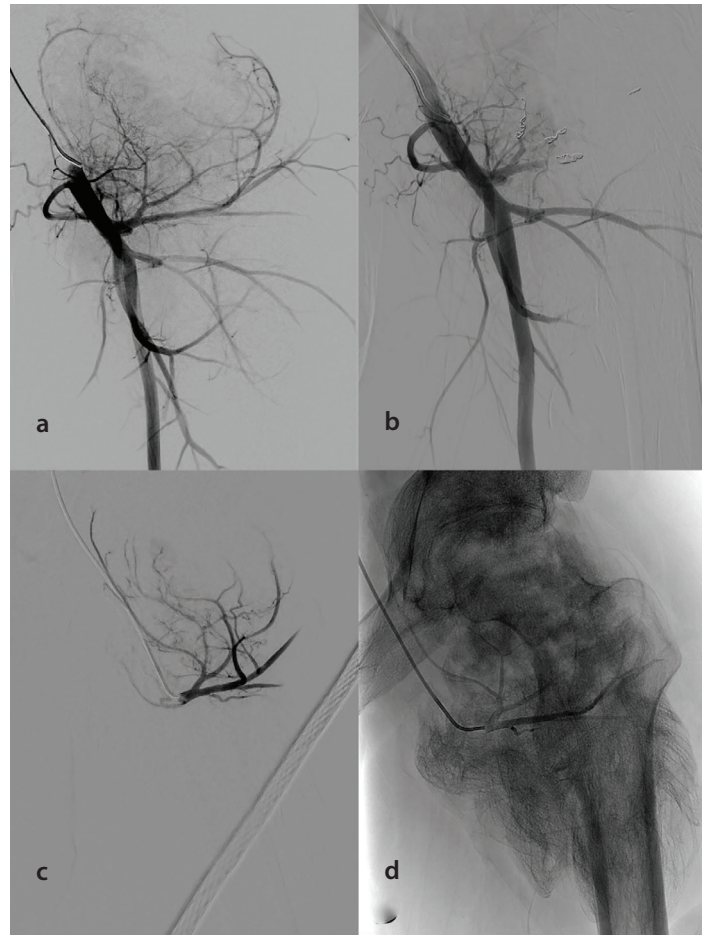
Unfortunately, we were unable to carry out a long-term follow-up of our patients, as half of them were referred to us for surgery and, after the 1<sup>st</sup> year, conducted their follow-up elsewhere. It would be interesting in the future to determine whether embolization can limit the risk of symptomatic recurrence of HO.

This study has several limitations, including its retrospective design with non-random allocation and the small sample size. Thus, it remains possible that HO management improved during the study and that the observed effect on hospital stay is due solely to this, as this is a before-and-after study. Moreover, the length of hospital stay is not the best criterion in open-label studies, as medical staff may be encouraged to discharge patients, knowing they have been embolized.

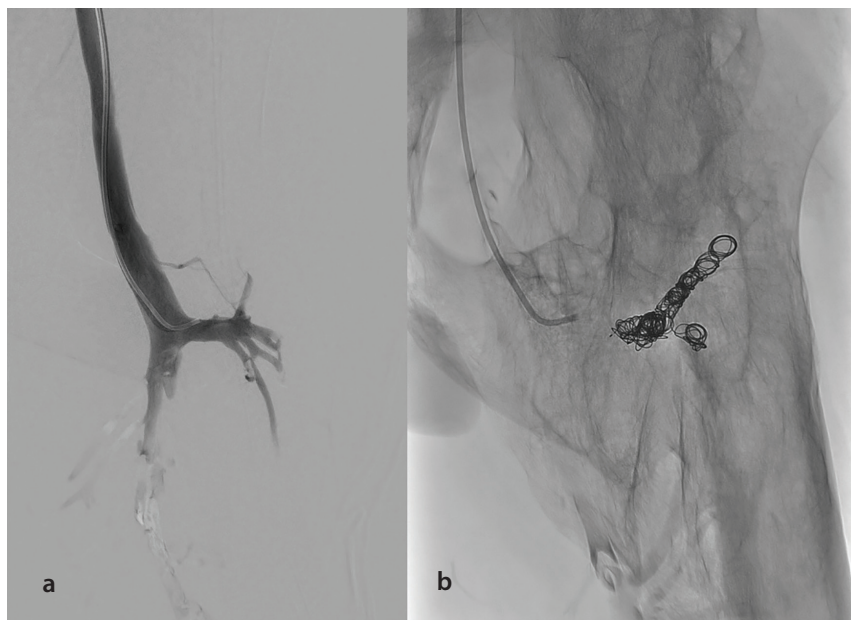In conclusion, preoperative embolization appears to be a safe adjunct to HO resection, significantly reducing hospital stay. However, its impact on surgical bleeding remains unclear. Further research is needed to refine embolization techniques and evaluate long-term outcomes, including recurrence rates.



**Figure 2.** Pre-operative (a, b) and postoperative (c, d) computed tomography scan of the left hip in the maximum-intensity projection.



**Figure 3.** Angiographic views of the left hip (same patient as Figure 1). (a) Angiography of the deep femoral artery, showing pseudotumoral hypervascularization originating from the lateral femoral circumflex artery. (b) Angiography of the deep femoral artery after embolization of branches of the lateral femoral circumflex artery, showing reduced hypervascularization and the persistence of pseudotumoral blush from branches of the medial femoral circumflex artery. These arterial branches were not embolized, as they were not on the operative path. (c, d) Selective angiography of the lateral circumflex femoral artery prior to embolization.



**Figure 4.** Phlebography of the left femoral vein. (a) Pre-embolization phlebography showing the lateral circumflex vein. (b) Post-embolization.

## Footnotes

## Conflict of interest disclosure

The authors declared no conflicts of interest.

## References

1. Dejerine A, Ceillier A. Para-ostéo-arthropathies des Paraplégiques par lésion médullaire: Étude clinique et radiographique. *Ann Méd.* 1918;497-5.
2. Wittenberg RH, Peschke U, Bötel U. Heterotopic ossification after spinal cord injury. Epidemiology and risk factors. *J Bone Joint Surg Br.* 1992;74(2):215-218. [\[Crossref\]](#)
3. Ranganathan K, Loder S, Agarwal S, et al. Heterotopic ossification: basic-science principles and clinical correlates. *J Bone Joint Surg Am.* 2015;97(13):1101-1111. [\[Crossref\]](#)
4. Denormandie P, de l'Escalopier N, Gatin L, Grelier A, Genêt F. Resection of neurogenic heterotopic ossification (NHO) of the hip. *Orthop Traumatol Surg Res.* 2018;104(1 Suppl):121-127. [\[Crossref\]](#)
5. Kim C, Park SSH, Davey JR. Tranexamic acid for the prevention and management of orthopedic surgical hemorrhage: current evidence. *J Blood Med.* 2015;6:239-244. [\[Crossref\]](#)
6. Papalexis N, Peta G, Errani C, Miceli M, Facchini G. Preoperative arterial embolization for heterotopic ossification of the hip. *J Vasc Interv Radiol.* 2023;34(4):608-612. [\[Crossref\]](#)
7. Amar R, Salga M, Tordjman M, et al. Neurogenic heterotopic ossification of the hip: magnetic resonance imaging versus computed tomography for pre-surgical assessment. *Eur J Radiol.* 2024;175:111466. [\[Crossref\]](#)
8. Gross JB. Estimating allowable blood loss: corrected for dilution. *Anesthesiology.* 1983;58(3):277-280. [\[Crossref\]](#)
9. Law-Ye B, Hangard C, Felter A, et al. Pre-surgical CT-assessment of neurogenic myositis ossificans of the hip and risk factors of recurrence: a series of 101 consecutive patients. *BMC Musculoskelet Disord.* 2016;17(1):433. [\[Crossref\]](#)
10. Genêt F, Jourdan C, Schnitzler A, et al. Troublesome heterotopic ossification after central nervous system damage: a survey of 570 surgeries. *Plos One.* 2011;6(1):e16632. [\[Crossref\]](#)
11. Filippidis DK, Binkert C, Pellerin O, Hoffmann RT, Krajina A, Pereira PL. Cirse quality assurance document and standards for classification of complications: the cirse classification system. *Cardiovasc Intervent Radiol.* 2017;40(8):1141-1146. [\[Crossref\]](#)
12. Mavrogenis AF, Guerra G, Staals EL, Bianchi G, Ruggieri P. A classification method for neurogenic heterotopic ossification of the hip. *J Orthop Traumatol.* 2012;13(2):69-78. [\[Crossref\]](#)
13. Appelt EA, Kenkel JM, Ballard JR, Lopez JA, Anthony T, Castillo T. Preoperative embolization of heterotopic ossification for the treatment of a recalcitrant pressure sore. *Plast Reconstr Surg.* 2005;116(4):50e-53e. [\[Crossref\]](#)
14. Vogl TJ, Wolff JD, Balzer J, Skripitz R. Preoperative arterial embolization in heterotopic ossification: a case report. *Eur Radiol.* 2001;11(6):962-964. [\[Crossref\]](#)
15. Kim JH, Park C, Son SM, et al. Preoperative arterial embolization of heterotopic ossification around the hip joint. *Yeungnam Univ J Med.* 2018;35(1):130-134. [\[Crossref\]](#)
16. Zielinski E, Chiang BJL, Satpathy J. The role of preoperative vascular imaging and embolisation for the surgical resection of bilateral hip heterotopic ossification. *BMJ Case Rep.* 2019;12(8):e230964. [\[Crossref\]](#)
17. Igei T, Nakasone S, Ishihara M, Onaga M, Nishida K. Embolization followed by resection of the heterotopic hip joint ossification with spinal cord injury. *J Orthop Sci.* 2024;29(1):454-457. [\[Crossref\]](#)
18. Garland DE, Hanscom DA, Keenan MA, Smith C, Moore T. Resection of heterotopic ossification in the adult with head trauma. *J Bone Joint Surg Am.* 1985;67(8):1261-1269. [\[Crossref\]](#)
19. Alshameeri Z, Bajekal R, Varty K, Khanduja V. Iatrogenic vascular injuries during arthroplasty of the hip. *Bone Joint J.* 2015;97-B(11):1447-1455. [\[Crossref\]](#)