



Percutaneous cystic duct embolization with microvascular plug and LAVA liquid embolic system for persistent bile leak following cholecystectomy

Aamir Ali¹
 Talal Abdel Aal²
 Ahmed Kamel Abdel Aal¹

¹The University of Texas Health Science Center at Houston, Department of Diagnostic and Interventional Imaging, Texas, United States of America

²The University of Texas Health Science Center at Houston, McGovern Medical School, Texas, United States of America

Bile duct injury from laparoscopic cholecystectomy is an uncommon complication. Percutaneous cystic duct embolization has been used to treat bile leaks from the cystic duct in patients who are not surgical candidates or who have failed endoscopic retrograde cholangiopancreatography (ERCP). A case of a 48-year-old man who underwent cholecystectomy complicated by bile leak and biloma in the gallbladder fossa requiring drain placement is presented. The patient initially underwent ERCP with sphincterotomy of the major duodenal papilla and common bile duct stent placement. However, due to a persistent bile leak, a percutaneous cystic duct embolization procedure was performed through the gallbladder fossa using a microvascular plug and the LAVA[®] Liquid Embolic System (LES) in a retrograde fashion. The output from the preexisting drain in the gallbladder fossa stopped within 3 days, and the drain was removed after follow-up abdominal computed tomography at 1 week, which confirmed resolution of the biloma. The LAVA LES has not been reported in the literature with respect to cystic duct embolization.

KEYWORDS

Cholecystectomy, bile leak, cystic duct embolization, microvascular plug, LAVA Liquid Embolic System

Bile duct injuries from laparoscopic cholecystectomy have been reported with an incidence of 0.3%–0.6%, and they can lead to biloma formation with increased risk of infections.¹ Cystic duct leak following cholecystectomy can be managed by surgical interventions, endoscopic retrograde cholangiopancreatography (ERCP), or percutaneous cystic duct embolization.^{2,3} The existing literature is limited to percutaneous cystic duct embolization, which is supported by only a few case reports.⁴⁻⁷ A case of cystic duct embolization with a combination of a microvascular plug and the LAVA[®] Liquid Embolic System (LES) is presented. To our knowledge, the use of LAVA LES, alone or with other embolics, for embolization of the cystic duct has not been reported in the literature.

Technique

Informed consent was obtained from the patient for the publication of this case report. A 48-year-old man was transferred from an outside hospital following a laparoscopic cholecystectomy for acute cholecystitis complicated by bile leak resulting in biloma in the gallbladder fossa that was treated with percutaneous drain placement. On admission, he was afebrile with abdominal pain, leukocytosis (white blood cell count: 16.9 K/uL), and mildly elevated liver enzymes (alanine aminotransferase: 105 U/L, aspartate aminotransferase: 102 U/L, alkaline phosphatase: 145 U/L). The patient underwent ERCP with major papilla sphincterotomy, with placement of an 8.5 French × 7 cm straight plastic stent (Boston Scientific, Marlborough, MA, USA) in the common bile duct to treat the cystic duct leak. After 1 week, the drainage catheter in the gallbladder fossa was upsized from 10 to 12 French (Cook Medical, Bloomington, IN, USA) due to catheter occlusion and a persistent biloma of the same size on computed

Handling Editor: Barbaros Çil

Corresponding author: Aamir Ali

E-mail: aamiralikemu@gmail.com

Received 04 March 2026; revision requested 06 March 2026; accepted 11 March 2026.



Epub: 23.06.2026

DOI: 10.4274/dir.2026.263693

tomography (CT) of the abdomen and pelvis. Contrast injection through the exchanged drainage catheter demonstrated communication between the cystic duct and the gallbladder fossa biloma (Figure 1). Following the exchange of the gallbladder fossa drainage catheter and continued antibiotic treatment, the patient's leukocytosis improved. However, he had persistently elevated alkaline phosphatase enzyme and continuous bile fluid output from the drainage catheter. Repeat abdominal CT performed 3 days after the procedure showed no significant change in the size of the biloma in the gallbladder fossa. Surgical treatment for the bile leak was not possible because of infection. The primary team consulted interventional radiology for cystic duct embolization, and the patient preferred general anesthesia.

Contrast injection through the indwelling drainage catheter in the biloma confirmed communication with the cystic duct. The drainage catheter was replaced with a 6-French sheath (Terumo Medical, Somerset, NJ, USA) using a 0.035-in Amplatz wire (Cook Medical). A 5-French Kumpe catheter (Cook Medical) was placed in the biloma through the introducer sheath, and the distal end of the cystic duct was catheterized using a 0.035-in Glidewire® (Terumo Medical) (Figure 2a). A 2.8-French Progreat® microcatheter (Terumo Medical) was advanced into the common bile duct (Figure 2b) and then retracted into the proximal cystic duct. First, the MVP-3Q microvascular plug (Medtronic, Minneapolis, MN, USA) was deployed in the proximal segment of the cystic duct (Figure 2c), and then the distal segment of the cystic duct was embolized with 1 mL of LAVA-34 LES (Sirtex Medical Inc, Woburn, MA) in retrograde fashion while pulling back the microcatheter (Figure 2d). Following this, a digital subtraction cholangiogram was performed with contrast injection through the 5-French Kumpe catheter in the biloma, which showed a small separate superior out-

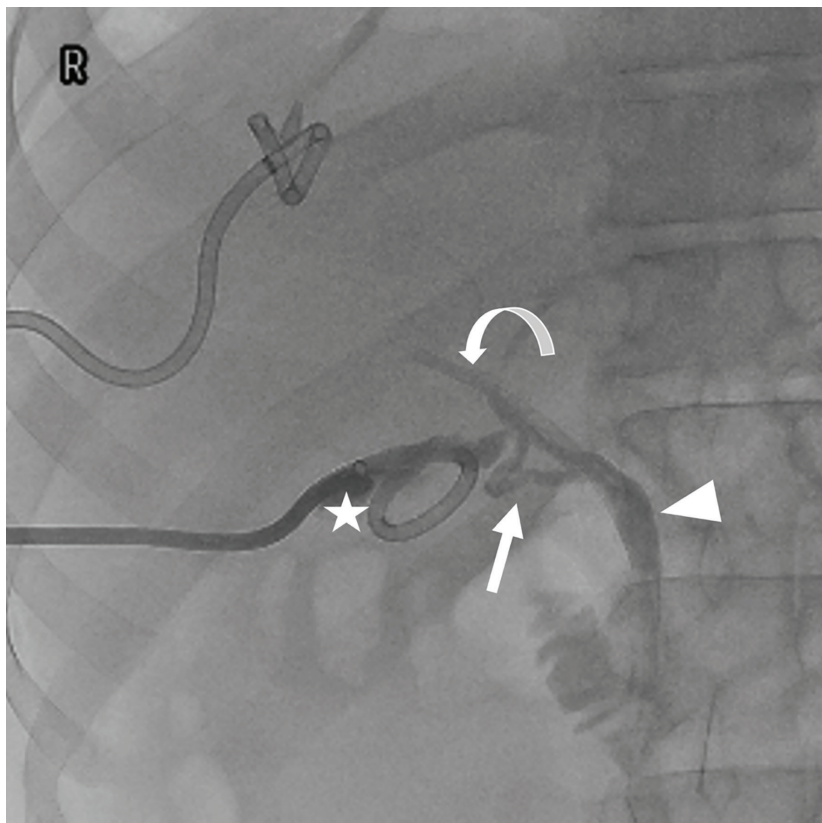


Figure 1. Contrast injection through the preexisting drainage catheter in biloma (asterisk) shows communication between the cystic duct (arrow) and common bile duct (arrowhead) with a preexisting stent in the common bile duct (curved arrow).

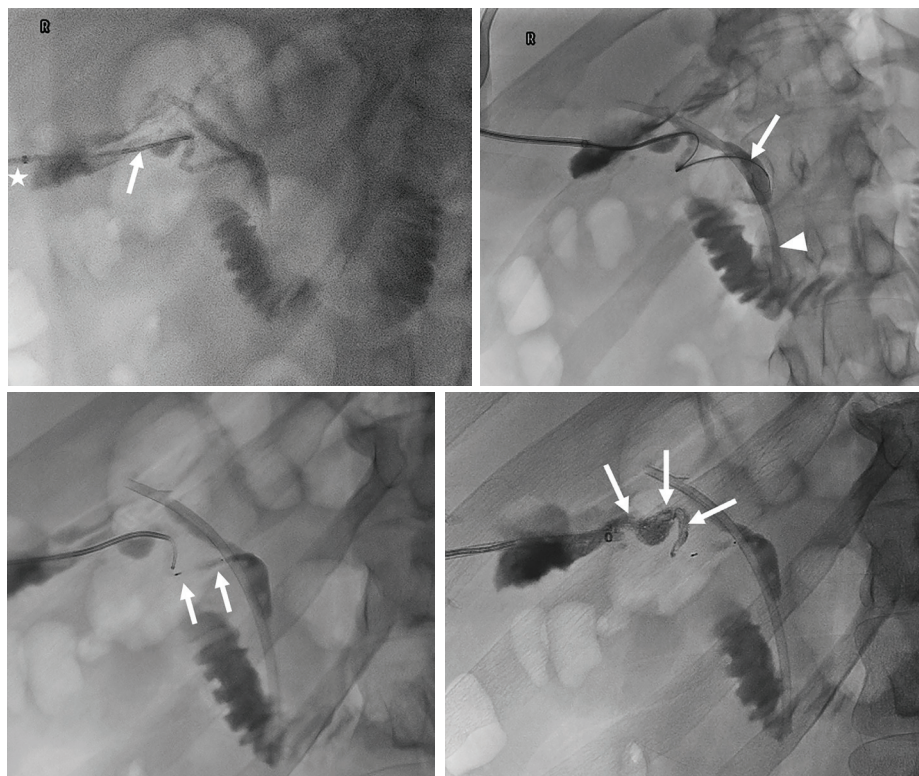


Figure 2. (a) Placement of a 5-French Kumpe catheter (arrow) with its tip at the distal cystic duct through a 6-French sheath (asterisk). (b) The 2.8-French microcatheter and microwire with its tip in the common bile duct (arrow). Note the preexisting common bile duct stent (arrowhead). (c) Embolization of the proximal cystic duct with MVP-3Q microvascular plug (arrows). (d) Embolization of the distal cystic duct with LAVA-34 liquid embolic material (arrows).

Main points

- Biliary complications following cholecystectomy can increase the risk of infection and biloma formation.
- A case report of a 48-year-old man who underwent cholecystectomy complicated by bile leak and biloma in the gallbladder fossa requiring drain placement is presented.
- The patient underwent percutaneous cystic duct embolization using the LAVA® Liquid Embolic System and microvascular plug following failed endoscopic retrograde cholangiopancreatography.

pouching extending from the gallbladder fossa biloma via a narrow tract. This superior outpouching was catheterized with a 0.035-in Glidewire and a 5-French Kumpe catheter. The bile content of this outpouching fluid collection was first gently aspirated, and the residual outpouching and the narrow tract were embolized with 1 mL of LAVA-34 LES using a 2.8-French Progreat microcatheter. A new 12-French Dawson Mueller drainage catheter was placed in the gallbladder fossa biloma, and gentle aspiration was applied to decompress its content (Figure 3).

The patient's abdominal pain improved, and the alkaline phosphatase level returned to normal the next day after the procedure. He was discharged from the hospital 3 days after the procedure. Following discharge, the patient reported minimal to no output from the drainage catheter, which was removed after 1 week following an abdominal CT that confirmed resolution of the gallbladder fossa biloma.

Discussion

Biliary complications following cholecystectomy are uncommon but present a risk of infection and biloma formation. Surgical intervention and ERCP with sphincterotomy and bile duct stent placement are typically the first-line treatments for managing these complications.² For patients who are not surgical candidates or in whom ERCP has failed, percutaneous interventions may be considered. These include decompression and diversion of bile by place-

ment of an internal-external biliary drain, or embolization of the leaking biliary tract.³ Percutaneous cystic duct embolization can be performed for the treatment of bile leaks from the cystic duct stump using various embolic materials, such as Gelfoam, coils, glue mixed with lipiodol, and microvascular plugs.⁴⁻⁷

Percutaneous cystic duct embolization may be performed via existing or newly established percutaneous transhepatic biliary access, or using a retrograde technique through a catheter placed in the gallbladder fossa for biloma drainage.⁴⁻⁶ In the present case, the cystic duct was accessed through an existing drainage catheter in the gallbladder fossa, and embolization was performed in a retrograde manner. The retrograde approach should be prioritized when a drainage catheter is already present in the gallbladder fossa, as this strategy avoids creating unnecessary new transhepatic biliary access through the intrahepatic and common bile ducts. However, interventional radiologists must exercise caution when using liquid embolic agents in the cystic duct using the retrograde technique, as there is a theoretically increased risk of migration of the liquid embolic agent resulting in non-target embolization of the common bile duct and occluding it.

In this case, we performed embolization of the cystic duct with a microvascular plug first to prevent migration of the LAVA LES, which was subsequently carefully injected. The LAVA LES has been Food and Drug Ad-

ministration-approved for embolization of peripheral arterial hemorrhages following a prospective multicenter study demonstrating its safety and efficacy.⁸ However, to our knowledge, its use for cystic duct embolization has not been reported previously. Future studies with a large sample size should be conducted to evaluate the safety and efficacy of LAVA LES for cystic duct embolization. Finally, the cystic duct embolization procedure should be considered in patients with persistent bile leak from the cystic duct stump following cholecystectomy, who may not be surgical candidates or have failed ERCP.

Footnotes

Conflict of interest disclosure

The authors declared no conflicts of interest.

References

1. Copelan A, Bahoura L, Tardy F, Kirsch M, Sokhandon F, Kapoor B. Etiology, diagnosis, and management of bilomas: a current update. *Tech Vasc Interv Radiol*. 2015;18(4):236-243. [\[Crossref\]](#)
2. Ahmad F, Saunders RN, Lloyd GM, Lloyd DM, Robertson GS. An algorithm for the management of bile leak following laparoscopic cholecystectomy. *Ann R Coll Surg Engl*. 2007;89(1):51-56. [\[Crossref\]](#)
3. Gunn AJ, Raborn J, Moawad S, Saddekni S, Kamel Abdel Aal AM. Percutaneous treatment of iatrogenic and traumatic injury of the biliary system. *Curr Trauma Rep*. 2017;3:196-206. [\[Crossref\]](#)
4. Abdel Aal AK, Jones DP, Caraway J, Moustafa AS, Moawad SM, Underwood ES. Percutaneous embolization of cystic duct stump leak following failed endoscopic management. *Radiol Case Rep*. 2017;12(4):786-789. [\[Crossref\]](#)
5. Giurazza F, Ierardi A, Spinazzola A, et al. Percutaneous embolization of biliary leaks: initial experience with extravascular application of a PTFE-covered microplug. *Cardiovasc Intervent Radiol*. 2023;46(3):400-405. [\[Crossref\]](#)
6. Nezami N, Jarmakani H, Arici M, et al. Selective trans-catheter coil embolization of cystic duct stump in post-cholecystectomy bile leak. *Dig Dis Sci*. 2019;64(11):3314-3320. [\[Crossref\]](#)
7. Kayali A. Transhepatic embolisation of the cystic duct stump with a glue and lipiodol mixture. *Cardiovasc Intervent Radiol*. 2023;46(5):689-691. [\[Crossref\]](#)
8. Arslan B, Razavi MK, Siskin G, Richard HM, Katz M, Lookstein R, et al. The LAVA study: a prospective, multicenter, single-arm study of a liquid embolic system for treatment of peripheral arterial hemorrhage. *J Vasc Interv Radiol*. 2025;36(3):436-445.e2. [\[Crossref\]](#)

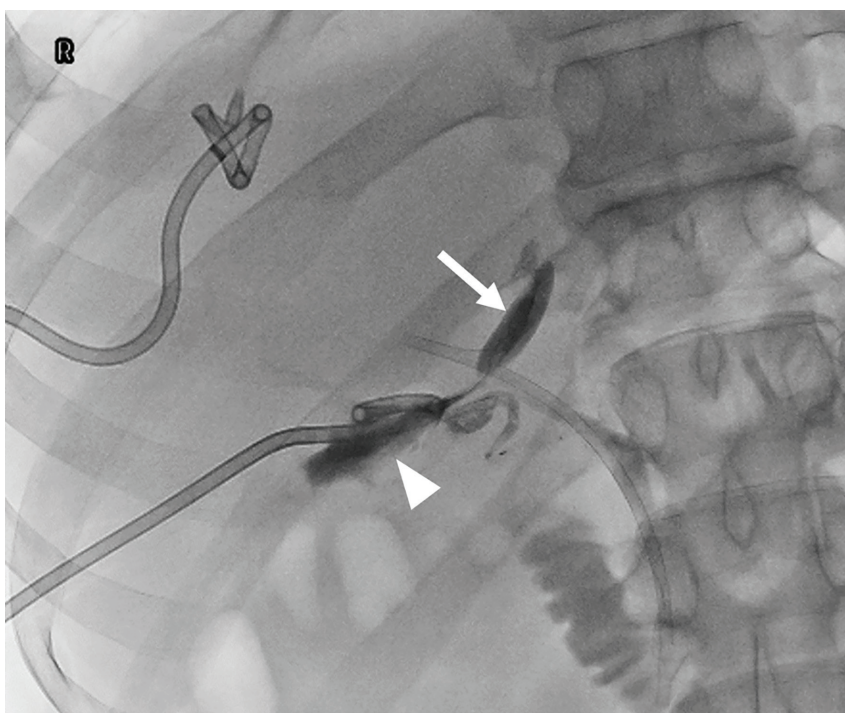


Figure 3. Decompression of the superior outpouching (arrow) and the remaining biloma cavity (arrowhead) with placement of a new 12-French Dawson Mueller catheter.