

Transjugular insertion of biliary stent in patients with malignant biliary obstruction complicated by ascites with/without coagulopathy: a prospective study of 12 patients

Dong Jae Shim 

Dong Il Gwon 

Gi-Young Ko 

Hyun-Ki Yoon 

Kyu-Bo Sung 

PURPOSE

In patients with malignant biliary obstruction complicated by massive ascites, when endoscopy fails, safe routes for biliary decompression are needed as an alternative to percutaneous approach. We aimed to evaluate the safety and effectiveness of transjugular insertion of biliary stent (TIBS) in patients with malignant biliary obstruction complicated by massive ascites with or without coagulopathy.

METHODS

From March 2012 to December 2017, a total of 12 consecutive patients with malignant biliary obstructions treated with TIBS were enrolled in this study. Five patients had jaundice and cholangitis, while seven had jaundice only. Clinical parameters including technical and clinical success rates and complications following TIBS were evaluated. Overall survival and stent occlusion-free survival were assessed using Kaplan-Meier analysis.

RESULTS

The indications for transjugular approach were massive ascites with (n=2) or without (n=10) coagulopathy. TIBS was technically successful in 11 of 12 patients. Clinical success was defined as successful internal drainage and was achieved in eight patients. The mean serum bilirubin level was initially 13.9 ± 6.3 mg/dL and decreased to 4.9 ± 5.3 mg/dL within 1 month after stent placement ($P = 0.037$). Two patients had procedure-related complications (hemobilia). During the follow-up period (mean, 30 days; range, 1–146 days), all 12 patients died of disease progression. The median overall survival and stent occlusion-free survival times were 19 days (95% confidence interval [CI], 16–22 days) and 19 days (95% CI, 12–26 days), respectively. There was no stent dysfunction in the eight patients that had successful internal drainage.

CONCLUSION

TIBS appears to be safe, technically feasible, and clinically effective for patients with malignant biliary obstruction complicated by massive ascites with or without coagulopathy.

Biliary drainage is essential for the palliation of malignant obstruction in biliary system (1, 2). Percutaneous transhepatic biliary drainage (PTBD) and metallic stent insertion have been used to manage malignant biliary obstruction when endoscopic approach is impossible (1); however, major complication rates of percutaneous biliary drainage have been as high as 5% in previous reports (3–6).

In particular, in patients with malignant biliary obstruction complicated by ascites, PTBD is contraindicated because of a high risk of intra-abdominal hemorrhage and bile peritonitis (4, 7). A single-session percutaneous procedure beginning with ascites drainage followed by metallic stent insertion and tract embolization can immediately relieve malignant biliary obstruction (8). However, the risk of complication is relatively high in patients with malignant biliary obstruction complicated by massive ascites and coagulopathy. Therefore, as an alternative method for those high-risk patients, a transjugular approach for biliary stent insertion was reported in previous studies with limited numbers of patients (9–11).

The purpose of our study was to evaluate the safety and effectiveness of transjugular insertion of biliary metallic stent (TIBS) in patients with malignant biliary obstruction complicated by massive ascites with or without coagulopathy.

From the Department of Radiology (D.J.S.), Incheon St. Mary's Hospital, The Catholic University of Korea School of Medicine, Seoul, Republic of Korea; Department of Radiology and Research Institute of Radiology (D.I.G. ✉ radgwon@amc.seoul.kr, G.Y.K., H.K.Y., K.B.S.), Ulsan University School of Medicine, Asan Medical Center, Seoul, Republic of Korea.

Received 31 October 2018; revision requested 21 December 2018; last revision received 19 February 2019; accepted 06 March 2019.

Published online 28 August 2019.

DOI 10.5152/dir.2019.18470

You may cite this article as: Shim DJ, Gwon DI, Ko GY, Yoon HK, Sung KB. Transjugular insertion of biliary stent in patients with malignant biliary obstruction complicated by ascites with/without coagulopathy: a prospective study of 12 patients. *Diagn Interv Radiol* 2019; DOI 10.5152/dir.2019.18470.

Methods

Patient population

The institutional review board of our institution approved this prospective study (S2013-0272-0001). Formal informed consents were obtained from each patient or legal guardian. Between March 2012 and December 2017, 12 consecutive patients (six men; mean age, 49 years; age range, 32–79 years) with malignant bile duct obstruction complicated by massive ascites with or without uncorrectable coagulopathy were enrolled. We included patients that had a malignant bile duct obstruction that could not be treated surgically because of unresectability, advanced stage, old age, or severe comorbidities; a previously unsuccessful endoscopic attempt to drain the obstructed bile ducts; and massive ascites with or without uncorrectable coagulopathy. Our exclusion criteria included minimal intrahepatic bile duct dilatation, multiple intrahepatic separation, and poor performance status (Eastern Cooperative Oncology Group performance status: grade 4).

Technique

Prior to TIBS, computed tomography (CT) or magnetic resonance cholangiopancreatography was performed to evaluate the hepatic anatomy and plan the most appropriate pathway for intervention. TIBS was performed with the patients under conscious sedation with intravenous pethidine hydrochloride (Demerol, Keukdong) and local anesthesia with subcutaneous lidocaine (Jeil Pharmaceuticals) injection. Intravenous antibiotics (Cefotaxime) were administered 2 hours before the procedure and for at least 48 hours after the procedure. The right internal jugular vein was accessed with a micro-

puncture set under the guidance of ultrasound. Then the venotomy site was serially dilated and a 9 French (F) sheath (Cook Medical) was inserted. A 5 F angiographic catheter was manipulated into the right hepatic vein. Biliary duct was accessed using Ring transjugular intrahepatic access set (RTPS-100, Cook Medical). The location of bile duct was approximated by referring pre-acquired CT. The right intrahepatic bile duct was punctured using a 16-gauge modified Colapinto needle (Cook Medical) under the guidance of fluoroscopy and then was negotiated with a 0.035-inch hydrophilic guidewire (Terumo). After passing the catheter into the biliary system, a cholangiography was performed to determine the location and length of the biliary obstruction. The obstructed biliary segment was traversed with the guidewire. The 9 F sheath was introduced immediately after cannulation of obstructed bile duct with guidewire and 5 F catheter. The 9 F sheath was carefully managed to keep the location during procedure and only removed at the end of the procedure. Pre-balloon dilatation was performed using an 8 mm balloon catheter (Mustang, Boston Scientific) in each of the patients.

Uncovered self-expandable metallic stents with a diameter of 10 mm or 12 mm (Zilver, Cook Medical) were initially deployed across the obstruction so as to cover the biliary duct at a position approximately 2–4 cm proximal to the steno-occlusion to prevent overgrowth of tumor. In all patients, the distal portion of the stent was placed across the papilla to bridge the duodenum. If cholangiogram taken immediately after stent placement did not demonstrate fluent contrast media passage because of immediate tissue ingrowth into the stent, an additional covered stent (GD stents, TaeWoong Medical) was placed. Very little bile reflux to systemic vein seemed to occur during stent placement because of the TIPS sheath tamponading the tract. Prior to sheath removal, we aspirated the remaining bile juice in the biliary system as much as possible. The sheath was removed if completion cholangiography demonstrated good contrast media passage through the stent into the duodenum (Fig. 1). In the first 3 patients, parenchymal tract embolization was performed using coils prior to sheath removal.

Follow-up

The patients underwent clinical evaluation in association with regular chemotherapy including measurements of total serum bili-

rubin levels at our outpatient clinic at 1 and 3 days and 1, 2, 3, and 6 months after the procedure, or if there were unexpected symptoms such as jaundice, fever, or pain. Contrast-enhanced multiphase computed tomography scan was performed within 1 month after TIBS. Beginning 6 months after TIBS, we reviewed the medical record or interviewed each patient or guardian by telephone about patient condition to assess overall survival and stent occlusion-free survival. Complications were diagnosed based on clinical examinations or imaging modalities.

Definitions and study endpoints

Technical success was defined as successful puncture of the intrahepatic bile duct and subsequent placement of the biliary stent in an appropriate position. Complications were classified as major or minor according to the guidelines of the Society of Interventional Radiology Standards of Practice Committee (12). Clinical success was defined as achieving successful internal drainage when serum bilirubin level decreases to <75% of the pre-treatment value within the first month following stent placement (13). Patients' overall survival time was defined as the interval between the stent placement and death. Stent occlusion-free survival (or stent patency) was defined as the time interval between the stent placement and recurrence of the obstruction or death. Stent occlusion was defined as a radiologically confirmed biliary obstruction with serum bilirubin levels >3 mg/dL or any condition requiring repeat intervention to improve jaundice.

Statistical analysis

A Wilcoxon signed ranks test was used to compare pre- and postprocedural serum bilirubin levels. A Kaplan-Meier survival analysis was used to assess stent occlusion-free survival and overall survival times. A Fisher's exact test was performed to evaluate the effect of tract embolization on complications. All data analyses were performed using the SPSS statistical software (version 17.0; SPSS Inc.) and considered $P < 0.05$ to be statistically significant.

Results

During the study period, a total of 12 patients were eligible for this study and all patients were included. The baseline demographics are presented in Table 1. The most common underlying disease was ad-

Main points

- Biliary stent via transjugular approach was successfully placed in 11 of 12 patients with malignant biliary obstruction complicated by massive ascites with or without coagulopathy.
- Successful internal drainage was achieved in 8 patients (72.7%) and major complication (hemobilia) occurred in 2 patients.
- In patients with malignant biliary obstruction complicated by massive ascites with or without coagulopathy, transjugular approach seems to be a technically safe and effective alternative to percutaneous transhepatic approach.

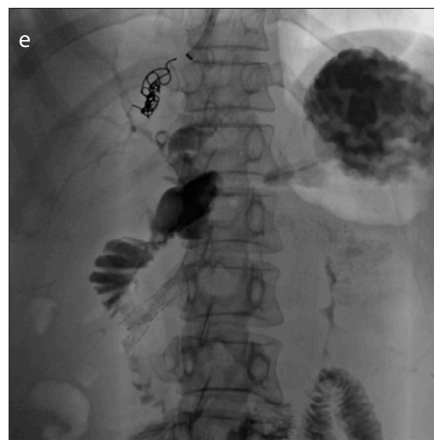
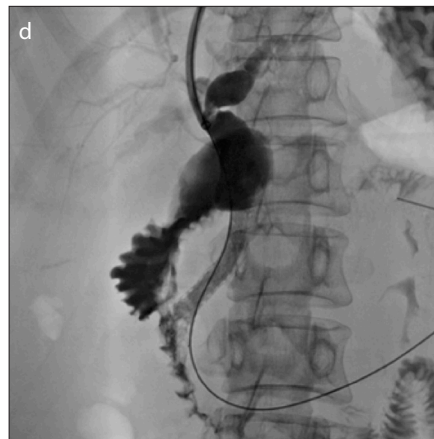
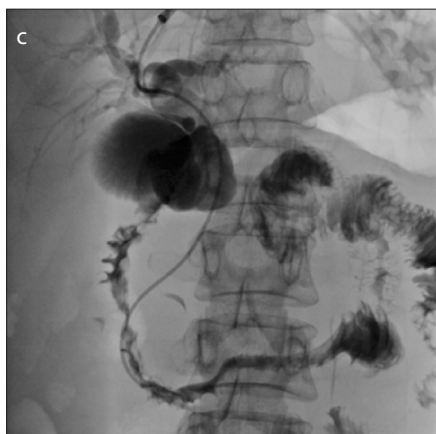
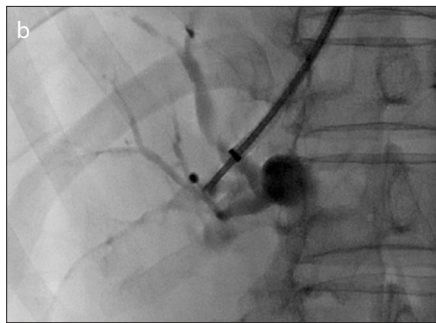
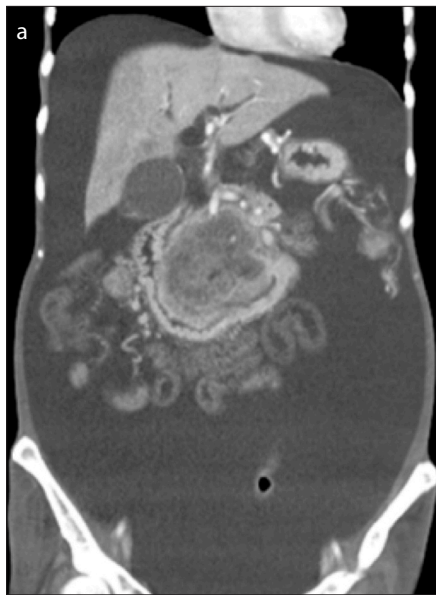


Figure 1. a–e. A 40-year-old female with pancreatic cancer and multiple metastases presented with jaundice and ascites (Patient 2). Coronal reconstructed computed tomography image (a) shows diffuse bile duct dilatation and massive ascites. Cholangiography (b) obtained after cannulation of the bile duct using a Colapinto needle shows dilatation of the bile duct and ensures successful biliary access. In image (c), the obstructed bile duct segment was traversed up to the duodenum using a 0.035-inch hydrophilic guidewire and 5 F catheter. Subsequent jejunography showed that the lower intestinal tract was free of obstruction (not shown). A self-expandable bare metallic stent (10×80 mm) was successfully placed across the distal bile duct obstruction (d). Completion radiograph (e) shows good contrast media passage to the jejunum and multiple coils between the hepatic vein and biliary duct for tract embolization.

vanced gastric cancer (n=9) followed by pancreatic cancer (n=2) and colorectal cancer (n=1). Seven patients had the symptom of jaundice only, while five patients presented with jaundice and cholangitis. The average length of obstructed segment was 38 mm (range, 13–70 mm). The indications for transjugular approach were massive ascites in 10 patients and massive ascites with uncorrectable coagulopathy (prothrombin

time, 58% and 40%) that was unresponsive to appropriate management in two patients. Clinical outcomes are presented in Table 2. The mean number of attempts needed to achieve bile duct puncture from the right hepatic vein was 3.4 (range, 1–6). Subsequent stent placement was technically successful in 11 of 12 patients. In one patient, puncture of the intrahepatic bile duct failed because of mild duct dilatation and

unfavorable anatomy. In that patient, we subsequently performed left PTBD and metallic stent insertion; however, the patient had hemobilia after stent insertion and died after 5 days, although following cholangiogram demonstrated well-preserved function of the stent.

To relieve the malignant biliary obstruction, a single uncovered stent was sufficient in 5 patients. In 5 other patients, two (n=4) or three (n=1) uncovered stents were placed for long segmental occlusion. In one patient, after placing two uncovered stents, one covered stent was placed because of immediate dysfunction of an uncovered stent. Embolization of the parenchymal tract was performed using coils only in the first 3 patients. In the 8 patients that did not receive embolization of the parenchymal tract, neither immediate hemobilia on fluoroscopy nor sepsis was observed during the hospital stay, except for one patient with hemobilia.

Procedure-related major complications (hemobilia) occurred in two patients during bile duct puncture and might have been caused by portal venous bleeding. One of those patients died on the first day after the procedure. It was not clear whether the cause of death was complication due to the procedure or progression of the underlying sepsis. The second patient with major complications had unstable vital signs after the procedure and did not respond to transfusion, which was suggestive of hemobilia; however, the patient refused further management and died 20 days after the procedure. None of the patients experienced minor complications. There was no significant difference in complication rate between the group of tract embolization and nonembolization on Fisher's exact test ($P = 0.491$).

Among the 11 patients with technical success, 3 had a progressive increase in serum bilirubin level due to hemobilia (n=2) or unknown cause (n=1). Therefore, clinical success was achieved in 8 patients. The mean serum bilirubin level was initially 13.9 ± 6.3 mg/dL and decreased to 4.9 ± 5.3 mg/dL within 1 month after stent placement in the 11 patients with technical success ($P = 0.037$).

Clinical follow-up until death or the end of the study was available for all patients and lasted 1–146 days (mean, 30 days). All 11 patients died within the follow-up period. The median overall survival time was 19 days (95% confidence interval [CI],

Table 1. Patient characteristics

Patient/age/sex	Underlying disease	INR	CRP (mg/L)	Cholangitis (Fever/sepsis)	Obstruction level	Stents (mm)*
1/45/F	Advanced gastric cancer	1.04	1.37	-	CBD	10×100
2/40/F	Pancreatic cancer	1.03	2.77	-	CBD	10×80
3/61/F	Pancreatic cancer	1.28	18.40	Sepsis	CBD	10×60, 10×80
4/63/M	Advanced gastric cancer	1.10	9.28	Fever	CBD	12×80
5/54/M	Advanced gastric cancer	1.20	2.04	-	CHD	10×40, 10×80, 12×80
6/43/F	Advanced gastric cancer	1.09	2.18	-	CHD	10×40, 10×60
7/39/F	Advanced gastric cancer	1.33	0.82	-	CBD	10×180
8/43/M	Advanced gastric cancer	0.96	0.13	-	CBD	10×80, 10×180
9/60/M	Advanced gastric cancer	1.09	11.18	-	CBD	10×60, 10×80
10/32/M	Colorectal cancer	1.13	9.63	-	Hilar	10×80
11/34/F	Advanced gastric cancer	1.78	6.06	-	CBD	10×100, 10×90
12/79/M	Advanced gastric cancer	0.98	10.94	-	CBD	10×40, 10×100

INR, international normalized ratio; CRP, C-reactive protein; F, female; M, male; CBD, common bile duct; CHD, common hepatic duct.
*Diameter × Length.

Table 2. Clinical outcomes of TIBS

Patient no	Technical success	Bilirubin (mg/dL)		Tract embolization	Complications	Stent patency (days)	Clinical success	Overall survival (days)
		Before TIBS	Follow-up within 1 month					
1	Yes	28.8	2.4	Coil	No	18	Yes	18
2	Yes	12.5	9.0	Coil	No	23	Yes	23
3	Yes	16.5	N/A	Coil	Hemobilia	1	N/A	1
4	Yes	6.9	13.5	No	Hemobilia	20	No	20
5	Yes	17.5	1.1	No	No	26	Yes	26
6	Yes	16.8	1.8	No	No	19	Yes	19
7	Yes	12.5	0.4	No	No	146	Yes	146
8	Yes	8.6	0.5	No	No	48	Yes	48
9	Yes	8.9	2.9	No	No	11	Yes	11
10	Yes	7.8	14.3	No	No	39	No	39
11	Yes	15.7	2.9	No	No	6	Yes	6
12	No	8.5	5.5*	N/A	No	5	No	5

TIBS, transjugular insertion of biliary stent; N/A, not available.

* The patient underwent metallic stent placement via a percutaneous approach.

16–22 days; Fig. 2). The median stent occlusion-free survival was 19 days (95% CI, 12–26 days; Fig. 3). Stent occlusion did not occur in any of the 8 patients that had successful internal drainage.

Discussion

In patients with malignant bile duct obstruction complicated by coagulopathy and massive ascites, percutaneous approach involves potential risk of hemobilia

and peritoneal bleeding or bile peritonitis, respectively, even after preprocedural management (4, 14). Even with successful PTBD, malignant ascites tends to increase, and PTBD can cause problems such as entry-site

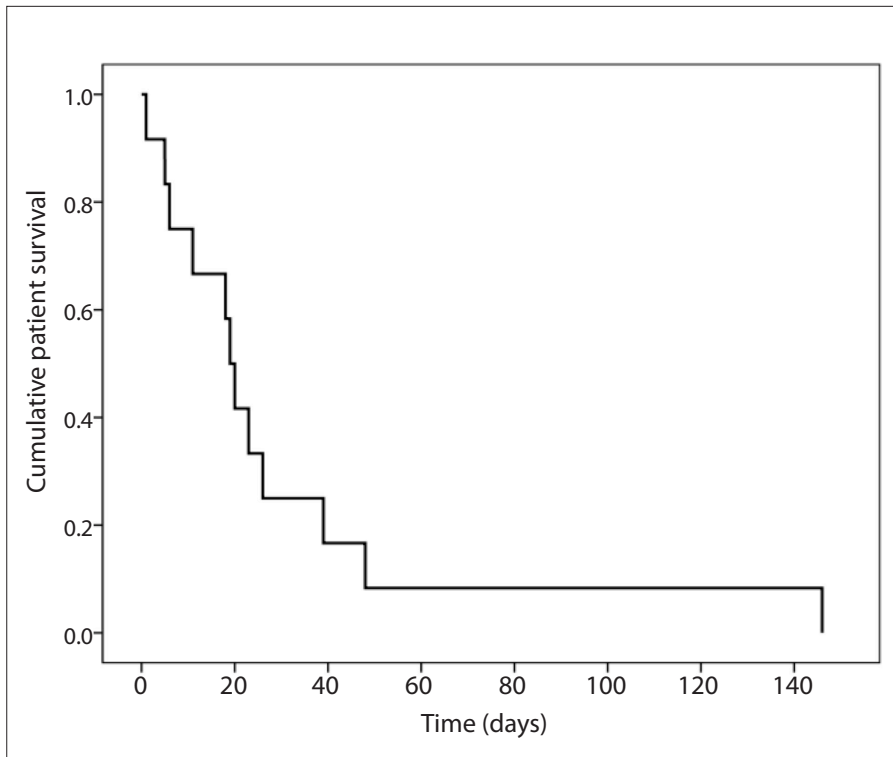


Figure 2. Kaplan-Meier survival curve of patients' overall survival.

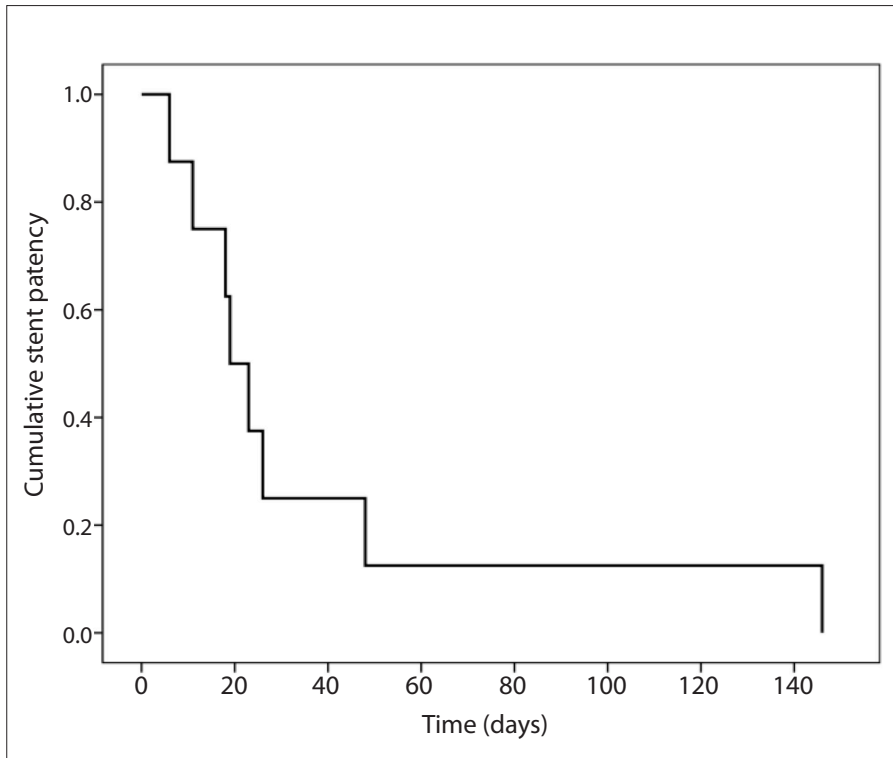


Figure 3. Kaplan-Meier survival curve of stent occlusion-free survival.

leakage and catheter buckling (11). There is a limited number of treatment options to overcome the potential risks. Previous investigations reported about percutaneous biliary stent placement with subsequent

tract embolization in a single session (4, 8, 14). In those studies, the technical and clinical success rates were 96%–100% and 87.5%–88%, respectively. Although these results suggested that this method may be

a reasonable option, the complication rates were relatively high (24%–43.7%).

To avoid the potential risks of percutaneous approach, a few small studies investigated the use of TIBS (10, 11, 15). Since Ring et al. (10) first described one case in 1991, Amygdalos et al. (15) reported two, and Tsauo et al. (11) reported 6 cases. Among the previous cases, technical and clinical successes were achieved in all patients except one (10, 11, 15). TIBS requires little time to control ascites and correct coagulopathy. Therefore, TIBS can provide early biliary drainage before aggravation of biliary sepsis.

In our study, bile duct puncture and subsequent stent deployment was technically successful in 11 of 12 patients and required an average of 3.4 attempts for puncture. The introducer system of TIBS is 9 F in diameter, which can be considered an acceptable size. The use of small caliber needle in Rösch-Uchida transjugular liver access set (14-gauge, Cook) may be helpful for prevention of hemobilia. The median overall survival and stent occlusion-free survival times were both 19 days and these results were probably associated with advanced-stage disease and presence of ascites, which was reported as a poor prognostic factor (16).

In a previous study, Tsauo et al. (11) embolized the tract with gelfoam because TIBS may increase the risk of sepsis. In our study, regardless of embolization, we did not observe sepsis following TIBS. We postulate that bile aspiration immediately after stent placement could gain time for closure of the parenchymal tract, and aspiration itself could prevent retrograde bile reflux. Moreover, we did not observe any significant hemobilia in the bile duct, and only a minimal amount of contrast media from the hepatic vein remained after removal of the introducer system. Therefore, sufficient bile aspiration at the final stage of the procedure is important to prevent potential complications. In our study, the major complication and clinical success rates were 16.7% and 72.7%, respectively, which is in good agreement with the results of previous studies using percutaneous self-expandable metallic stents (complication rates, 0%–28%; clinical success rates, 80%–88%) (17–19). Recently endoscopic ultrasound-guided biliary drainage (EUS-BD, choledochoduodenostomy or hepaticogastrostomy) were attempted in patients with failed endoscopic approach and showed better clinical success than PTBD (20). Alvarez-Sánchez, et

al. (21) reported on the feasibility of EUS-BD in patients with malignant biliary obstruction complicated by ascites in a pilot study. It is difficult to compare TIBS and EUS-BD because both were performed on a limited number of patients; however, both modalities can be good alternatives for those patients with contraindications to PTBD.

Our study had several limitations. First, the number of patients included was too small to allow general conclusions regarding the technical and clinical effectiveness of TIBS. Second, the median overall survival time was only 19 days, which limited our ability to observe the long-term stent occlusion-free survival. Third, the lack of a control group who underwent ascites drainage followed by PTBD and then parenchymal tract embolization can be another limitation.

In conclusion, TIBS appears to be safe, technically feasible, and clinically effective for the treatment of patients with malignant biliary obstruction complicated by massive ascites with or without coagulopathy.

Financial disclosure

This research was supported by Cook medical Korea.

Conflict of interest disclosure

The authors declared no conflicts of interest.

References

1. Lorenz JM. Management of malignant biliary obstruction. *Semin Intervent Radiol* 2016; 33:259–267. [\[CrossRef\]](#)
2. Tsetis D, Krokidis M, Negru D, Prassopoulos P. Malignant biliary obstruction: the current role of interventional radiology. *Ann Gastroenterol* 2016; 29:33–36.
3. Hamlin J, Friedman M, Stein M, Bray J. Percutaneous biliary drainage: complications of 118 consecutive catheterizations. *Radiology* 1986; 158:199–202. [\[CrossRef\]](#)
4. Sofue K, Arai Y, Takeuchi Y, Fujiwara H, Tokue H, Sugimura K. Safety and efficacy of primary metallic biliary stent placement with tract embolization in patients with massive ascites: a retrospective analysis of 16 patients. *J Vasc Interv Radiol* 2012; 23:521–527. [\[CrossRef\]](#)
5. Saad WE, Wallace MJ, Wojak JC, Kundu S, Cardella JF. Quality improvement guidelines for percutaneous transhepatic cholangiography, biliary drainage, and percutaneous cholecystostomy. *J Vasc Interv Radiol* 2010; 21:789–795. [\[CrossRef\]](#)
6. Choi SH, Gwon DI, Ko G-Y, et al. Hepatic arterial injuries in 3110 patients following percutaneous transhepatic biliary drainage. *Radiology* 2011; 261:969–975. [\[CrossRef\]](#)
7. Patel V, McLaughlin SW, Shlansky-Goldberg R, et al. Complication rates of percutaneous biliary drainage in the presence of ascites. *Abdom Radiol* 2019; 44:1901–1906. [\[CrossRef\]](#)
8. Seif HM, Zidan M, Helmy A. One-stage percutaneous triple procedure for treatment of endoscopically unmanageable patients with malignant biliary obstruction and marked ascites. *Arab J Gastroenterol* 2013; 14:148–153. [\[CrossRef\]](#)
9. Rosch J, Antonovic R, Dotter C. Transjugular approach to the liver, biliary system, and portal circulation. *Am J Roentgenol Radium Ther Nucl Med* 1975; 125:602–608. [\[CrossRef\]](#)
10. Ring E, Gordon R, LaBerge J, Shapiro H. Malignant biliary obstruction complicated by ascites: transjugular insertion of an expandable metallic endoprosthesis. *Radiology* 1991; 80:579–581. [\[CrossRef\]](#)
11. Tsao J, Li X, Li H, et al. Transjugular insertion of bare-metal biliary stent for the treatment of distal malignant obstructive jaundice complicated by coagulopathy. *Cardiovasc Intervent Radiol* 2013; 36:521–525. [\[CrossRef\]](#)
12. Dariushnia SR, Haskal ZJ, Midia M, et al. Quality improvement guidelines for transjugular intrahepatic portosystemic shunts. *J Vasc Interv Radiol* 2016; 27:1–7. [\[CrossRef\]](#)
13. Gwon DI, Ko G-Y, Kim JH, et al. Percutaneous bilateral metallic stent placement using a stent-in-stent deployment technique in patients with malignant hilar biliary obstruction. *AJR Am J Roentgenol* 2013; 200:909–914. [\[CrossRef\]](#)
14. Cekirge S, Akhan O, Ozmen M, Saatçi I, Besim A. Malignant biliary obstruction complicated by ascites: closure of the transhepatic tract with cyanoacrylate glue after placement of an endoprosthesis. *Cardiovasc Intervent Radiol* 1997; 20:228–231. [\[CrossRef\]](#)
15. Amygdalos MA, Haskal ZJ, Cope C, Kadish SL, Long WB. Transjugular insertion of biliary stents (TIBS) in two patients with malignant obstruction, ascites, and coagulopathy. *Cardiovasc Intervent Radiol* 1996; 19:107–109. [\[CrossRef\]](#)
16. Tuğan W, Innabi A, Alawneh A, Farsakh FA, Al-Khatib M. Prediction of survival following percutaneous biliary drainage for malignant biliary obstruction. *J Transl Int Med* 2017; 5:127–131. [\[CrossRef\]](#)
17. Gordon R, Ring E, LaBerge J, Doherty M. Malignant biliary obstruction: treatment with expandable metallic stents—follow-up of 50 consecutive patients. *Radiology* 1992; 182:697–701. [\[CrossRef\]](#)
18. Lee BH, Choe DH, Lee JH, Kim KH, Chin S. Metallic stents in malignant biliary obstruction: prospective long-term clinical results. *AJR Am J Roentgenol* 1997; 168:741–745. [\[CrossRef\]](#)
19. Inal M, Akgül E, Aksungur E, Demiryürek H, Yağmur Ö. Percutaneous self-expandable uncovered metallic stents in malignant biliary obstruction. *Acta Radiol* 2003; 44:139–146. [\[CrossRef\]](#)
20. Sharaiha RZ, Khan MA, Kamal F, et al. Efficacy and safety of EUS-guided biliary drainage in comparison with percutaneous biliary drainage when ERCP fails: a systematic review and meta-analysis. *Gastroint Endosc* 2017; 85:904–914. [\[CrossRef\]](#)
21. Alvarez-Sánchez MV, Luna O, Oria I, et al. Feasibility and safety of endoscopic ultrasound-guided biliary drainage (EUS-BD) for malignant biliary obstruction associated with ascites: results of a pilot study. *J Gastrointest Surg* 2018; 22:1213–1220. [\[CrossRef\]](#)