

Transcatheter arterial embolization for postoperative arterial complications after pelvic or hip surgery

Kai Wang* 

Ji Zhou* 

Xiang-Shu Chen 

Ying-Ying Zhang 

Xiao-Xin Peng 

Wei-Jian Jiang 

PURPOSE

We aimed to study the technical and clinical outcome of urgent transcatheter arterial embolization (TAE) for postoperative arterial complications after pelvic or hip surgery, and to accumulate additional experience about the role of embolization for these injuries.

METHODS

Patients who received TAE procedure for arterial complications after pelvic or hip surgery between September 1st, 2002 and December 1st, 2014 were screened on medical records and included in the analysis. Angiographic findings included active contrast agent extravasation, pseudoaneurysm formation, arteriovenous fistula, and other suspicious signs such as sighting of coarse margin or distortion of vessels. Embolic agents consisted of coils, gelatin sponge, and polyvinyl alcohol. Technical success was defined as complete occlusion of targeted artery through angiography, and clinical success as sustained resolution of symptoms.

RESULTS

A total of 22 patients (15 males, 19–76 years old) were enrolled. Prior to TAE, 12 patients developed hemorrhagic shock and the remaining 10 patients had hemorrhage-related pain, hematoma, or anemia. Contrast agent extravasation occurred in 12 cases, pseudoaneurysm formation in 5 cases, and other suspicious signs in 5 cases. Injury occurred in the internal iliac artery stem in 6 cases, inferior gluteal artery in 6 cases and superior gluteal artery in 6 cases. Multiple vascular lesions appeared in 5 cases. After TAE, technical success occurred in 22 patients and clinical success in 21 patients (95.5%). A 36-year-old woman died of irreversible multiple organ failure; no other severe procedure-related complications were recorded.

CONCLUSION

TAE is safe and effective for postoperative arterial complications after pelvic or hip surgery.

Arterial complication after pelvic or hip surgery is a rare condition, with an incidence less than 0.5% (1). The probable mechanisms of arterial injury include invasive surgery, prosthesis implantation, and coagulation disorder (2). Arterial complication could be life-threatening because of rapid progress of hemodynamic instability (3); therefore seeking an urgent and effective countermeasure of definite bleeding control is essential for clinicians.

Compared with traditional surgical intervention, TAE procedure has several significant advantages, such as minimal invasiveness, earlier recovery of physical activity, and no need of general anesthesia (4, 5). However, the current literature evaluating TAE outcome as remedial measure for surgical complication is predominantly composed of case reports or series on multimodal endovascular treatments (6–9). Moreover, the awareness of and the willingness to try this treatment among orthopedic surgeons seems poor, because many orthopedic surgeons have not encountered any such cases and TAE procedures are usually performed by interventional radiologists (10). Therefore, a case series with better homogeneity would help to enrich the related clinical experience.

TAE is often applied as the primary strategy for iatrogenic arterial injury in our hospital. Herein, we aimed to evaluate the safety and effectiveness of TAE for arterial complications

From the Department of Vascular Neurosurgery (K.W., J.Z., Y.Y.Z., W.J.J. ✉ cjr.jiangweijian@vip.163.com), New Era Stroke Care and Research Institute, the General Hospital of the PLA Rocket Force, Beijing, China; Department of Radiology, (X.S.C., X.X.P. ✉ jstpeng@sina.com), Beijing Jishuitan Hospital, Beijing, China.

*These authors contributed equally to this study.

Received 4 June 2018; revision requested 11 July 2018; last revision received 17 August 2018; accepted 1 September 2018.

Published online 25 March 2019.

DOI 10.5152/dir.2019.18212

You may cite this article as: Wang K, Zhou J, Chen XS, Zhang YY, Peng XX, Jiang WJ. Transcatheter arterial embolization for postoperative arterial complications after pelvic or hip surgery. *Diagn Interv Radiol* 2019; DOI 10.5152/dir.2019.18212.

after pelvic or hip surgery and to accumulate additional experience about the role of embolization for these injuries.

Methods

Patients

Patients who received TAE procedure for postoperative arterial complications after pelvic or hip surgery were investigated. Imaging data of all TAE procedures were prospectively preserved and classified according to bleeding site. We further reviewed medical records through image ID instead of keyword retrieval. The criteria for inclusion in the study were as follows: pelvic or hip surgery, complicated with suspected massive bleeding through local or systemic signs (paresthesia, a nonhealing wound, hematoma, anemia or hemorrhagic shock); arterial injuries (active contrast agent extravasation, pseudoaneurysm formation, arteriovenous fistula, and other suspicious signs) confirmed by angiography and followed by TAE surgery. The present study does not include patients who received treatments other than embolization. The study has been approved by the hospital ethics committee. All conscious patients signed informed consent for TAE treatment. All procedures performed in studies involving human participants were in accordance with the ethical standards of the institutional and national research committee and with the 1964 Helsinki declaration and its later amendments or comparable ethical standards.

A total of 362 patients received interventional embolization between September 1st, 2002 and December 1st, 2014. Of them, 96 patients received embolization for arterial injuries in the pelvic or hip zone. Excluding 74 cases of traumatic pel-

vic bleeding or preoperative prophylactic embolization, 22 patients (15 males, 19 to 76 years old) receiving TAE procedure for arterial complications after pelvic or hip surgery were included in the present study. Prior to TAE, 12 patients developed hemorrhagic shock and the remaining 10 suffered from hemorrhage-related pain, hematoma, or anemia.

TAE procedure

After local anesthesia, 13 cases of ipsilateral femoral artery access were routinely performed, and the other 9 cases were performed via contralateral femoral artery access. After placing 5 French sheath (Terumo), access to the ipsilateral common iliac artery was gained using 0.035-inch hydrophilic guidewires and 4 French catheters (Terumo). Nonselective and selective diagnostic angiography of iliac artery and branches was performed using Ultravist 300 contrast agent. The arterial and delayed phases (8–10 cardiac cycles) were observed. Abnormal angiographic findings included active contrast agent extravasation, pseudoaneurysm formation, arteriovenous fistula (11), and other suspicious signs (sighting of coarse margin or distortion of vessels).

Embolization was performed by an interventional radiologist with 25 years of clinical experience in endovascular intervention. For definite hemorrhagic lesions, superselective embolization was performed in proximity to the culprit artery branch. For suspected hemorrhagic lesions, target vessel or proximity trunk artery were embolized to avoid occult bleeding. Coils, gelatin sponge, or polyvinyl alcohol was selected depending on the site of injury, vessel size, and therapeutic purpose. For the purpose of temporary blocking active extravasation of small sized arteries, gelatin sponge or polyvinyl alcohol was selected. For trunk arteries with large blood flow, coils followed by gelatin sponge or polyvinyl alcohol were preferred the most. The success of procedure was confirmed by angiography and repeated TAE was carried out when necessary. Additionally, contralateral angiography was performed to confirm no collateral vessels to injured artery. For patients undergoing arterial embolization, such as the unilateral external iliac artery, the femoral artery, or the bilateral internal iliac artery, ischemia of limbs or organs were closely monitored and readied for bypass surgery.

Outcome assessment

During hospitalization, continuous monitoring of symptoms was performed after the endovascular procedure, any related abnormality was recorded in detail. Thirty-day follow-up of symptoms and complications (early or delayed recurrence of hematoma or bleeding, functional organ deficits, coils migration and backwash, inherent symptoms like pain and infection, nontarget embolization, and skin or periarticular tissue necrosis) was completed by outpatient visits or telephone interviews.

Technical success was defined as complete occlusion of targeted artery through angiography at the end of intervention. Clinical success was defined as the sustained resolution of symptoms (without repeated endovascular treatments or subsequent surgical intervention) from 24 hours after procedure to discharge (range, 7–28 days). Short-term complication was classified according to in-hospital medical records and 30-day follow-up results.

Results

Demographics and procedural details are summarized in Table 1, and a typical case is shown in Fig. Angiography examination revealed 12 patients with contrast agent extravasation, 5 patients with pseudoaneurysm formation and 5 patients with other suspicious signs. Contrast agent extravasation accounted for most of the hemodynamically unstable cases (66.6%, 8/12). The most commonly injured vessels were the internal iliac artery stem in 6 cases, inferior gluteal artery in 6 cases, and superior gluteal artery in 6 cases. Multiple vascular lesions appeared in 5 cases.

TAE was the only endovascular treatment used. Embolic materials included coils, gelatin sponge, and polyvinyl alcohol. As soon as the embolic procedure was over, active bleeding signs were no longer detected in any of the patients, yielding a technical success rate of 100%. Within 24 hours of endovascular procedure, 21 of 22 patients achieved sustained resolution of symptoms, yielding a clinical success rate of 95.5%.

A 36-year-old woman received a technically successful embolization of internal iliac artery trunk, but the hemodynamic instability persisted. Five hours after embolization, repeated angiography was carried out in order to find out the source of bleeding. However, no signs of arterial injury were found and previous embolization was

Main points

- Arterial complication after orthopedic surgery is rare (less than 0.5%), and occurs mostly after pelvic or hip surgeries.
- The current literature evaluating transarterial embolization (TAE) outcome as a remedial measure for surgical complication is infrequent, and the awareness of and willingness for trying this treatment among orthopedic surgeons seems poor.
- TAE is a safe, feasible, and lifesaving strategy for postoperative arterial complications after pelvic or hip surgery and should be considered as the first option because of its minimal invasiveness and lack of complications.

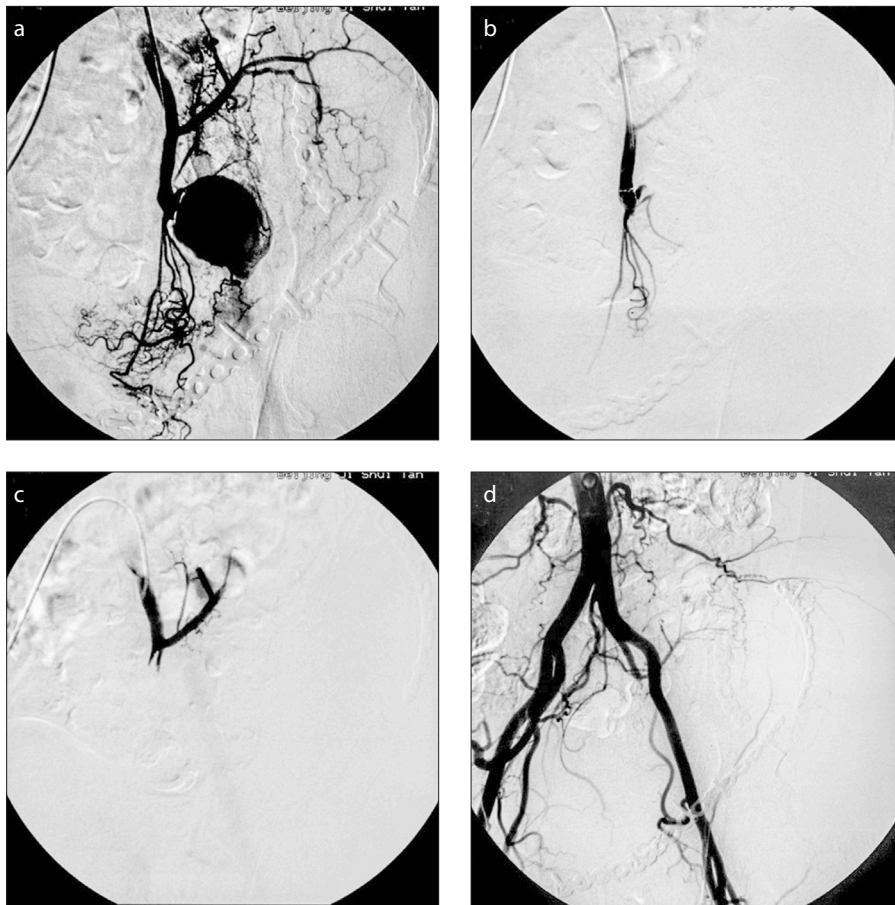


Figure. a–d. A 51-year-old man with gluteal hematoma after pelvic internal fixation. Angiography of internal iliac artery (a) shows pseudoaneurysm of superior gluteal artery and agent extravasation from iliolumbar artery. Panel (b) shows embolization of distal internal iliac artery using coils followed by gelatin sponge through 3-F PROGREAT microcatheter. Postembolization selective angiogram demonstrated no contrast agent filling in pseudoaneurysm. After selective embolization for branches of iliolumbar artery using gelatin sponge (c), contrast agent extravasation is no longer detected from angiography. Aorta angiography (d) further demonstrates the technical success of procedure.

reliable through angiography, therefore repeat embolization was not carried out. Unfortunately the patient finally died of irreversible multiple organ failure.

No other severe procedure-related complications were recorded.

Discussion

The diagnostic and therapeutic role of endovascular treatment has been shown by several previous case reports and series (8, 12–16). However, the satisfying outcome of especially TAE for iatrogenic arterial complications is patchy, and the awareness of and willingness for that treatment among orthopedic surgeons seems poor, because relevant studies were infrequently reported (10, 17). Additional single-center experience with high homogeneity is valuable for expanding clinical experience. Herein, through retrospective analysis of 22 un-

common clinical cases in a single center, we found TAE to be a safe, feasible, and lifesaving strategy for postoperative arterial complications after pelvic or hip surgery, with a technical success rate of 100% and a clinical success rate of 95.5%. Our results, together with the previously published results (summarized in Table 2) (10, 17–20), contributes to the recommendation of TAE for postoperative arterial complications after pelvic or hip surgery.

With the improvement of embolization techniques and the experience accumulated by interventional radiologists, clinicians pay more and more attention to endovascular therapy of iatrogenic arterial injury. Traditionally, surgical vascular intervention was considered as the primary choice (13). However, some disadvantages of traditional vascular surgery cannot be ignored: surgical exploration may not be effective,

because the source of the bleeding is not always easy to clarify (21); re-operation will increase the risk of complications such as deep infection or anatomic distortion from a pseudoaneurysm (22). Nowadays, from the view point of the interventional radiologists, TAE is worth trying as long as the patient's hemodynamics tend to be stable and can tolerate minimally invasive surgery. Only in patients with malignant hemodynamic instability, damage control surgery (e.g., pelvic packing) remains as the first choice (23).

Early recognition of postoperative bleeding is important because of the possibility to develop serious sequelae. Contrast-enhanced computed tomography (CT) or CT angiography is a useful noninvasive technique for identifying ongoing arterial hemorrhage. However, only a small portion of the 22 patients actually received a CT examination (CT angiography is not available for emergency). First, metal artifact of implants would interfere the CT image and we usually failed to draw a conclusion. Second, even if abnormal density was detected, it was difficult to differentiate active bleeding with intraoperative blood accumulation. Third, especially in hypotensive state, noninvasive tests usually fail to reveal any abnormality of the major vessels. Angiography provides direct identification of sources of bleeding and could bridge to embolotherapy quickly. Angiographic findings of active contrast agent extravasation, pseudoaneurysm formation, and arteriovenous fistula were observed in most patients with massive bleeding (24). However, according to the above signs, it was not easy to detect occult hemorrhage of small arteries, especially when patient was hypotensive or vasopressor drugs were used (25). Therefore, any sighting of coarse margin or distortion of vessels should be noted and superselective angiography is recommended to avoid misdiagnosis of occult hemorrhage.

Previous results suggested that angiographic finding and time phases was relevant, that earlier postoperative phase tend to exhibit extravasation of contrast agent and later phase pseudoaneurysm or arteriovenous fistula (20). In the present study, the biphasic angiographic finding was not always observable and 7 of 8 hemodynamically unstable patients exhibited contrast agent extravasation during angiography. The angiographic findings may directly reflect the severity of vascular injury. Contrast

Table 1. Demographic data, treatment information, and results

Age/Sex	Diagnosis	Orthopedic surgery	Main symptoms post surgery	Hemodynamic condition	Angiographic findings	Criminal artery	Material	Technical success	Clinical success
60/F	Coxarthrosis	Total hip prosthesis	BP↓, HR↑	Unstable	Pseudoaneurysm	Superior gluteal	Gelfoam and PVA	Success	Recovery
21/M	Femoral carcinoma	Complete thigh amputation	BP↓, HR↑	Unstable	Contrast agent extravasation	Inferior gluteal, obturator	Gelfoam and PVA	Success	Recovery
28/M	Acetabular fracture	Acetabular reconstruction	BP↓, HR↑	Unstable	Contrast agent extravasation	Superior gluteal	Coils	Success	Recovery
20/F	Acetabular fracture	Acetabular reconstruction	BP↓, HR↑, HGB↓	Unstable	Contrast agent extravasation	Deep circumflex iliac	Gelfoam	Success	Recovery
36/F	Pelvic fracture	Internal fixation	BP↓, HR↑	Unstable	Contrast agent extravasation	Internal iliac	Coils	Success	Died of shock
38/M	Acetabular fracture/sinuses	Debridement	BP↓	Unstable	Contrast agent extravasation	Deep femoral	Coils	Success	Recovery
54/M	Hip villonodular synovitis	Total hip prosthesis	Pain, hematoma	Stable	Pseudoaneurysm	Inferior gluteal, obturator	Coils and gelfoam	Success	Recovery
19/F	Acetabular carcinoma	Tumor resection/Total hip prosthesis	Pain, hematoma	Stable	Pseudoaneurysm	Inferior gluteal, superior gluteal	Coils	Success	Recovery
44/M	Sacrum carcinoma	Tumor resection	HGB↓	Stable	Other abnormal vascularities	Inferior gluteal, obturator	Coils and gelfoam	Success	Recovery
50/M	Pelvic fracture	Internal fixation	Hematoma	Stable	Pseudoaneurysm	Internal iliac	Gelfoam and PVA	Success	Recovery
20/F	Acetabular fracture	Acetabular reconstruction	HGB↓	Stable	Contrast agent extravasation	Deep circumflex iliac, deep femoral	PVA	Success	Recovery
72/F	Femoral neck fracture	Hip prosthesis	Pain, hematoma	Stable	Other abnormal vascularities	Superior gluteal	PVA	Success	Recovery
74/F	Femur head necrosis	Total hip prosthesis	Pain, hematoma	Stable	Contrast agent extravasation	Lateral circumflex femoral	Gelfoam	Success	Recovery
44/M	Acetabular fracture	Acetabular reconstruction	BP↓, HR↑	Unstable	Contrast agent extravasation	Superior gluteal	Coils followed by gelfoam	Success	Recovery
63/F	Iliac carcinoma	Tumor resection	BP↓, HR↑, HGB↓	Unstable	Pseudoaneurysm	Internal iliac	Coils followed by gelfoam	Success	Recovery
45/M	Acetabular fracture	Acetabular reconstruction	BP↓, HR↑, HGB↓	Unstable	Contrast agent extravasation	Superior gluteal	Gelfoam	Success	Recovery
59/M	Pelvic fracture	Internal fixation	Hematoma	Stable	Other abnormal vascularities	Internal iliac	Coils followed by gelfoam	Success	Recovery
34/M	Pelvic fracture	Internal fixation	Pain, hematoma	Stable	Contrast agent extravasation	Inferior gluteal	Coils followed by PVA	Success	Recovery
23/M	Pelvic fracture	Internal fixation	HGB↓	Stable	Contrast agent extravasation	Internal iliac	Coils followed by gelfoam	Success	Recovery
43/M	Pelvic fracture	Internal fixation	BP↓, HR↑, HGB↓	Unstable	Contrast agent extravasation	Inferior gluteal	Coils followed by PVA	Success	Recovery
55/F	Acetabular fracture	Acetabular reconstruction	BP↓, HR↑, HGB↓	Unstable	Other abnormal vascularities	Internal iliac	Coils followed by gelfoam	Success	Recovery
76/M	Femoral neck fracture	Hip prosthesis	BP↓, HR↑, HGB↓	Unstable	Other abnormal vascularities	Femoral	Coils followed by gelfoam	Success	Recovery

F, female; M, male; BP, blood pressure; HR, heart rate; HGB, hemoglobin; PVA, polyvinyl alcohol.

Table 2. Findings of the literature review

Author (year)	Country	Patients, n	Mean age, yrs	Treatment	Technical success % (n/N)	Clinical success % (n/N)	Procedure-related complications
Kickuth (2006)	Switzerland	11	62	TAE	100% (11/11)	90.9% (10/11)	Pulmonary embolism (n=1)
Mavrogenis (2011)	Italy	25	48	TAE	100% (25/25)	100% (25/25)	None
Carrafiello (2012)	Italy	9	75	TAE	100% (9/9)	100% (9/9)	None
Cheng (2013)	Korea	12	68	TAE	91.7% (11/12)	66.7% (8/12)	None
Erschbamer (2015)	Switzerland	13	67	TAE	100% (13/13)	84.6% (11/13)	None
The present study	China	22	44	TAE	100% (22/22)	95.5% (21/22)	None
Total		92	57	TAE	98.9% (91/92)	91.3% (84/92)	Pulmonary embolism (n=1)

TAE, transcatheter arterial embolization.

agent extravasation exhibited a continuous process during patients with severe arterial injury or impaired local hemostatic function. In contrast, sighting of coarse margin or distortion usually meant moderate bleeding.

Techniques and materials used during embolization are critical factors determining the treatment prognosis. Although direct identification of bleeding source could be detected by angiography, the selection of vessels for embolization was not always easy to determine. For hemodynamic instability condition or multiple branches hemorrhage, we usually recommend blocking of proximal larger diameter arteries. For exact hemorrhage of certain small culprit vessel, embolization of target vessel is the reasonable choice, avoiding large areas of ischemia. Another situation often encountered in practice is embolization of proximal larger diameter artery followed by embolization of downstream branch vessels with the purpose of complete hemostasis. Type of vascular lesion, size of the feeding artery, and preferences of operator are determinants in the choice of embolic materials. Generally speaking, for temporary embolization of distal, small culprit vessels, gelatin sponge or polyvinyl alcohol may be selected; for trunk arteries with large blood flow, coils followed by gelatin sponge or polyvinyl alcohol are the preferred embolics.

Time-effect is a critical factor that directly affects the outcome of TAE. Early use of TAE for definite hemostasis in the early therapeutic window usually results in good prognosis, especially for patients with hemodynamic instability (26). Although the embolization was technically successful, a

36-year-old woman in our case series died. The patient received internal fixation operation because of traumatic pelvic fracture and quickly progressed to hemodynamic instability. Considering high blood loss in previous operation, the doctor-in-charge preferred transfusion therapy and observation as the first choice. However, several hours later, the patient underwent hemorrhagic shock with loss of consciousness and was transported to the ICU. Considering the possibility of persistent vessel bleeding and intolerance to surgery, orthopedic surgeon sought consultation and angioembolization was finally performed 2 days later. The irreversible pathophysiological changes due to 2 days of latency might be responsible for this patient's eventual death. A quick in-hospital algorithm and a 24-hour interventional team should be recommended to shorten the time for hemostasis in critical patients. Additionally, considering the high accuracy and low invasiveness of angiography, this examination should be carried out more actively for suspected bleeding.

TAE is a safe treatment technique with rare occurrence of severe complications, but a few related defects should not be ignored (9, 15, 17). Potential complications after TAE include early or delayed recurrence of hematoma or bleeding, functional organ deficits, coil migration and backwash, inherent symptoms like pain and infection, non-target embolization, and skin or periarticular tissue necrosis (27–29). In our patients, no severe procedure-related complications were recorded, indicating that the blocking effect of TAE on local blood vessels can be

well compensated by delayed collateral branch, and individualized embolic agent selection and experienced operators can help avoid complications.

There are several limitations in our study. First, our study was small-sized and lacked a control group, which can be attributed to the rarity of these iatrogenic arterial complications. Second, due to the lack of long-term follow-up, we have not been able to further evaluate the durability of the technology. Third, because it is difficult to carry out prospective randomized trials for life-threatening situations, we could only perform a retrospective study. In future, we will further complete a multicenter case collection and include patients who underwent surgical therapy as controls.

In conclusion, TAE is a safe, feasible, and lifesaving strategy for postoperative arterial complications after pelvic or hip surgery, and should be considered as the first option because of minimal invasiveness and lack of complications.

Conflict of interest disclosure

The authors declared no conflicts of interest.

Financial disclosure

The study was supported by the National Natural Science Foundation of China (81471767 and 81871464).

References

- Rossi G, Mavrogenis A, Angelini A, Rimondi E, Battaglia M, Ruggieri P. Vascular complications in orthopaedic surgery. *J Long Term Eff Med Implants* 2011; 21:127–137. [CrossRef]
- Pereira BM. Non-operative management of hepatic trauma and the interventional radiology: an update review. *Indian J Surg* 2013; 75:339–345. [CrossRef]

3. Jiang WX, Zhou ZE, Yan WG, Pan J, Ji ZG. Unexpected hemorrhage of a rare vessel, a pubic branch of the external iliac artery, after laparoscopic radical prostatectomy: Case report. *Medicine (Baltimore)* 2017; 96:e9357. [\[CrossRef\]](#)
4. Puig J, Perendreu J, Fortuno JR, Branera J, Falco J. Transarterial embolization of an inferior genicular artery pseudoaneurysm with arteriovenous fistula after arthroscopy. *Korean J Radiol* 2007; 8:173–175. [\[CrossRef\]](#)
5. Chun HJ, Osuga K, Sugihara E, Tsukaguchi I, Ohsawa S, Tsuda K. Transarterial embolization of large complex arteriovenous fistula associated with hip joint surgery. *Jpn J Radiol* 2010; 28:489–492. [\[CrossRef\]](#)
6. Lum DJ, Poon PC. Embolization as a treatment for bleeding post-total hip arthroplasty. *Aust N Z J Surg* 2000; 70:469–470. [\[CrossRef\]](#)
7. Katsimihias M, Robinson D, Thornton M, Langkamer VG. Therapeutic embolization of the genicular arteries for recurrent hemarthrosis after total knee arthroplasty. *J Arthroplasty* 2001; 16:935–937. [\[CrossRef\]](#)
8. Plagnol P, Diard N, Bruneteau P, Roncheau V. Case report: pseudoaneurysm of popliteal artery complicating a total knee replacement: a successful percutaneous endovascular treatment. *Eur J Vasc Endovasc Surg* 2001; 21:81–83. [\[CrossRef\]](#)
9. Ulmar B, Aschoff AJ, Orend KH, Puhl W, Huch K. Minimally invasive intervention for acute bleeding from a pseudoaneurysm after revision hip arthroplasty. *Acta Orthop Belg* 2004; 70:361–364.
10. Mavrogenis AF, Rossi G, Rimondi E, Ruggieri P, Mercuri M. Embolisation for vascular injuries complicating elective orthopaedic surgery. *Eur J Vasc Endovasc Surg* 2011; 42:676–683. [\[CrossRef\]](#)
11. Lustenberger T, Wutzler S, Stormann P, Laurer H, Marzi I. The role of angio-embolization in the acute treatment concept of severe pelvic ring injuries. *Injury* 2015; 46 Suppl 4:S33–38. [\[CrossRef\]](#)
12. Thomas CD, Asumu T, Chalmers N, Hirst P. Therapeutic embolization for sustained hemorrhage following total hip replacement in a patient with hemophilia A. *Orthopedics* 2000; 23:849–850.
13. Carlin RE, Papenhausen M, Farber MA, et al. Sural artery pseudoaneurysms after knee arthroscopy: treatment with transcatheter embolization. *J Vasc Surg* 2001; 33:170–173. [\[CrossRef\]](#)
14. Barriga A, Valenti Nin JR, Delgado C, Bilbao JJ. Therapeutic embolisation for postoperative haemorrhage after total arthroplasty of the hip and knee. *J Bone Joint Surg Br* 2001; 83:90–92. [\[CrossRef\]](#)
15. Velmahos GC, Toutouzias KG, Vassiliu P, et al. A prospective study on the safety and efficacy of angiographic embolization for pelvic and visceral injuries. *J Trauma* 2002; 53:303–308. [\[CrossRef\]](#)
16. Schneider JR, Alonzo MJ, Hahn D. Successful endovascular management of an acute iliac venous injury during lumbar discectomy and anterior spinal fusion. *J Vasc Surg* 2006; 44:1353–1356. [\[CrossRef\]](#)
17. Kickuth R, Anderson S, Kocovic L, Ludwig K, Siebenrock K, Triller J. Endovascular treatment of arterial injury as an uncommon complication after orthopedic surgery. *J Vasc Interv Radiol* 2006; 17:791–799. [\[CrossRef\]](#)
18. Carrafiello G, Fontana F, Mangini M, et al. Endovascular treatment in emergency setting of acute arterial injuries after orthopedic surgery. *Cardiovasc Intervent Radiol* 2012; 35:537–543. [\[CrossRef\]](#)
19. Cheng H, Shin JH, Yoon HK, et al. Retrospective 12-year study of the safety and efficacy of transcatheter arterial embolization for managing bleeding complications following hip surgery. *Cardiovasc Intervent Radiol* 2014; 37:1464–1468. [\[CrossRef\]](#)
20. Erschbamer M, Den Hollander J, Sauter D, Erhardt J, Hechelhammer L, Kulling F. Endovascular embolisation is a successful and safe treatment for post-operative arterial complications after total hip arthroplasty and revision surgery. *Int Orthop* 2016; 40:1577–1582. [\[CrossRef\]](#)
21. Wilson JS, Miranda A, Johnson BL, Shames ML, Back MR, Bandyk DF. Vascular injuries associated with elective orthopedic procedures. *Ann Vasc Surg* 2003; 17:641–644. [\[CrossRef\]](#)
22. Calligaro KD, Dougherty MJ, Ryan S, Booth RE. Acute arterial complications associated with total hip and knee arthroplasty. *J Vasc Surg* 2003; 38:1170–1177. [\[CrossRef\]](#)
23. Marzi I, Lustenberger T. Management of Bleeding Pelvic Fractures. *Scand J Surg* 2014; 103:104–111. [\[CrossRef\]](#)
24. Alserr AH, Antonopoulos CN, Papapetrou A, Kakisis JD, Brountzos E, Liapis CD. Endovascular repair of popliteal artery pseudoaneurysm with arteriovenous fistula after knee arthroscopy: case report and literature review. *Vasc Endovascular Surg* 2014; 48:166–170. [\[CrossRef\]](#)
25. Po LK, Simons ME, Levinsky ES. Concealed postpartum hemorrhage treated with transcatheter arterial embolization. *Obstet Gynecol* 2012; 120:461–464. [\[CrossRef\]](#)
26. Papakostidis C, Kanakaris N, Dimitriou R, Giannoudis PV. The role of arterial embolization in controlling pelvic fracture haemorrhage: a systematic review of the literature. *Eur J Radiol* 2012; 81:897–904. [\[CrossRef\]](#)
27. Soyer P, Dohan A, Dautry R, et al. Transcatheter Arterial Embolization for Postpartum Hemorrhage: Indications, Technique, Results, and Complications. *Cardiovasc Intervent Radiol* 2015; 38:1068–1081. [\[CrossRef\]](#)
28. Bauer JR, Ray CE. Transcatheter arterial embolization in the trauma patient: a review. *Semin Intervent Radiol* 2004; 21:11–22. [\[CrossRef\]](#)
29. Vo NJ, Althoen M, Hippe DS, Prabhu SJ, Valji K, Padia SA. Pediatric abdominal and pelvic trauma: safety and efficacy of arterial embolization. *J Vasc Interv Radiol* 2014; 25:215–220. [\[CrossRef\]](#)